

Krzysztof ŚWIEŻYŃSKI

The Skeletal Muscular System of the European Bison,  
*Bison bonasus* (L i n n a e u s 1758) <sup>1</sup>

Umięśnienie szkieletowe żubra, *Bison bonasus* (L i n n a e u s 1758)

**Bisoniana VIII.**

[With 30 Figs. and 1 table]

I. Introduction . . . . .	166
II. Material and method . . . . .	167
III. Detailed section . . . . .	168
1. Head . . . . .	168
A. Muscles of the lips and cheeks . . . . .	168
B. Mandibular muscles . . . . .	171
2. Neck and trunk . . . . .	173
A. Muscles of the shoulder girdle . . . . .	173
B. Epaxial muscles . . . . .	178
C. Group of the short muscles of the vertebral column . . . . .	184
D. The lateral and ventral muscles of the vertebral column . . . . .	185
E. The muscles of the thoracic wall . . . . .	187
F. The abdominal muscles . . . . .	189
3. The thoracic limb . . . . .	191
A. Muscles of the shoulder and arm . . . . .	191
B. Muscles of the forearm and manus . . . . .	195
a. Extensor division . . . . .	195
b. Flexor division . . . . .	196
4. The pelvic limb . . . . .	200
A. Inner and ventral muscles of the rump . . . . .	200
B. The lateral muscles of the hip . . . . .	201
C. The medial muscles of the thigh . . . . .	203
D. The anterior muscles of the thigh . . . . .	205
E. The posterior muscles of the thigh . . . . .	205

<sup>1</sup>) The work was carried out partly with the financial assistance of the Zoological Committee of the Polish Academy of Sciences.

F. The muscles of the leg and foot . . . . .	207
a. Dorso-lateral group . . . . .	207
b. Plantar group . . . . .	209
c. Muscles of metatarsus . . . . .	211
IV. Discussion and results . . . . .	211
References . . . . .	215
Streszczenie . . . . .	217

## I. INTRODUCTION

Publications on the European bison are concerned chiefly with the problems of its biology, occurrence, breeding in reserves, while more recent works deal also with its physiology and within very narrow limits, with the pathology of this species.

Literature on the anatomy of the European bison is not abundant. The list given by Wilkus (1957) of publications dealing with this subject has been supplemented in recent years by the publications of the Warsaw Centre: Świeżyński & Pilarski (1956), Pilarski & Roskosz (1957), Piękoś & Pilarski & Roskosz (1958), Krysiak (1960), Roskosz & Empel (1961), Węgrzyn & Serwatką (1961) and the work by Bochenek (1955). Among the foreign authors, known to me in addition to the names given by Wilkus (l.c.) the following dealt with the anatomy of the European bison — Poleiner (1932), Millot (1945) and as a side line only Albrecht (1944).

The majority of works are concerned with the skeleton of the European bison. The reason for this state of affairs was probably to be found in the difficulties involved in the collection of material. The small number of living European bison, and in connection with this the infrequent opportunities of obtaining cadavers made it necessary to wait for a long time for the completion of a suitable number of specimens for research. Bones as being easier to store, were more suitable for this purpose.

Works on the "soft parts" of the body are in the majority of cases merely contributions. This is the result, in addition to the difficulties mentioned above in obtaining material, of difficulties in storing and conserving the remains of so large an animal.

One of the few works known to me amongst those dealing with the skeletal muscular system of the E. bison is that by Poleiner (1932). The author had at his disposal the limbs of a female European bison which had died in a Zoo. His observations are concerned with the skeleton, muscles and main nerve and vascular trunks of the thoracic and pelvic limbs of the E. bison in comparison with domestic cattle. Świeżyński & Pilarski (1956) dealt with the cutaneous muscular system of the European bison. Wróblewski (1927) refers to the muscular system of the E. bison in more general terms.

Research on the skeletal muscle system of the E. bison involved the start of work practically from its basic elements. Poleiner's observations made on one specimen only, and in addition referring only to the limbs of the European bison, were checked and supplemented during investigations covered by the present work. Investigation was also made of the morphology of muscular components of the remaining regions of the body of the European bison. The work does not include the group of hyoid muscles, the muscles of the ear, nose, external muscles of the eyeball and of the tail. These groups will be investigated (or are in process of investigation) together with the respective systems.

## II. MATERIAL AND METHOD

The material used for investigations consisted of the cadavers of twenty European bison which had died during the period from 1950 to 1960. The detailed list below shows that these were bison of both sexes and of different ages. The number of males and females, and the different ages of the specimens of both sexes, made it possible to state authoritatively that this material may form a basis for reaching objective conclusions, taking into consideration both factors.

**Table 1.**  
Material.

No.	No. of Pe-degree Books	Name	Age			No.	No. of Pe-degree Books	Name	Age		
			Years	Months	Days				Years	Months	Days
Females						Males					
1.	1153	Poługa	—	—	1	9.		Foetus			
2.	866	Poda.	—	—	2	10.	794	Pogrom	—	—	19
3.	900	Plazma	—	7	1	11.	84/R	Porucznik	—	5	8
4.	893	Platyna	—	7	13	12.	863	Plastuś	—	8	18
5.	943	Purata	1	5	10	13.	1086	Pud (Burnus)	1	—	26
6.	858	Tatra	1	6	26	14.	824	Plater	7	2	17
7.	674	Poziomka	11	8	16	15.	572	Połamaniec	9	1	26
8.	219	Planarie	18	5	2	16.	785	Pluszcz	10	5	9
						17.	597	Punkt	10	6	23
						18.	546	Pluvius II	17	3	6
						19.	228	Puk	17	4	6
						20.	575	Plato	17	4	4

The majority of the European bison which we prepared were first subjected to anatomopathological autopsy to discover the cause of death. This caused partial damage to certain regions of the muscular system (the wall of the abdomen, the wall of the thorax, the ventral muscles of the neck). For this reason only parts of certain of the cadavers were used for our investigations. The same applied when difficulties arose in connection with the transport of the whole cadaver, when the animal died a long way from Warsaw, when the specimen was a large one, and when death took place during the summer when the processes of dissolution rapidly ensue.

Anatomical preparation was carried out partly on fresh and partly on fixed material. The fresh material was used when field work was done, for as long as the state of the cadavers permitted. This applied especially to the first period of investigations. As the technique for preserving the carcasses was improved, difficulties were eliminated.

Material was fixed by keeping it in basins containing a water solution of formalin (about 8%), or by interarterial injections. A 5% formalin solution was used for injection, or a mixture of the methylated ethyl alcohol usually obtainable in shops,

phenol, formalin, potato syrup and water in the following parts: 60 : 6 : 4 : 5 : 25<sup>2)</sup>). The mixture used permitted of maintaining the cadaver in a satisfactory condition for several months even at the warm time of the year. In addition the muscles (like other organs) did not harden as they do when formalin only is used, which makes preparation difficult. The specimens which were kept in a formalin solution were placed for 5—6 days in a 3% water solution of spirits of salts to soften them before preparation.

The drawings included in this work were made from photograms.

### III. DETAILED SECTION

#### 1. HEAD

##### A. Muscles of the lips and cheeks

1. *M. m. cutanei* — of the head are represented in European bison by *m. cutaneus faciei*, *m. cutaneus frontalis*, *m. cutaneus nasi* and *m. cutaneus labiorum*. The behaviour of these muscles is similar to that of the corresponding muscles in domestic cattle, except as regards size, which is greater in the European bison (P i l a r s k i & Ś w i e ż y ń s k i (1956).

2. *M. orbicularis oris* — does not differ in appearance from that in cattle. Its fibres run circularly along the lower lip and pass on both sides into the upper lip.

3. *M. incisivus maxillaris* — is formed by scattered muscular fascicles passing from os incisivum and radiating into the upper lip.

4. *M. incisivus mandibularis*. Is slightly more strongly developed than *maxillaris*. The muscular fascicles of this muscle run from the anterior surface of the alveolar border for the incisor teeth of the mandible and reach to the lower lip.

5. *M. levator naso-labialis* (Fig. 29, 30 — N1.), begins in *fascia nasofrontalis* at the level of the eye sockets and on the dorsal surface of the nasal bone. In this region it is covered by fascicles of fibres of *m. cutaneus frontalis*. The fibres of the flat venter run in an antero-ventral direction and the venter divides above the upper edge of *m. levator labii maxillaris proprius* into the superficial and the deep layers. Fibres running along the surface cover *m. levator labii maxillaris proprius*, *m. caninus* and *m. depressor labii mandibularis*, next radiating into *m. orbicularis oris*. The deep layer lies under the group of the above mentioned muscles, ending in *margo adentalis* of the maxilla and premaxilla.

The description given above agrees with that accepted in textbooks.

<sup>2)</sup> The fluid was prepared according to the prescription used in the Department of Veterinary Anatomy of Iowa State University, where prophylactic alcohol, phenol, corn syrup and water are used. The composition of the fluid we used was adapted to the possibilities of obtaining the ingredients in Poland.

The problem of the structure of the muscle referred to and the appurtenance of its parts to corresponding muscle units has for a long time formed a subject for discussion.

As long ago as 1883 F r a n c k questioned the appurtenance of the deep layer of *m. levator naso-labialis* to this muscular unit.

A k a j e w s k i (1931) when investigating these muscles in cattle, sheep, reindeer, pigs and dogs included the deep layer with *m. lateralis nasi*, at the same time identifying the anterior part of *m. malaris* as *pars malaris musculi levatoris naso-labialis*. He based his statement on the results of his own investigations and the works by H u b e r (1924), introducing some supplementary material, which in his opinion was essential to a discussion of this problem in animals in general, and in ruminants and pigs in particular.

K a m a n & H a m p l (1959) in their work on the superficial facial muscles in *Capreolus capreolus* (L i n n a e u s 1758) on the basis of the origin and innervation of the muscle in question, distinguished three muscular units: *m. naso-labialis superficialis*, *m. naso-labialis lateralis profundus* et *m. naso-labialis dorsali profundus*.

The observations we made, described above, on the structure and situation of *m. levator naso-labialis* are insufficient to solve the problem of the appurtenance of its different parts to this or the other muscular unit of the European bison.

6. *M. levator labii maxillaris proprius* (Fig. 1, 29 — Ll.) is attached to the maxilla, orally of *tuber malare*. The fairly thick venter of this muscle, the fibres of which run dorsally, passes into a number of distinct fascicles, and later tendons radiating into the upper lip. Part of them are connected with similar tendons on the opposite side.

7. *M. caninus* (Fig. 1, 29 — C.) runs together with *m. levator labii maxillaris proprius* and *m. depressor labii maxillaris*. Near the insertion it is strongly connected with the latter. The rounded venter of this muscle, the fibres of which run lengthways, passes into the tendon, ending in the nasal muscles.

8. *M. depressor labii maxillaris* (Fig. 1, 29 — Dl.) is connected by its venter with *m. levator labii maxillaris proprius* and with *m. caninus*. It originates, together with the latter, and in the oral section separates from it distinctly. It ends in two or three thin tendons situated ventral to the tendons of the previous one, in the muscles of nose and in the upper lip.

9. *M. zygomaticus* (Fig. 30 — Z.) lies very superficially and begins in the *fascia parotidico-masseterica*, on the external surface of the *masseter*. It forms a flat venter, to which the fibres of the *m. cutaneus faciei* radiate. In its continuation the venter of *m. zygomaticus* runs to the corner of the

mouth, and in so doing covers *m. buccinatorius* and ends in *m. orbicularis oris*. Near its termination *m. cutaneus labiorum* reaches *m. zygomaticus*, and in this place all three (*m. cutaneus labiorum*, *m. zygomaticus*, *m. buccinatorius*) intertwine their fibres.

10. *M. depressor labii mandibularis* (Fig. 1, 29 — Dm.) lies along the lower edge of *m. buccinatorius* and comes into close contact with its superficial layer. The fibres, which at first run forward and downward and later on lengthways, form a flat venter and radiate into the lower lip. The fibres of *m. sterno-mandibularis* which run from the side of *angulus mandibulae*, lie on this muscle.

11. *M. buccinatorius* (Fig. 1, 29 — B, B', B'') forms the stroma to the cheek and exhibits a multi-strata structure.

The most superficial, thin layer, the fibres of which run perpendicularly and intertwine with the fibres of *m. depressor labii mandibularis*, covers numerous salivary glands and ends at the level of the anterior edge of *m. masseter*.

The intermediate layer has fibres running diagonally to the long axis of the head and is thickest in the aboral part of the muscle, being inserted between the alveolar border of the maxilla and the aboral part of the alveolar border of the mandible. The majority of the fibres in this layer run to the *lemniscus inferior*<sup>3)</sup> and radiate into *m. orbicularis oris*.

The deepest and thinnest layer, only slightly separated from the former one, has fibres running in several directions, with a preponderance of lengthwise ones. They radiate both into *lemniscus superior*<sup>3)</sup> and *inferior*. This layer is thickest in the aboral part of the muscle. From the interior it is covered by a mucous membrane with which it is closely bound.

The description given above of *m. buccinatorius* in the European bison is similar to the relations obtaining in this respect in domestic cattle. Chomiak (1947) made exhaustive studies of this muscle in domestic ruminants and Wilkus (1957) referred in passing to this problem, using the European bison as an example. From these works it is clear, *inter alia*, that *m. buccinatorius* is characterised by a close morphological and functional connection with the long protuberances found in ruminants, situated on the mucous membrane of the cheek. The results given by the above two authors are confirmed by our observations.

12. *M. mentalis* — partly covers *m. incisivus ventralis*, running from the anterior surface of the alveolar border for the incisor teeth of the mandible. It is fairly thick, strongly interlaced with abundant connective tissue. It radiates into the lower lip.

<sup>3)</sup> Terms introduced by M. Chomiak (1947).

13. *M. orbicularis oculi* is strongly developed. The fascicles of the fibres of this muscle, attached to the bony border of the orbit, follow a circular course. The whole of the muscle is interlaced by abundant connective tissue.

14. *M. malaris* (Fig. 29, 30 — Ma.) is relatively strongly expressed in the European bison and both the anterior and posterior parts can be distinguished, being clearly defined, but coalescing with each other. The anterior part beginning on *facies facialis* of the lacrimal and zygomatic bones, forms a flat venter with radiating fibres which terminate at the level of *m. zygomaticus*, penetrating into *m. buccalis*. The superior insertion of the posterior part reaches further to the back under the lower eyelid. Numerous fibres of this part run downwards, partially covering *m. buccinatorius*, where they disappear fairly low down at the level of the clearly visible buccal branches of the facial nerve.

The anterior part is included by A k a j e w s k i (1931) with *m. levator naso-labialis* (see description of this muscle).

The posterior part, also termed *m. depressor palpebrae inferioris*, is more strongly formed in the European bison than in cattle.

Similar relations were noted in the goat (K o l d a, 1950).

#### B. Mandibular muscles

1. *M. masseter* (Fig. 1 — M.M') of the European bison has two easily distinguishable main parts, of which one is situated superficially and anterior in relation to the second, which has a posterior position and is partly covered by the former.

The superficial part begins at *os maxillaris*, its superior insertion reaching backwards from facial tuberosity, through the zygomatic bone and *facies masseterica* of *arcus zygomaticus* to the end of *processus temporalis ossis zygomatici*. The flat venter of the muscle is of fairly characteristic shape and has clearly defined boundaries, is constructed of fascicles of fibres running obliquely, being decidedly perpendicular near the posterior border. This layer ends in *fossa masseterica* of the mandible (faintly defined in the European bison) on the border of *angulus mandibulae*, and partly on the *ramus mandibulae*. The deepest fibres of this part "tear away" during preparation and reveal a separate insertion, beginning on *tuber maxillae*, and ending on the craniolateral surface of *ramus mandibulae*. The course followed by the fibres is the same in it as in the remainder and it is in fact difficult to speak of a separate layer.

The deep part begins on the zygomatic process of the temporal bone and ends on the external surface of *ramus mandibulae* below the condyle of the mandible.

The structure and course of the fibres of the masseter in *E. bison*, described above, correspond to the description given by Borowiec (1950) of the same relations in cattle. The only difference is that we did not note the fusion of the deep layer of the masseter with *m. temporalis*, mentioned by Borowiec (l.c.)

2. *M. pterygoideus medialis* (Fig. 2, 4 — Ptm, Ptm') the strong levator of mandible, begins on the perpendicular part of the palatine bone and on the pterygoid process of the sphenoid bone. Just after leaving this insertion it is divided by *m. pterygoideus lateralis* running in this direction to its insertion on the cranium, into two flat bellies, or in fact into two layers.

The anterior superficial layer begins as described above, its fibres running in an backward and downward direction, being inserted in fanlike formation on to the medial surface of the angle of the mandible.

The posterior deep layer begins at the back of the above layer on the pterygoid process of the sphenoid bone and in the pterygo-palatine fossa, ending on the medial surface of the ramus of mandible.

3. *M. pterygoideus lateralis* (Fig. 4 — Ptl.), forms a strong venter, the fibres of which run in a posterior convergent direction. It begins on the border of the pterygo-palatine fossa and partly in the temporal fossa, and ends on the medial side of the condyle of the mandible.

The pterygoid muscles of the *E. bison* do not in principle differ from the corresponding ones in domestic cattle. Only *m. pterygoideus lateralis* does not exhibit the bistratiform structure, described by Borowiec (1950), despite the fact that the places of insertion agree with those described by this author in domestic cattle.

4. *M. temporalis* (Fig. 3, 4 — T, T') fills the temporal fossa and is attached to its border. The main mass of muscle is similar in shape to an elongated oval, with fibres running to the centre, in the direction of the coronoid process of the mandible, into which they are attached. The muscular venter, the fibres of which run in an antero-ventral direction, separates from the antero-dorsal surface of the part of the muscle described above. This venter is attached to the walls of the temporal fossa, partly on *crista pterygoidea*, and then run downwards and surround the base of the coronoid process from the front and sides. The muscular fascicles of this part reach downwards almost to the level of the *arcus dentalis inferior* and are inserted on the medial and lateral surfaces of the ramus of the mandible near its anterior border.

The presence of the separated anterior portion of *m. temporalis* described above was confirmed by Borowiec (1950) in domestic cattle. In the *E. bison* it extends downwards, and the mandibular insertion covers



not only the medial surface of the *ramus mandibularis*, as in the case of cattle, but also the lateral surface.

5. *M. biventer mandibulae* (Fig. 2 — Bv.—Bv'.) originates on the paramastoid process of the occipital bone with a distinct initial tendon attached under the inferior border of the occipito-mandibular muscle. The thin fusiform venter posterior of this muscle runs in the direction of the angle of mandible, where it passes through the medial part into a short tendon situated in a postero-medial position in relation to the thickened posterior border of *m. masseter*. The flattened venter anterior runs from this tendon which ends on the ventral border of the body of the mandible. Along the medial border of the anterior belly of the biventer, there is a tendinous strip which is an extension of the tendon between the anterior and posterior bellies. *M. interdigastricus* runs between the tendinous strips of the bilateral anterior bellies. This muscle is better formed in older individuals (fig. 2 — d.). The muscle described covers from the bottom the posterior deep part of *m. mylohyoideus* lying under it.

The division of *m. biventer* into anterior and posterior bellies noted both in domestic cattle (Bijvoet, 1908; Martin & Schauder, 1938) and in small domestic (Thiel, 1954) and wild ruminants (Thiel, l.c.; Hampl & Kaman, 1959) is also clearly defined in the E. bison. The shape and situation of both bellies correspond to relations in cattle, the insertion of the anterior belly on the mandible reaching further to the front, similarly to the relations in the goat (Thiel, l.c.).

## 2. NECK AND TRUNK

### A. Muscles of the shoulder girdle

1. *M. trapezius* (Fig. 29 — Tu, Th.), forms the most superficial layer of muscles of the withers. As in other animals, the *pars cervicalis* and *pars thoracalis*, which are not sharply divided from each other, can be distinguished in it.

*Trapezius cervicalis*, attached to the dorsal border of the funicular part of the nuchal ligament, extends over the space between the second and third cervical vertebrae and the first thoracic vertebrae, and ends along the spine of the scapula. At the level of the third-fourth cervical vertebrae this muscle intertwines its muscular fascicles with those of *m. rhomboideus* which lies beneath it. Its anterior border (especially in the upper section) fuses with *m. cleidooccipitalis*.

The superior insertion of *trapezius thoracalis* reaches to the spinous processes of the terminal thoracic vertebrae (Th<sub>10</sub>—Th<sub>13</sub>, or Th<sub>14</sub>). The fibres of the muscle run in an antero-ventral direction to the upper <sup>2</sup>/<sub>3</sub>

of *spina scapulae*. In this region the muscle described coalesces with *m. cutaneus scapulohumeralis*, and the lower border with *m. latissimus dorsi*.

The powerfully developed (especially in males) withers and neck of the bison are to a great extent the result of the strong development of the muscles of this region. Contrary to this principle, *m. trapezius* in E. bison does not exhibit specially strong development. Both the cervical and thoracal portions are formed from relatively thin, flat patches of muscle. The extent of the truncal insertion of the thoracic part is situated more to the back than in cattle (Th<sub>9</sub>—Th<sub>10</sub>) and even more so than in ruminants with strongly developed muscles of the withers such as the Indian water-buffalo, in which it reaches T<sub>9</sub> (de M o u l i n, 1924).

2. *M. omotraversarius* (Fig. 29 — Ot.) is a flat muscle running from the scapular fascia at the level of the *collum scapulae* in the direction of the head. It is covered from the top by *m. trapezius* and in the anterior section by *m. brachiocephalicus*, and ends on the wing of atlas connecting by means of its aponeurosis with *m. splenius* and *m. longissimus atlantis*.

3. *M. rhomboideus* (Fig. 5, 14, 15, 16, 29 — R, R'.) is strongly developed in the E. bison. It attains great dimensions, especially in males, shaping (together with *m. splenius*) the outline of this region characteristic of the bison. It divides into two parts, differing as to situation and direction in which the fibres run.

*Pars thoracalis* is inserted on the lateral surfaces of the spinal processes of the thoracic vertebrae from the 2 — 5. The flat venter of this part has fibres running transversely, upwards and forwards, and ends on the medial surface of the scapular cartilage and the scapula.

*Pars cervicalis* has fibres running in an arch upwards and forwards, and is directed forwards from the anterior part of the scapular cartilage, and as it approaches the termination of the cervical insertion it thickens, the thickening in males being considerably greater than in females. The part described is inserted along the *funiculus nuchalis*, on which at the level of approximately the 2—3 cervical vertebrae it ends suddenly in males and more gradually in females. The cervical parts of the rhomboid muscles of both sides connect along the *funiculus nuchalis*.

The structure of the muscle described in E. bison differs considerably from the relations found in cattle. These differences apply both to the degree of development of the different parts and to the extent of the insertions. The cervical part which in cattle is represented by the relatively flat muscular venter, is strongly thickened in the bison and forms the ridge of the massive "hump". The vertebral insertion of *pars thoracalis* reaches in cattle to Th<sub>7</sub> — Th<sub>8</sub> (M a r t i n & S c h a u d e r, 1938) while

in the E. bison in the 8 specimens prepared by us it reached Th<sub>4</sub> or Th<sub>5</sub>, and in one case Th<sub>6</sub>. The strongly developed spinal processes of the thoracic vertebrae of the E. bison cause the fascicles of muscle of the *pars thoracalis* of the rhomboid muscle to be relatively longer than in cattle, and the whole part to be wide.

The participation of *m. rhomboideus*, and strictly speaking its cervical portion, in the structure of the "hump" in the zebu ox was described by Boas & Peterson (1921) and de Moulín (1924). The behaviour of both parts of the muscle under discussion in the zebu ox differs considerably from what we found in the E. bison, the result of which is the completely different silhouette of this animal. This leads to the "shift" in the zebu ox of the cervical part backwards to the thoracic part, which produces a "hump" situated at the level of 1st to 6th thoracic vertebrae, while in the E. bison the "hump" is situated above the cervical part of the vertebral column. We did not find in the E. bison the division, described in respect of the zebu ox by de Moulín (l.c.) of the *pars cervicalis* of the rhomboid muscle into two separating layers.

4. *M. sternocleidomastoideus* in E. bison, as in cattle, is represented by *m. brachiocephalicus* and *m. sternocephalicus*.

a) *M. brachiocephalicus* (Fig. 29, 30 — Br.) is situated on the lateral surface of the neck. It originates on the humerus in the *crista humerii* region. The flat muscular venter runs forwards, surrounding the anterior part of the deep pectoral muscle and the cranio-lateral lower end of *m. biceps brachii*. Near the shoulder joint it is covered from the side and bottom by *pars clavicularis musculi pectoralis superficialis*. It coalesces closely with the latter, from which it cannot be separated. Midway along the neck the muscular venter is divided by a tendinous inscription, at first faintly defined and later more distinctly visible, into two parts strongly fused with each other. It is only possible to separate them in certain places.

The dorsal part described in cattle and other ruminants as *m. cleidooccipitalis* terminates in a flat aponeurosis on the occipital bone, being also inserted in the funicular part of the nuchal ligament near the *m. rhomboideus*.

The ventral part known as *m. cleidomastoideus*, coalesces at its lower border with *m. sternomastoideus* and thrusting under the parotid, terminates on the mastoid process of the temporal bone. From it a few fibres run to the base of the cranium.

The description given above of *m. brachiocephalicus* in the E. bison in principle corresponds to the description of this muscle in cattle, except that in the literature at our disposal we nowhere found a mention of

a connection between *m. cleidomastoideus* and *m. sternomastoideus*. Such a connection is, on the other hand, the rule with *m. brachiocephalicus* in the goat, in which the cranial insertion is situated only on the base of the cranium (Reiser, 1903).

b) *M. sternocephalicus* in the E. bison, as in other ruminants, is divided into the superficial and deep parts. Both originate on the sternum.

The superficial part (Fig. 5, 7 — St.) corresponding to *m. sternomandibularis* in cattle runs from *manubrium sterni* and is situated in this region dorsally in relation to the deep part. It runs in the direction of the head and crosses the deep part laterally at the level of the upper  $\frac{1}{3}$  of the neck. At the level of *angulus mandibularis* the muscular venter passes into two tendons. One reaches the anterior border of *m. masseter*, closely fusing with it. The second is inserted on the body of the mandible.

The deep part corresponding to *m. sternomastoideus* (Fig. 5, 7 — Sr.) also runs from *manubrium sterni*. It coalesces in this place with *m. sternomandibularis* and is partially covered by it. The long, flat muscular venter crosses *m. sternomandibularis* medially, and laterally *m. omohyoideus*, and at the level of the atlas passes into aponeurosis. It ends on the mastoid process of the temporal bone (jointly with *m. cleidomastoideus*) and partially also on the base of the cranium and the medial surface of the ramus of the mandible.

The structure of and course followed by *m. sternocephalicus* in the E. bison do not in principle differ from the relations found in cattle.

5. *M. sternoclavicularis* — in the European bison is very strongly fused with *m. brachiocephalicus*. It extends from *manubrium sterni* and from the first costal cartilage, passing upwards and sideways, to disappear in *m. brachiocephalicus*. The degree of fusion of the above muscles is very considerable. Among the E. bison which we prepared *m. sternoclavicularis* and *m. brachiocephalicus* were distinctly separated from each other only in the cadaver of one male called "Pluszcz".

6. *M. latissimus dorsi* (Fig. 16, 30 — Ld.) forms a wide muscular layer situated caudally in relation to *m. trapezius*. Partially covered by *m. cutaneus trunci*, it originates in a wide, flat aponeurosis closely fused with the superficial layer of the lumbo-dorsal fascia and with the dorso-transversal fascia. Its aponeurosis passes into a flat muscular venter attached in addition in the form of two teeth on the lower  $\frac{1}{3}$  of ribs X—XI or IX—X depending on the number of ribs occurring.

The venter, in which the fibres run convergently, in a cranio-ventral direction, partially covers the serratus muscles, and thickens as it approaches the posterior border of the scapula. Above the olecranon *latissimus dorsi* thrusts under *caput longum* of the *triceps brachii*. On the

medial side of the limb the venter passes into a strong tendon partially fused with *m. teres major*. It terminates on the deltoid tuberosity of the *humerus*. The lower border of the muscle occasionally intertwines the fascicles of fibres with *m. pectoralis profundus*.

The structure of *m. latissimus dorsi* exhibits relations between domestic cattle and small ruminants. The similarity to these latter is marked in the costal insertion of this muscle, which in sheep and goats covers ribs IX—XI (M ö r i k o, 1954), while in cattle it reaches ribs XI—XII (M ö r i k e, 1954; M a r t i n & S c h a u d e r, 1938). On the other hand, however, these authors have emphasised the occurrence in small ruminants of 3—4 digitations which were attached to the ribs, while in the E. bison, similarly to cattle, we found the presence of two digitations.

K o m a r e k (1958) describes the intertwining of fibres between *m. latissimus dorsi* and *m. pectoralis profundus* in *Cervus elaphus* (L i n n a e u s 1758).

7. *M. m. pectorales* form in the E. bison two principle aggregations in the form of *m. pectoralis superficialis* and *m. pectoralis profundus*.

a) *M. pectoralis superficialis* (Fig. 29, 30 — Ps.) covers the *sternum* from the anterior, dividing into two distinct parts.

The anterior and more superficial part, known under the name of *pars clavicularis*, runs from the lateral surface of *manubrium sterni*. The flat venter, with fibres running in an cranio-lateral direction, covers the lower end of *m. biceps brachii*, terminating on the *humerus* in the region of the radial fossa and in the antebrachial fascia.

The posterior part of this muscle *pars sterno-costalis* originates on *manubrium sterni* (is covered by the anterior part) and on the sides of *sternebrae* and reaches caudally to the level of 5—6 costal cartilages. The flat venter has fibres running in an antero-lateral direction, and it ends in fascia antebrachii, connecting with *m. brachicephalicus*.

b) *M. pectoralis profundus* (Fig. 29, 30 — Pp.) is strongly developed in the E. bison and begins on the *sternum* and costal cartilages (with the exception of the first), up to the abdominal fascia.

The stronger (compared with *m. pectoralis superficialis*) muscular venter, the fibres of which run obliquely craniad, bifurcates at its termination. The anterior part of this attachment inserts on *tuberculum maius* of the *humerus* and cranio-medially covers the lateral branch of *m. supraspinatus*. The posterior part ends under the medial branch of the above muscle.

The prescapular part of the deep pectoral muscles is not present in the E. bison as is the case in other ruminants. We found a few fascicles of muscle fibre running forwards from *tuberculum maius* in the direction of

the cervical border of the scapula in one out of six individuals dissected ("Pluszcz"). It may be considered as corresponding to the prescapular part of the deep pectoral muscle. The presence of such fascicles has also been described in some domestic cattle (M ö r i k e, 1954).

The pectoral muscles behave similarly in the E. bison to those in domestic and certain wild ruminants, such as, for instance, *Cervus elaphus*, *Capreolus capreolus* (R e i s e r, 1903; K o m a r e k, 1958), the gazelle (M ö r i k e, 1954).

8. *M. serratus ventralis* in the E. bison (Fig. 5, 29, 30 — Sv, Sv'.) is strongly developed and originate on the medial surface of the scapular cartilage and the scapula.

*Serratus thoracis* falls into regular digitations, spreading out fanwise to the respective ribs. The first three digitations are attached to the upper  $\frac{1}{2}$  of the ribs I, II, III. Starting from rib IV caudad, the digitations are longer and reach to the costo-chondral junctions. The final digitation is attached to rib IX. In the majority of the individuals dissected there was a further small digitation attached above the final digitation on rib IX, which in three specimens ("Tatra", "Plastus", and foetus) reached to rib X.

*Serratus cervicis* ends in digitations on the transverse processes from the 3rd to 7th cervical vertebrae.

The division and extent of the attachments of *m. serratus ventralis* in the E. bison correspond to the relations found in cattle.

## B. Epaxial muscles

1. *M. splenius* (Fig. 5, 6, 29 — Sl.) originates on the spinous processes, from the 2nd to 5th thoracic vertebrae and in *fascia spinotransversaria*. The muscular fibres run obliquely forwards and downwards, thickening considerably at the level of the 1st thoracic vertebra. In the cervical part the muscle becomes even thicker, this thickening being specially strong in adult males, in which the division of the muscle into three fleshy digitations can be seen. In females and young specimens the division of the belly of the muscle is less distinct, only three tendinous layers being visible. The most caudal of these connects with the digitation of *m. serratus ventralis*, and terminates on the 3rd cervical vertebra. The second in order of the bands runs to the wing of atlas in common with the tendons of *longissimus atlantis* and *longus atlantis* muscles. The most cranial band, in the form of a flat aponeurosis, is located together with the insertion of the *m. longissimus capitis* on the occipital bone. This aponeurosis is in common with the *pars occipitalis musculi longissimi capitis*, with *pars cleidooccipitalis musculi brachiocephalici* and with *m. splenius*.

The attachment of the above muscle to the spinous processes of the thoracic vertebrae reaches further than in the case of cattle, in which it covers the spinous processes of Th<sub>3</sub> and Th<sub>4</sub> vertebrae. This attachment in addition projects further cranial than that in cattle. Attachment of *m. splenius* on the spinous processes of the first thoracic vertebrae occurs also in such *Bovidae* as the Indian water buffalo and zebu ox (de Moulin, 1924), but is limited to the first three vertebrae, while in the *E. bison* it reaches Th<sub>5</sub>.

This extensive reach of the thoracic origin of the *splenius* is characteristic only of sheep and goats (Martin & Schauder, 1938).

2. *M. ilocostalis* (Fig. 5, 6, 7, 10, 29 — II.) in its lumbar part above the final lumbar vertebrae, is strongly coalesced with the *m. longissimus dorsi*, below which it lies. Cranially from the 3rd lumbar vertebra the boundary between both muscles starts to be distinctly perceptible. The most cranial set of fasciculi of the lumbar part of the muscle in question inserts on the final rib.

Above the thoracic part of the vertebral column *m. iliocostalis* is situated laterally in relation to *m. longissimus* and passes to the lateral side of the ribs. It is composed of a series of muscle bundles which insert on the posterior border of the vertebral extremities of the ribs. Each of the bundles crosses two ribs, being attached to the third. This applies in the caudal part of the muscle (to rib IX or X), while in the cranial part the muscle bundles cross three ribs, being attached to the fourth. Cranially from rib III *m. iliocostalis* coalesces with *m. longissimus dorsi*, which is extremely thin in this place, and these two muscles insert together on the transverse process of the 1st thoracic vertebra. In one of the six specimens dissected by us ("Pluszcz") this most cranial insertion was situated on the transverse processes of the 7th cervical vertebra and would correspond to *pars cervicalis* of the *m. iliocostalis* in cattle. In the remaining five specimens of *E. bison* the *pars cervicalis* of the *m. iliocostalis* was not found.

3. *M. longissimus* from the descriptive aspect may be divided into the lumbo-dorsal and cervical parts. The latter is divided into three separate muscle units, i.e.: *longissimus cervicis*, *longissimus atlantis* and *longissimus capitis*.

a) *M. longissimus lumborum et dorsi* (Fig. 6, 7, 8 — Li.) is a massive muscle unit, extending along the dorsal side of the spine. In the posterior part it blends on the medial side with *m. spinalis* and with *m. iliocostalis* on the ventro-lateral side. It originates on *crista iliaca*, on the lateral surfaces of the spinous processes of the two first sacral vertebrae, the spinous processes of the lumbar vertebrae and on the same processes of the two last thoracic vertebrae. In the lumbar section it is also attached on the transverse processes and mammillary processes. At the

level of the 13th thoracic vertebrae, on the dorso-medial border of the muscle described, the division between *m. longissimus* and *m. spinalis* becomes apparent. The belly of the *longissimus dorsi* sends insertions downwards to the transverse processes of thoracic vertebrae and to the vertebral extremities of the ribs. At the level of the 3rd thoracic vertebra the muscle becomes very thin and finally disappears, inserting most cranially on the transverse process of the 7th cervical or 1st thoracic vertebra. In this part *m. longissimus dorsi* coalesces with the anterior part of *m. iliocostalis*.

The location and insertions of *m. longissimus dorsi* in the European bison are similar to the corresponding ones in cattle. Only the cranial attachment, which in cattle reaches to the transverse processes of the 7th cervical vertebra, reached to the first thoracic vertebra in three of the four E. bison which we dissected. In one ("Pluszcz") its behaviour was similar to that in cattle.

b) *M. longissimus cervicis* (Fig. 7, 8 — Lr.) is a cranial extension of *m. longissimus dorsi*. It originates on the transverse processes of the first six or seven thoracic vertebrae, under the respective bundles of *longissimus dorsi*. It is covered in this section by its venter, and in addition is attached on *fascia spino-transversalis*, passing above the cervical part of the spine and ending on the transverse and articular processes from the 3rd to 7th cervical vertebra. A tendinous band passes from the anterior edge of the venter halfway along its length, connecting this muscle with *m. longissimus capitis*.

The most caudal digitation of *m. splenius* is connected slightly below the place where it joins with the perimysium of this muscle.

*M. longissimus cervicis* in the E. bison behaves similarly to that in cattle.

c) *M. longissimus capitis* (Fig. 7, 8 — Lp.) originates on the articular processes of the cervical vertebrae from the 2nd to the 7th, and occasionally even from the 1st thoracic vertebra (Pluvius II, Plater). These insertions are situated laterally in relation to the corresponding insertions of *m. semispinalis capitis*. The flat muscle venter covers the anterior part of *m. semispinalis capitis* (in males only to a slight degree) and passes into the tendon, which terminates on *pars lateralis* of the occipital bone and on the temporal bone, jointly with the cranial digitation of *splenius*.

d) *M. longissimus atlantis* (Fig. 6, 7, 8 — La.) originates on the articular processes of the cervical vertebrae from the third to the sixth (with Pluvius II also on the 7th cervical and first thoracic vertebra). The thin venter situated laterally in relation to *m. longissimus capitis* terminates on *ala atlantis* jointly with *m. splenius*,



The muscles *longissimus capitis* and *longissimus atlantis* are usually described in cattle jointly as one muscle. In the E. bison we dissected they were clearly separated, both in the anterior part and in the vicinity of the vertebral insertions. The extent of the insertion on the articular processes of the cervical vertebrae is greater in the E. bison and shifted more caudally in relation to that described in cattle, since it extends in the E. bison in *m. longissimus capitis* from the 3rd to the 7th cervical and even in some cases to the 1st thoracic vertebra, while in cattle its extent is limited to between the 4th and 6th cervical vertebrae (Martin & Schuder, 1938). This also applies to *m. longissimus atlantis*.

This shift in a caudal direction of the vertebral insertion of *m. longissimus capitis* occurs among the *Bovidae* in the Indian water buffalo and the zebu ox (de Moulin, 1924), but this insertion does not reach to the thoracic section, as was the case in two of the five E. bison which we dissected.

The relatively wide extent of the insertion of *m. longissimus capitis* and *m. longissimus atlantis* occurs in the sheep and goat from 2nd thoracic to the 2nd cervical vertebra — (Reiser, 1903) and in *Cervus elaphus* (Kaman & Hempl, 1958).

4. *M. spinalis et m. semispinalis* in the E. bison are, like those in other ruminants, strongly fused in the lumbo-thoracic section. In the cervical part they form a partly separate muscle unit, described further as *m. spinalis cervicis et m. semispinalis capitis*.

a) *M. spinalis et semispinalis dorsi* (Fig. 6, 7, 8 — Sd, Sd') forms a group of muscle bundles participating in the composition of *funiculus medialis* (according to the terminology introduced by Bogorodsky & Stimpel). Two distinctly separated parts can be distinguished in this muscle: the lateral and medial.

The lateral part originates on *crista iliaca* and *tuber sacrale* of the ilium and on the spinal processes of the last three or four lumbar vertebrae and the two first sacral vertebrae. In the lumbar region the lateral part described is located medially from *m. longissimus* and is blended with it. At the level of the 13th thoracic vertebra *m. longissimus* and *m. spinalis* separate from each other. *M. spinalis* sends out several distinct muscle digitations which terminate on the spinal processes from 10th thoracic to the 7th cervical vertebra (Foetus ♂, Platyna, Plazma) or on the spinous processes from 10th to 1st thoracic vertebra (Pluszcz).

The medial part originates more cranially than that of the previous one and forms three or four tendinous muscle bands. In the lumbar section its upper edge connects with the lateral part and they then jointly insert on the apices of the spinous processes of the three first lumbar vertebrae and on the lateral surfaces of the spinous processes of the three final thoracic vertebrae. Cranially at the level of 4th—5th thoracic vertebrae

the above-mentioned bands lose their tendinous character and intertwine muscle bundles with the lateral part under which they lie. The division between the two parts of *m. spinalis* becomes indistinct in this region and the muscle bundles of both parts terminate jointly on the spinous processes, in the same way as that described in the lateral part.

The muscle bundles corresponding to *m. semispinalis lumborum* (Fig. 9 — So.) are visible in the lumbar section. They take the form of three tendinous bands which pass from the mammi-arto-articular processes of the two first lumbar vertebrae and the final thoracic vertebra. These bands blend with the medial part of *m. spinalis dorsi* described above.

The general pattern of the structure of *m. spinalis et semispinalis dorsi* in the E. bison is similar to the structure of this muscle in other ruminants. The extent of the insertions in the caudal part is further shifted caudad in relation to that described in cattle, as it extends over the spinous processes of the two first sacral vertebrae, while in cattle it is limited to the spinous processes of the lumbar part of the vertebral column (Stimpel, 1934). This shift caudally of the attachment of the lateral part of this muscle is, according to Stimpel (l.c.) typical of small ruminants.

In the European bison, in comparison with cattle, the origins of the bands corresponding to *m. semispinalis lumborum* are also shifted slightly backwards. In cattle it is only in a few cases that they reach the mammi-arto-articular processes of the first lumbar vertebra, and in the majority they are confined to these processes of the thoracic vertebrae (Stimpel, l.c.). In all the E. bison which we dissected the muscular bands of *m. semispinalis lumborum* ran from the two first lumbar vertebrae and the final thoracic vertebra.

b) *M. spinalis cervicis* (Fig. 8, 9 — Sc.) is a strong muscle originating on the spinous processes of the 7th cervical vertebra and the first two or three thoracic vertebrae (Platyna, Plazma, foetus ♂, Pluszcz). The flat venter, the fibres of which run cranio-ventrally, terminates on the spinous processes of the 3rd to 6th cervical vertebrae. The segmental structure is especially distinct in adult males (Pluszcz), while in females and young individuals (Plazma, Platyna, foetus ♂) the division into segments is less clear.

c) *M. semispinalis capitis* (Fig. 6, 7, 8 — Sm.) lies under *m. splenius* and is the third muscle in turn (in addition to *m. rhomboideus* and *m. splenius*) which participates in the formation of the characteristic shape of the E. bison. In the thoracal section it originates on the transverse processes of the thoracic vertebrae. Of the nine E. bison which we dissected, in one the origin covered Th<sub>1</sub> — Th<sub>7</sub>, in six Th<sub>1</sub> — Th<sub>8</sub> and in two Th<sub>1</sub> — Th<sub>9</sub>. The differences in the extent of the thoracic origins of *m. semispinalis capitis* were not connected with the sex of the animal dissected. In this

section the muscle described is partly covered by *m. longissimus dorsi* and forms a flat venter with fibres running cranio-dorsally.

In the cervical section the venter of *m. semispinalis capitis* thickens (especially in males) and has several origins on the articular processes of the 2nd — 7th cervical vertebrae. The muscle bundles have fibres running in a more perpendicular direction (in relation to the thoracic section) and form a wide venter (in males it is thinner, and in females thicker than *m. splenius*), covering the lamellar part of the nuchal ligament from the sides. Above the axis the venter passes into an aponeurosis, terminating laterally from the insertion of the nuchal ligament.

*M. semispinalis capitis* in the E. bison corresponds as regards the extent of its origins and insertions to the relations found in cattle. It is, however, more strongly developed and distinctly separated from *m. spinalis et semispinalis dorsi*, while in cattle it forms an undivided extension of these muscles on the neck region.

5. *M. multifidus* (Fig. 8, 9, 10 — Md, Mc.) is composed of a series of muscle bundles running between the articular or mammi-lo-articular processes of the one, and the spinous processes of the preceding vertebra.

This formation begins above the sacral part of the vertebral column and in this part, as in the lumbar part, the fleshy fibres run obliquely (cranio-dorsally), and the muscle bands terminate on the lateral surface of the spinous process of the previous vertebra, or on one vertebra further for the whole of its height.

In the thoracic part the muscle bundles of the muscle described run in a more perpendicular direction, do not completely cover the lateral surfaces of the spinous processes and do not cover more than three vertebrae.

In the cervical part the division into muscle bundles is less distinct. They insert on the articular processes of the cervical vertebrae and terminate at the base of the spinous processes, forming a uniform flat muscle venter covering from the sides the anterior part of *m. spinalis cervicis*, and are themselves covered by *m. longissimus capitis*. The most cranial insertion of this muscle is attached on the caudal border of the spinous process of the axis.

Our observations of *m. multifidus* in the E. bison agree with the description of this muscle by K r ü g e r (1927) in cattle and goats, except for the lumbar part of this muscle. In this part, according to the above author the shortest bundles of fibres usually cross one vertebra, while in the E. bison we found bundles running from vertebra to vertebra. It is only the question of the occurrence in the E. bison of *m. rotatores* which is not clear, these muscles according to K r ü g e r (l.c.) being the most distinctly separated from *m. multifidus* in ruminants. This separation was

not found in the E. bison which we dissected. This problem, and also the one dealt with by Krüger (l.c.), using domestic ruminants as examples, as to the formation of the articular surfaces of vertebrae and the mutual dependence of these two factors, require in my opinion further and more detailed examination.

### C. Group of the short muscles of the vertebral column

1) *M. obliquus capitis cranialis* (Fig. 9, 10 — Or.) in the E. bison is weaker in relation to *m. obliquus capitis caudalis*. It runs from the cranial border of the wing of the atlas and from the *fossa atlantis* and inserts on the occipital bone, along *sutura parieto-occipitalis*, to the base of the paramastoid process.

2) *M. obliquus capitis caudalis* (Fig. 9, 10 — Ou.) in the E. bison is a strongly developed muscle, originating on the lateral surface of the spinous process of the axis. The thick, triangular venter (the base of which is directed towards the atlas) inserts on the caudal border of the wings of atlas and cranially of this border.

3) *M. rectus capitis dorsalis major* (Fig. 9, 10 — Rj.). Its origin is located on the edge of the spinous process of the axis. The venter of this muscle exhibits tendencies to division into a superficial and a deep part. The latter on account of its extent corresponds to *m. rectus capitis dorsalis intermedius* described by certain authors (Kolda, 1950). In the E. bison we dissected this division was not sufficiently distinct to authorise differentiation into two independent muscle units. Both parts terminate on the cranium under the tendon of the *semispinalis capitis* with which it sometimes blends.

4. *M. rectus capitis dorsalis minor* — passes from *tuberculum dorsale atlantis*. The muscle venter, situated under the bellies of the previously described muscle, is stronger and better developed, but shorter than it, and terminates on the skull below its insertion.

5. *M. atlantooccipitalis* (Fig. 7, 8, 9, 10 — Ao.) described in the sheep and goat (Krüger, 1927) and, among wild ruminants, in *Capreolus capreolus* and *Cervus elaphus* (Reiser, 1903), also occurs in the E. bison. It is located in the extension of the insertion of the *m. longus atlantis*. It originates on the cranial tendons of the *m. longus atlantis* and *m. longissimus atlantis* on the atlas. The flat venter of *m. atlantooccipitalis* runs cranial ending in a flat aponeurosis on the temporal bone.

6. *M. m. intertransversarii* — in the E. bison, as in other mammals, can be distinguished only in the cervical and lumbar parts, the muscle bands of the lumbar part being completely fused with *m. longissimus dorsi* and *m. iliocostalis*.

*M. m. intertransversarii* in the cervical section are formed from muscle bands running between the transverse processes and articular processes of this section. Three groups can be distinguished among them, differing both as to the direction in which they run and as to their insertions.

The first group (Fig. 9 — It.) form bundles running from the transverse processes of the one vertebra to the articular processes of the next.

The second group (Fig. 9 — It') is formed by the bundles running between the transverse processes of two neighbouring vertebrae.

The third group (Fig. 9 — It''), the most strongly developed, is formed by bundles running from the transverse processes of one vertebra to the ventral edge of the ventral branches of the transverse processes of the next vertebrae. In this group the most strongly developed are the bundles running between the third, fourth and fifth cervical vertebrae.

#### D. The lateral and ventral muscles of the vertebral column

1. *Musculi scaleni* in the E. bison, as in cattle, are represented by two muscles, the *m. scalenus supracostalis* and *m. scalenus primae costae*.

*M. scalenus supracostalis* (Fig. 5, 6, 7, 8 — Ss.) is a flat muscle which is located on the lateral side of the thoracic wall, under the digitations of the serratus tharocis. It originates on the posterior border of the third rib in its lower part and by means of a short aponeurosis on the anterior border of the fourth rib in the upper part. The flat venter, the fibres of which run in the form of an arch, passes into a tendon which is attached on the transverse process of the 5th cervical vertebra.

*M. scalenus primae costae* divides in turn into two separate parts.

*Pars ventralis* (Fig. 5, 6, 7, 8 — Spv.) begins on the sternal half of the first rib. The thin venter of the muscle ends in an indistinct tendon on the lateral branch of the transverse process of the 6th cervical vertebra, and then together with *m. scalenus supracostalis* (beneath it) passes on to the transverse process of the 5th cervical vertebra.

*Pars ventralis* (Fig. 5, 6, 7, 8 — Spv) begins on the sternal half of the first rib in the form of a wide, flat venter and ends in distinct digitations under the lateral branches of the transverse processes of the 5th to 7th cervical vertebrae.

Despite the joint pattern of structure, the *musculi scaleni* in the E. bison exhibit, in comparison with the corresponding muscles in cattle, differences in the extent of the insertions. *M. scalenus supracostalis* inserts on the transverse process of the 5th, and not 6th to 3rd cervical vertebrae, as is the case with cattle. Insertions of this kind of the muscle discussed in E. bison are more like the relations found in the goat, in which *m. scalenus supracostalis* inserts on the 5th—4th cervical vertebrae (R e i s e r, 1903).

The dorsal part of the *scalenus primae costae* reaches in the E. bison to the transverse processes of the 5th and 6th cervical vertebrae, while in cattle it reaches to 7th cervical vertebra. The ventral part of this muscle does not differ as regards insertions from that found in cattle.

2. *M. longus colli* (Fig. 11) in the E. bison, as in other mammals, is divided into the thoracic part and cervical part. Both are located on the ventral surface of corresponding parts of the spinal column and differ both as to location and to direction in which the fibres run.

The thoracic part (Fig. 11 — b) is formed from muscle bundles located in pairs (on the left and right sides) of which the most caudal pair runs from the ventral crest and lateral surfaces of the body of the 6th thoracic vertebra. The fusiform venter is formed from the next pairs of muscle bundles running similarly from the fourth and second thoracic vertebrae, and passes cranial inserting on the way into the lateral surfaces of the bodies of the thoracic vertebrae, and finally inserts with mighty tendons on the ventral branches of the transverse processes of the 6th cervical vertebra.

The cervical part (Fig. 11 — a) has two layers. The muscle bundles originate along the lower border of the ventral branches of the transverse processes of the 6th cervical vertebra form the superficial layer, which ends on the *crista corporis* of the 4th cervical vertebra and the deep layer ending in the same place on the 5th cervical vertebra. The bundles originating on the 5th, 4th and 3rd cervical vertebrae behave similarly, that is the superficial layer covers one vertebra, and the deep one ends on the previous vertebra. The muscle bundles originating on the transverse processes of the axis form distinct bellies (left and right), which are attached on the ventral tubercle and on the posterior border of the ventral arch of atlas.

The description of *m. longus colli* given above in the E. bison agrees with the description of this muscle in cattle.

3. *M. longus capitis* (Fig. 6, 9 — Lk.) in the E. bison, and in particular in the males, is strongly developed and is located on the lateral side of the neck. The muscle in question passes from the ventral branches of the transverse processes of the cervical vertebrae, from the 3rd to the 6th (below the *m. longus atlantis*, which is also attached in this place). The long venter, which in its anterior end connects with *m. sternomastoides et cleidomastoideus*, terminates together with them on the temporal bone and on the base of the skull.

4. *M. longus atlantis* (Fig. 5, 7, 8, 9 — Lt.) passes from the ventral branches of the transverse processes of the 2nd to the 6th cervical vertebrae (in the case of "Tatra" to the 5th) under the corresponding insertions

of *m. longus capitis*. Stronger in relation to the latter, the muscle venter exhibits tendencies to bifurcation and terminates on the edge of the wings of atlas.

The behaviour of *m. longus capitis* and *m. longus atlantis* in the E. bison is similar to that in cattle, except that they are more strongly separated from each other, while in cattle this separation is not so distinct. As a result certain authors have described the two muscles as one muscle unit.

5. *M. rectus capitis lateralis* (Fig. 7, 8, 9 — Rl.) forms a strong short venter, originating in the *fossa atlantis* (in the depression located caudo-ventrally to *foramen alare* and terminates on the medial surface and caudal border of the paramastoid process of the occipital bone.

6. *M. rectus capitis ventralis* originates on the caudal border of the ventral arch of the atlas (laterally from the ventral tubercle). The large, thick muscle venter terminates on the bony prominences of the basilar part of the occipital bone.

7. *M. sternohyoideus* (Fig. 2 — J.) originates on *manubrium sterni* jointly with *m. sternothyreoides*, partly above and below the insertion of *m. sternomastoideus*. Crossing the latter, immediately after leaving the insertion it passes to the ventral side of the trachea, ending on the body of the hyoid bone.

8. *M. sternothyreoides* originates together with the former one, initially coalescing with it. In its continuation it runs laterally in relation to *m. sternohyoideus*, terminating on the thyroid cartilage of the larynx.

*M. m. sternohyoideus* and *sternothyreoides* in their insertions and course do not exhibit differences from the same muscles in cattle.

9. *M. omohyoideus* (Fig. 2, 5, 6, 8 — Om.) in the E. bison, as in other ruminants, passes from *fascia colli profunda* at the level of the transverse processes of the third and fourth cervical vertebrae. The flat and relatively wide muscle venter, the fibres of which run cranio-ventrally, ends on the hyoid bone. On its way the venter connects with *m. sternomastoideus*

#### E. The muscles of the thoracic wall

1. *M. serratus dorsalis* in the E. bison is divided into *m. serratus dorsalis cranialis* and *m. serratus dorsalis caudalis*.

a) *M. serratus dorsalis cranialis* (Fig. 6 — Si.) originates on *fascia spino-transversalis* at the level of the fourth or fifth thoracic vertebra, forming a flat venter with fibres running caudo-ventrally. The venter, by means of faintly perceptible digitations, inserts on the anterior borders from the 6th to 8th ribs.

b) *M. serratus dorsalis caudalis* (Fig. 29 — Se.), in the foetus and the 6-months-old "Platyna" which we dissected, formed a uniform flat muscle venter, passing from *fascia lumbo-dorsalis* at the level of the final thoracic vertebra and first lumbar vertebra and terminating on the caudal border of the two last "Platyna" or the three last (foetus) ribs. In the remaining males (Pluszcz, Punkt) this muscle forms three separate digitations inserted on the caudal borders of the three final ribs. Each of the digitations divides into a superficial part covering *m. intercostalis externus*, and a deep part, penetrating under it and terminating lower in relation to the superficial part, jointly with *m. intercostalis internus*, with which it fuses.

*M. serratus dorsalis* in mammals exhibits great specific and individual variation. This variation is manifested by differences in the extent of the costal insertions of both parts of this muscle, or even the retrogression of one of them.

*M. serratus dorsalis cranialis s. pars inspiratoria* is formed in cattle from three to six digitations, having costal insertions from the 4th, 5th or 6th to 8th or 9th rib (Martin & Schauder, 1938). In sheep the costal insertion is situated on the anterior border of the 4th, 5th or 6th rib (Reiser, 1903), in goats from the 4th to 6th, or 7th rib (Reiser, l.c.). In the *Cervus elaphus* the extent of the costal insertions of the *serratus inspiratorius* covers ribs 5, 6, 7 or 8 (Reiser, l.c.). In the Indian water buffalo and the zebu ox this part is strongly reduced or does not occur at all (de Moulins, 1924).

*M. serratus dorsalis caudalis s. expiratorius*, is formed in cattle from 4 to 5 muscle digitations, terminating on the caudal borders of the 10th or 11th to the 13th ribs (Martin & Schauder, 1938), in sheep and goats from the 9th, or 10th to 12th, or 13th (Reiser, 1903), in *Cervus elaphus* from the 10th to 13th rib (Reiser, l.c.). In the Indian water buffalo *pars expiratoria musculi serrati dorsalis* inserts by means of digitations from the 6th to 13th rib (de Moulins, 1924).

From the description given above it is clear that *m. serratus dorsalis* is characterised by individual variation in the E. bison also. The extent of the costal insertions is different from that in the other ruminants considered for purposes of comparison.

2. *M. transversus costarum* (Fig. 5, 7 — Tc.) in the E. bison is located on the lateral surface of the thorax in the form of a wide and relatively thick venter, which reaches from the sternal extremity and costal cartilage of the first rib to the 4th costal cartilage. The extent of this muscle in the E. bison is shorter than in cattle, in which it reaches to the 6—7th costal cartilage (Martin & Schauder, 1938), and corresponds to the relations found in small wild and domestic ruminants, in which it reaches the 4th costal cartilage (Reiser, 1903).



3. *M. m. levatores costarum* (Fig. 8, 9 — Lc.) consist of a group of muscle bundles running from the costal tubercles and transverse processes of the thoracic vertebrae to the anterior border of the next rib. They occur in the E. bison in all the intercostal spaces, being less strongly developed between the 1st and 9th rib, and caudally separating more distinctly from the intercostal muscles.

4. *M. m. intercostales externi et interni* behave similarly to the corresponding muscles in cattle.

*M. m. intercostales externi* are formed of strongly tendinous muscle bundles with fibres running caudo-ventrally. In the final three or four intercostal spaces the direction in which the fibres run becomes more horizontal in relation to the fibres in the anterior intercostal spaces and they intertwine strongly with the internal ones. *M. m. intercostales interni* have fibres running in the opposite direction to that of the external ones.

5. *M. retractor costae* (Fig. 29 — Rc.) runs from the transverse process of the first lumbar vertebra and ends on the posterior border of the final rib, coalescing by means of the final tendon with the final digitation of the *serratus dorsalis caudalis*. The upper edge of *m. obliquus abdominis internus* thrusts in between these muscles.

6. *M. transversus thoracis* (Fig. 13 — Tt.) in the E. bison forms a symmetrical accumulation of muscle bundles located on the internal surface of the sternum and on the costal cartilages. These bundles run from the middle line of the dorsal surface of the sternum beginning from the 2nd sternebra. Caudally they terminate in turn on the costal cartilages from the 2nd to the 8th and on the sternal extremities of the corresponding ribs. The two final portions attached to the 7th and 8th cartilages are clearly separated. The whole corresponds to the structure of *m. transversus thoracis* in cattle. The muscle bundles of the opposite sides do not connect with each other in the medial line, and their location and insertion correspond to the "paired-hoof" type of this muscle described by T u r k i e w i t s c h (1928).

#### F. The abdominal muscles

1. *M. obliquus abdominis externus* (Fig. 30 — Oe.) is included in the group of muscles forming the abdominal walls, and its structure in the European bison does not in principle differ from the relations encountered in other ruminants. It originates on the external surface of the final 7—8th ribs in the form of a series of digitations thrusting between the digitations of the thoracic part of the *serratus ventralis*, and more caudally, under *m. latissimus dorsi*. The flat muscle formed by the above-

-mentioned digitations, the fibres of which run obliquely, caudo-ventrally, forms a uniform whole. The upper edge coalesced with *fascia lumbo-dorsalis* reaches caudally to *tuber coxae*. The cranio-ventral part thrusts between *m. pectoralis profundus* and *m. rectus abdominis*. The whole passes into a strong aponeurosis coalesced with *tunica flava abdominis*. This aponeurosis widens considerably caudally and connects with the aponeurosis of *m. obliquus abdominis internus* surrounding *rectus abdominis* from below. In the medial line the lower edge of this aponeurosis connects with the one like it from the opposite side. The caudal edge is attached along the shaft of ilium and partly on the pubic bone.

2. *M. obliquus abdominis internus* (Fig. 29 — Oi.) is located under *m. obliquus abdominis externus*, being included in the composition of the abdominal wall. It originates on *tuber coxae* and *fascia lumbodorsalis*. The flat muscle, the fibres of which run fanwise in a cranio-ventral direction, can be divided into two parts for purposes of description.

The dorsal part, with fibres running more parallel, is attached on the caudal edge of the final rib, to the costo-chondral junction. The upper edge of this part attached on the transverse processes of the lumbar vertebrae, thrusts between *m. serratus dorsalis* and *musculus retractor costae* and terminates on *tuber coxae* and on *ligamentum inguinale*.

The ventral part, thinner than the previous one, has fibres running more obliquely (near the caudal edge they run almost perpendicularly). It passes in the form of an arch (at the level of a imaginary line drawn from the costo-chondral junction of the final rib to the fold of the flank) into a aponeurosis which connects in *linea alba* with the one like it from the opposite side. This aponeurosis is strongly coalesced with the aponeurosis of *m. obliquus abdominis externus* and covers *m. rectus abdominis* from the exterior.

The general pattern of the structure of *m. obliquus abdominis internus* in the E. bison is similar to the structure of this muscle in cattle. The division of this muscle into two parts, described by M a x i m e n k o (1928) in cattle and other ruminants, takes place in the E. bison also. This division is manifested in the difference in the direction in which the fibres run and in the different thickness of the muscle layer, while the transverse band of fibrous tissue (*inscriptio tendinea*) separating these parts, which is present in cattle, is here absent.

3. *M. rectus abdominis* (Fig. 12, 29 — Ra.) in the E. bison is a flat, wide muscle, originating by means of a distinct tendon on the caudal tendon of the *m. transversus costarum* and on the costal cartilages beginning from the 5th caudad, and a distinctly separated medial part on the ventral surface of the sternum (at the level of the junction of the sternum with the costal arch). Both parts connect caudally, maintaining distinct bound-

aries only in the places where nerve branches and vessels pass through them. The flat venter is divided by five tendinous inscriptions. Caudally the muscle terminates on the pubic bone and on the prepubic tendon.

The location and number of tendinous inscriptions in *m. rectus abdominis* in the E. bison correspond to the structure of this muscle in cattle. The sternal attachment, which divides up and is partly tendinous (on the costal cartilages) and partly muscular (on the ventral surface of the sternum) occurs in sheep and in *Cervus elaphus*, but in these ruminants the number of tendinous inscriptions is seven (Reiser, 1905).

4. *M. transversus abdominis* (Fig. 12 — Ts.) forms the deepest muscular layer of the abdominal walls. It passes in a flat aponeurosis from the transverse processes of the lumbar vertebrae and from the caudal edge of the final osseous rib, and further on attaches on the medial surface of the costo-chondrial junctions of all the asternal ribs as far as the final sternal rib. The muscle venter passes in an arch (along a hypothetical line connecting the xiphoid cartilage with the region of the stifle joint) into an aponeurosis covering the dorsal surface of *m. rectus abdominis*. In the intermedial line it connects with the corresponding one from the opposite side.

The structure of *m. transversus abdominis* in the E. bison is similar to the structure of this muscle in cattle, as far as its insertions are concerned. It differs, however, by reason of the more strongly developed *pars aponeurotica*.

### 3. THE THORACIC LIMB

#### A. Muscles of the shoulder and arm

1. *M. deltoideus* (Fig. 14, 15, 29, 30 — D, D'.) in the E. bison is a flat, broad muscle which inserts along the *spina scapulae* down to the acromion, and coalesces with *m. infraspinatus* lying beneath it, throughout almost the entire surface. In the cranial part it is thinner, and thicker caudally. Beginning from the caudal edge of *m. infraspinatus*. *M. deltoideus* is surrounded by a joint fascial sheath with *m. teres minor*. It mixes numerous fibres with *m. teres minor* and also with the lateral head of *triceps brachii*, which it covers from the sides. It terminates on the ventral end of *crista humeri* and on the deltoid tuberosity of humerus. In the caudal part of this muscle the part which passes by means of an aponeurosis on to the lateral head of *triceps brachii* separates from it.

The division, occurring in all ruminants, of this muscle into *pars acromialis et pars scapularis*, was perceptible in the E. bison which we dissected, but was not so distinct as that in cattle.

2. *M. supraspinatus* (Fig. 5, 14, 15, 16, 30 — S.) originates in the supraspinous fossa and on the anterior angle and anterior edge of the scapula.

The muscle venter, protruding cranially slightly beyond the anterior edge of the scapula, attains its greatest dimensions at the level of *tuber scapulae*. Above the shoulder joint it divides into two branches of which the lateral one, as a rule stronger, is attached widely on *tuberculum maius craniale*, and the medial one on *tuberculum minus craniale*.

3. *M. infraspinatus* (Fig. 5, 15 — I.) occupies the infraspinous fossa and the greater part of it blends with *m. deltoideus*, which covers it. It is attached on the caudal surface of the spine of scapula in infraspinous fossa and on the caudal angle and in its "free" part (from *m. deltoideus*) it forms a thick, flat venter terminated by a strong tendon on *facies musculi infraspinam* and by several tendinous fibres on *tuberculum maius caudale*.

Poleiner's statement (1932) asserting that contrary to cattle, the tendon of insertion of this muscle in the E. Bison was less tendinous, was not confirmed by our observations.

4. *M. teres minor* (Fig. 15 — Ti.) is a muscle almost entirely fused with *m. infraspinatus* and is differentiated from it only by its extent. The fibres of its venter form a whole which, lying caudally in relation to the main mass of *m. infraspinatus*, does not terminate on *tuberculum maius caudale*, but runs slightly further to *facies teres* (although only faintly perceptible in the E. bison) and to the upper section of *crista humeri*.

5. *M. subscapularis* (Fig. 16 — Su, Su', Su'') located on the medial side of the scapula, permits of distinguishing three parts clearly separating from each other. The cranial one, in the upper section, coalesces with *m. supraspinatus* and is the thickest of the three. The middle one occupies *fossa subscapularis* and is strongly tendinous. Its fibres run at an acute angle in relation to the cranial part and thrust under it to pass in turn into a joint aponeurosis. The caudal part, lying behind and partly under the middle one, coalesces in the upper section with *m. teres major*. All three connect at the level of the shoulder joint in a common tendon (previously arranging themselves one on top of the other in the order given) which thrusts under the distal head of *coraco-brachialis* and inserts on *tuberculum minus caudale* and below in its vicinity.

During the dissection of the thoracic limbs of two females (Poziomka and Purata), we encountered a fairly distinctly separating fourth part of this muscle, which must be considered as corresponding to that part described by Leichter (cit. acc. to Martin & Schauder, 1938) in *m. subscapularis* in the goat.

6. *M. teres major* (Fig. 14, 15, 16 — Ta.) originates on the caudal angle of the scapula and in the upper section of the caudal edge, coalescing near its origin with *m. subscapularis*. The flat venter thrusts under *m. latissimus dorsi*, with which it also intertwines fibres and terminates medially to it on *tuberositas teres* of the humerus.

7. *M. coracobrachialis* (Fig. 16, 18 — Cb.) is a flat muscle, the venter of which is divided by a branch of *N. musculo-cutaneus* into two parts: proximal and distal. Both originate in a distinct tendon on scapular tuberosity. The proximal part is located more superficially and terminates above teres tuberosity. The distal part in the initial section is located deeper than the previous one and terminates below teres tuberosity, reaching *crista epicondylis medialis*. This division into the different parts is visible in older animals (Poziomka, Plazma, Plastus, Pluszcz). It cannot be seen at all in the calves of *E. bison* (Poda), apart from the place where the nerve crosses and from a certain difference in the direction in which the fibres run.

8. *M. tensor fasciae antebrachii* (Fig. 16, 30 — Tf.) originates on the caudal edge of the scapula and on the aponeurosis of *m. latissimus dorsi*. It passes on to the medial side of *caput longum* of triceps in the form of a flat venter, terminating on olecranon and in *fascia antebrachii*.

9. *M. triceps brachii* occupies the angle between the scapula and humerus, forming a group of muscles in which four distinct heads can be distinguished.

*Caput longum* (Fig. 14, 15, 16, 29, 30 — Tr.) originates on the caudal angle of the scapula and below its caudal edge, up to the level of the neck of this bone. The triangular muscle venter, with fibres running caudo-ventrally, terminates without the visible participation of the tendinous component on the olecranon, covering from the medial side, from the top, and laterally, the tendon of the lateral head.

*Caput laterale* (Fig. 14, 15, 29 — Tr') originates on the lateral side of the humeral bone at the level of *crista anconeae* and on the caudal border of tendon of *m. teres minor*. It is covered in its anterior part by *m. deltoideus* and in four out of the six *E. bison* dissected by us fuses with it. Initially thick, the flat venter next terminates on the lateral surface and caudal border of *tuber olecrani*.

*Caput mediale* (Fig. 16 — Tr'') originates above and below teres tuberosity. It is covered in its anterior part by *m. coracobrachialis*, and in the posterior by *caput longum*. Above the medial epicondyle of the humerus this head passes into a tendon, terminating on the medial surface of the *processus olecrani*.

*Caput accessorium* (Fig. 18 — Tr''') originates at the level of the lower  $\frac{1}{3}$  of the humerus on its caudo-medial side. The flat, thin muscle venter, with fibres running lengthways, terminates on the lateral side of *processus olecrani* under the lateral head of the muscle described.

R. Poleiner (1932) in his otherwise very detailed description of *m. triceps brachii* in the *E. bison* makes absolutely no mention of the *caput*

accessorium. He does not even refer to its absence when discussing differences compared with cattle, which gives rise to the suspicion that this muscle unit was overlooked. In all the specimens dissected by us the caput accessorium of *m. triceps brachii* is relatively strongly formed.

10. *M. anconeus* (Fig. 17 — A.) forms a flat muscle venter, located laterally in relation to the accessory head of *triceps brachii*, and directly contiguous with the humerus. It originates on the lateral condyloid crest and passes on the medial surface of the lateral epicondyle where it coalesces with the tendon of the lateral head of the *triceps*.

This muscle is relatively strongly developed in the E. bison, and corresponds to the relations encountered in small domestic ruminants, but does not possess an independent terminal tendon, as is the case in *Capreolus capreolus* and *Cervus elaphus* (Reiser, 1903; Komarek, 1958).

11. *M. biceps brachii* (Fig. 14, 15, 16, 18, 20 — Bb.) originates in a massive tendon on *tuber scapulae*. It passes into the intertubercular groove between the branches of *m. supraspinatus* and extends into a fusiform venter, running on the cranio-medial side of the humerus. It terminates with one tendon on the collateral medial ligament of the elbow joint, on *tuberculum ligamentosum mediale* of radius and on the radial tuberosity, and with a second tendon on the medial border of the radius.

On the medial surface of *m. biceps* in old animals an elongated groove is visible which indicates a tendency, as it were, to a division of this muscle into two secondary bellies. In the animals we dissected we did not find the presence of *lacertus fibrosus* in the form present in cattle. Only in old individuals (Pluszcz, Poziomka) does this muscle exhibit coalescence with the *fascia antebrachii* which is thickened on the medial side.

12. *M. brachialis* (Fig. 14, 15, 18 — Bc.) originates on the neck of the humerus in the caudal half of its circumference, continuing to the beginning of the anconeal crest. The strong muscle venter is located in the musculospiral groove of the humerus, initially covered by the lateral head of the *triceps brachii* and by *m. deltoideus*. On reaching the lateral side it passes between *m. brachiocephalicus* and *m. extensor carpi radialis*, and next runs on to the medial side to terminate on the medial border of the radius in the vicinity of *tuberculum ligamentosum mediale*. In the ventral end *m. brachialis* is covered by a tendon of insertion of *m. biceps brachii*. A strong tendinous band passes from the insertion to terminate on the ulna near *spatium interosseum antebrachii*.

The insertion, described above, of *m. brachialis* in the E. bison exhibits intermediate relations between those encountered in cattle, where the insertion is located on *tuberositas radii*, and in small domestic ruminants

in which this insertion is located on *processus coronoideus ulnae* (Reiser, 1903). *M. brachialis* terminates in *Capreolus capreolus* and *Cervus elaphus* in a similar way to that in these latter ruminants (Reiser, l.c., and Komarek, 1958).

## B. Muscles of the forearm and manus

### a. Extensor division

1. *M. extensor carpi radialis* (Fig. 14, 15, 16, 17, 18, 20, 29, 30 — Er) originates on the lateral supracondyloid ridge, on the lateral epicondyle and in the radial fossa. Near the origin it coalesces with the venter of *m. extensor digiti tertii proprius*. Slightly lower, the venter of this muscle undergoes division into two bellies: the superficial and the deep, which above the carpus pass into two distinctly separating tendons. The superficial one, running medially, terminates on tuberosity Mc. III. The deep one — lateral — terminates more laterally.

In adult individuals a tendinous band passes through the deep venter, beginning above the *fossa radialis* and joining the lateral tendon. The tendons of insertion are crossed from the front by the tendon of *m. abductor pollicis longus*.

R. Poleiner (1932) in his description of this muscle in the E. bison refers to the division of the muscle venter, describing in detail the course followed by both tendons. Reiser (1903) also writes of the division of *m. extensor carpi radialis* in ruminants and referring to Müller & Leisering as authority for this, considers it as usually occurring in sheep, and in certain cases also in cattle. Martin & Schauder consider the division of *m. extensor carpi radialis* as a characteristic of the muscle system of small ruminants. All the above authors consider this accessory head of *m. extensor carpi radialis* as corresponding to *m. extensor pollicis longus* of the five-fingered limb.

2. *M. extensor carpi ulnaris* (Fig. 14, 15, 17, 19, 29, 30 — Eu.) originates on the *epicondylus extensorius* and on *crista epicondyli lateralis*, and in one of the E. bison which we dissected (Purata) also on the margin of the *fossa radialis* of the humerus. The large venter runs towards the fingers and above the carpus passes into a tendon ending in one branch on the accessory bone of carpus, and in the other on Mc. IV.

According to Poleiner (1932) the tendon of insertion of this muscle sends out fibres to the rudimentary Mc. V, which we noted only in one case (Poziomka).

3. *M. abductor pollicis longus* (Fig. 17, 29, 30 — Ap.) originates on the dorso-lateral surface of the forearm bones in a flat, tendinous triangular venter. Above the carpus it passes into a tendon crossing from the front

the tendon of insertion of *m. extensor carpi radialis*, and terminates on the medial side of the proximal extremity of Mc. III.

Martin & Schauder (1938) and Kolda (1950) in describing this muscle in cattle do not distinguish the ulnar part of origin. The presence of this part of the insertion is characteristic of sheep, goats and *Cervus elaphus* (Reiser, 1903).

4. *M. extensor digitalis communis* (Fig. 14, 15, 17, 29, 30 — Ec.) begins with a superficial head on *epicondylus lateralis* and in *fossa radialis* of the humerus, and with a deep head on the forearm bones, in the neighbourhood of the proximal interosseous space. Halfway along the radius both heads join, then pass into a tendon, the location of which was described together with the tendon of *m. extensor digiti tertii proprius*. Above the metacarpo-phalangeal joint this tendon bifurcates and runs to the extensor processes of the third phalanges.

5. *M. extensor digiti tertii proprius* (Fig. 14, 15, 17, 18, 29, 30 — Et.) originates on the *epicondylus lateralis* of the humerus (on the cranio-lateral side) above the origin of the *extensor digitalis communis*. In the upper section the bellies of these muscles exchange fibres. At the level of the lower  $\frac{1}{4}$  of the radius, the slender venter passes into a tendon, which runs more dorsally than the tendon of the *extensor digitalis communis*. In the section between the carpus and tuberosity of Mc. III both tendons are surrounded by a common synovial sheath. On leaving the sheath the tendon of the *m. extensor digiti tertii proprius* runs more medially, inserting on Ph. II and Ph. III of the third digit. This tendon connects in the final part of its course with the tendon of *m. interosseus medius*.

6. *M. extensor digiti quarti proprius* (Fig. 14, 15, 17, 19, 29, 30 — Eq.) originates on the *epicondylus extensorius* of the humerus, near *tuberculum ligamentosum laterale* of the radius and on the lateral border of the ulna, to which it is attached by means of a strong fascia surrounding the muscle venter. By means of this fascia it is in addition attached to the dorsal ligament of the carpus, to which strong tendinous bands pass out from it. Above the carpus the fusiform muscle venter passes into a tendon running towards the fingers, widening along Ph. I owing to reinforcement by the tendon of *m. interosseus medius*. It divides into two branches, attached on Ph. II and Ph. III of the fourth finger.

#### b) Flexor division.

1. *M. flexor carpi radialis* (Fig. 16, 18, 19, 20 — Fr.) is a flat muscle originating on the medial epicondyle of the humerus and on the medial ligament of the elbow joint. The muscle venter at the level of the lower  $\frac{1}{3}$  of the radius in young individuals, and the upper  $\frac{1}{3}$  in adults, passes



into a tendon running along the medial edge of this bone. This tendon above the carpus receives a synovial sheath, strongly coalesced with the *fascia antebrachii*, which is thick in this place, and passing on the medial side of *canalis carpalis*, inserts on the second carpal bone, and partly on Mc. III.

Poleiner (1932) in his description of the final tendon of this muscle did not take into account the insertion on the carpus.

2. *M. flexor carpi ulnaris* (Fig. 16, 18, 19 — Fu.) located most caudally in the flexor group, originates almost without a tendon on the medial condyle of the humerus and on the flat aponeurosis, thrusting under the medial head of the *triceps brachii* on the olecranon. The group of muscle fibres running from this aponeurosis forms a distinct ulnar head, although closely coalesced with the main venter, the whitely-gleaming tendon of insertion of which runs on the caudal edge of the main venter. It is specially distinctly visible in young animals. The tendon of insertion of the *flexor carpi ulnaris* which begins at the level of the carpus, coalesces with *fascia antebrachii* and inserts on the accessory carpal bone, partly also on Mc. IV.

3. *M. flexor digitalis superficialis* (Fig. 17, 18, 19, 20 — Fs, Fs') originates on the medial epicondyle of the humerus and divides into two heads blended with each other in the upper part. The superficial head passes into a tendon at the level of the carpus, while the deep head becomes tendinous slightly higher up. At the level of the carpus both tendons, which are separated from each other by *ligamentum carpi volare superficiale*, are located superficially in relation to the tendon of the deep digital flexor. These tendons coalesce halfway along the metacarpus to divide at the level of the metacarpo-phalangeal articulation into lateral and medial branches. These branches, together with the tendons of the superficial head of the *interosseus medius*, surround the tendons of the *flexor digitalis profundus*, forming a sheath round them. Both final branches of the tendon of the muscle described divide once again and each of them ends laterally on the Ph. II.

A band runs from the anterior edge of the venter of the deep head of the superficial digital flexor at the level of the lower  $\frac{1}{3}$  of the radius which connects with the tendon of the deep digital flexor. This is *m. interflexorius proximalis* (Fig. 20 — a.) which in all the individuals which we dissected contains little muscular tissue. The situation is different with *m. interflexorius distalis* (Fig. 20 — b.) (it connects the humeral head of the deep digital flexor with the deep head of the superficial digital flexor) which regardless of the age of the animal dissected, exhibited the presence of muscle fibres,

The occurrence of interflexor muscles in the muscle system of the thoracic limb, has been described both in cattle and in small domestic ruminants (Pitzorne, 1905). Komarek (1958) also described it in *Cervus elaphus*.

Poleiner (1932) notes the existence of *m. interflexorius* in European bison without stating precisely whether he found the presence of both, or of one. Our observations show that both *musculi interflexores* occur in the E. bison.

4. *M. flexor digitalis profundus* (Fig. 17, 18, 19 — Fp.) is a strong flexor muscle consisting of three independent heads, as follows: the humeral radial, and ulnar heads.

*Caput humerale* (Fig. 19, 20 — Fph.) originates on the lateral epicondyle and on its crest, and is covered in this place by *m. triceps brachii*. The massive venter of this head, threaded with numerous tendinous bands, exhibits a tendency to division into two or three bellies. They pass above the carpus into a flat tendon, concave medially. In this hollow, on the boundary of the transition of the venter into tendon, *m. interflexorius distalis* is located, in young animals completely muscular, in older specimens slightly tendinous, the tendon of which connects with the tendon of insertion of the deep head of the superficial flexor (see description of this muscle).

*Caput radiale* (Fig. 20 — Fpr.) is located the deepest in the immediate vicinity of *ossa antebrachii*. It inserts on the medial side of the caudal surface of the radius and partly near the interosseous space. The narrow flat venter passes into a tendon, which connects in the region of *canalis carpalis* with the tendon of the humeral head. The difference, emphasised by Poleiner (1932) in the origin of this head in relation to that in cattle does not appear justified to us. In all the individuals dissected by us (except Platyna) the origin did not extend beyond the lower half of the radius.

*Caput ulnare* (Fig. 14, 15, 16, 17, 19, 20 — Fpu.) originates on the lateral surfaces and caudal border of the olecranon, forming a triangular venter thrust between *caput humerale* and *m. extensor carpi ulnaris*. At the level of the proximal interosseous space the belly of the ulnar head passes into a strong, flat tendon, lying caudo-laterally on the humeral head of this muscle and coalescing with its tendon of insertion above the carpus.

All the heads described have a common tendon located most deeply within *canalis carpalis* and contained at this level in a synovial sheath reaching to the level of the carpo-metacarpal joint. At the level of the metacarpus the tendon of the deep digital flexor is located under the tendon of the superficial digital flexor and, not reaching the metacarp-

-phalangeal joints, bifurcates into two branches. At the level of the metacarpo-phalangeal and proximal interphalangeal joints these branches are surrounded by sheaths formed by the tendons of the superficial digital flexor and the branches of the tendons of insertion of the superficial part of the *interosseus medius*. They then terminate on the third phalanges.

5. *M. pronator teres* was not found by us in young specimens. The scanty group of muscle fibres which can be distinguished in *fascia antebrachii* in this region can only be considered as evidence that it is present in adult animals.

P o l e i n e r (1932) does not mention this muscle in the E. bison at all, neither does he include its absence in the chapter devoted to the differences between the muscular systems of the E. bison and cattle. R e i s e r (1903) found that this muscle was absent in *Cervus elaphus* and *Capreolus capreolus*.

6. *M. interosseus medius* (Fig. 17, 18, 19, 25, 26 — Im.) located directly on the volar surface of the metacarpus, is strongly tendinous in the E. bison and seen from the exterior gives the impression of a tendon, but after making lengthways cuts it is possible to find some bundles of red muscle fibres in its interior. It consists of two parts, beginning as a uniform musculo-tendinous formation on the *ligamentum carpi volare profundum* and on the volar surface of the proximal extremity of the metacarpus. Slightly below the origin it divides into superficial and deep parts.

The deep part divides halfway along the metacarpus into three branches, the lateral and medial of which run to the external proximal sesamoid bones, and the intermedial branch divides up once again into three. The weaker, collateral branches run to the internal proximal sesamoid bones. The intermedial branch thrusts under the intersesamoid ligament, enters the interdigital space and passes out on the dorsal side. Here it joins by means of two thin twigs with the tendons of the *extensores proprii* of the third and fourth digits.

The superficial part, slightly higher than the one previously described, also divides into three branches. The intermedial branch divides in the lower  $\frac{1}{4}$  of the metacarpus into two and jointly with the branches of the tendon of insertion of the superficial digital flexor covers the tendon of the deep digital flexor. The collateral branches are very weakly formed and run in the direction of the accessory digits (II and V).

The above description agrees with the description of this muscle in cattle (Š t ě r b a, 1958).

## 4. THE PELVIC LIMB

## A. Inner and ventral muscles of the rump

1. *M. iliopsoas* exhibits in European bison, as in other species, a distinct division into two units:

a) *M. psoas major* (Fig. 10, 24 — Pj.) originates on the vertebral extremity of the 13th rib, coalesces with *m. transversus abdominis* just behind this rib, and inserts on the bodies and ventral surface of the transverse processes of the lumbar vertebrae. The venter, at first broad and flat, becomes round at the level of the sacrum and is surrounded from the sides and above by *m. iliacus*. The strong, long tendon of this muscle terminates on *trochanter minor* of the femur.

b) Two heads with different origins can be distinguished in *m. iliacus*.

*Caput laterale* (Fig. 23, 24, 29 — Ia.) is stronger and originates on the *tuber coxae*, *margo semilunaris* and on *facies pelvina* of the wings of the ilium and sacrum. The concave belly surrounds *m. psoas major* from the side and from above, interchanging fibres with it.

*Caput mediale* (Fig. 24 — Ia.) is weaker, and originates on the pelvic surface of the wing of the sacrum and on the shaft of the ilium. A flat venter interchanging with *m. psoas minor* surrounds *m. psoas major*, blending with it, and then with *caput laterale*. Both heads terminate in a short aponeurosis on *trochanter minor*.

The description given above of *m. iliopsoas* does not in principle differ from the description of this muscle in cattle, of course taking into account the difference in size.

2. *M. psoas minor* (Fig. 24 — Pm.) is the most medially located of this group. It originates on the caudal part of the lateral surface of the body of the 13th thoracic and on the lateral surfaces of the bodies of all the lumbar vertebrae. The fusiform belly at the level of *promontorium ossis sacri* begins to become tendinous, passing into a tendon located laterally from the lateral branch of origin of the *sartorius*. It terminates on *tuberculum psoadicum* which is very faintly marked in the E. bison.

3. *M. quadratus lumborum* is located most dorso-laterally of the whole group. Its structure is segmental in character, exhibiting individual variation in arrangement. It originates, in all the individuals which we dissected, in muscle bundles which run from the caudal part of the body of 11th thoracic vertebra. Similar bundles also run from the bodies of the 12th and 13th thoracic vertebrae. In some individuals these bundles all terminate on the transverse process of the first lumbar vertebra, and in others only the final one terminates in this way, while the two previous ones terminate on the transverse process of the last thoracic vertebra and

on the vertebral extremity of the last rib. In the lumbar section the bundles of this muscle run from the transverse processes of one vertebra to the transverse processes of another vertebra, crossing sometimes over one, and sometimes even over two vertebrae. The final portion of the bundles of this muscle terminates on the inner surface of the wing of the ilium. Some few fibres insert on the ventral surface of the wings of sacrum also but this we found in one individual only.

4. *M. obturator internus* is a flat, fanshaped muscle, originating on *pars sacrotuberale* of the sacro-sciatic ligament, on *tuber ischii*, *arcus ischiadicus* and along the dorsal side of *symphysis pelvis*. The flat belly with fibres running in convergent radiation is located in the region of *foramen obturatum*, passing through this foramen and forming a massive tendon attached in *fossa intertrochanterica* of the femur.

5. *M. obturator externus* originates on the outer surface of the body of ischium and along *symphysis pubis* and round the border of *foramen obturatum*, with the exception of the cranio-lateral part of this border. The flat venter surrounds the tendon of insertion of *m. obturator internus* and inserts by means of short tendon in the trochanteric fossa.

6. *M. quadratus femoris* (Fig. 22, 23 — Qf.) is located caudally from the hip joint and covered from the back by *m. semimembranosus*. It originates near the origin of the tendinous band described together with *m. biceps femoris* (see description of this muscle) and passes into a fusiform venter with fibres running caudo-ventrally. It inserts on the *linea trochanterica caudalis*.

7. *M. gemellus* (Fig. 22, 23 — Ge.) originates on the acetabular branch of ischium along the lesser sciatic notch and on *tuber ischii*. The flat single venter terminates in a short tendon in the trochanteric fossa.

#### B. The lateral muscles of the hip

1. *M. biceps femoris* (Fig. 21, 27, 29, 30 — Gb.) is, in the E. bison as in other ruminants, fused with the caudal part of the *m. gluteus superficialis*, forming a muscle unit known under the name of *m. gluteobiceps*. The vertebral origin of this muscle extends along the spinal processes from the 2nd sacral to the 2nd coccygeal vertebra. The sciatic head is attached on the lateral tubercles of the *tuber ischii* and on the sacro-sciatic ligament in its caudal part.

The venter is distinctly divided into two parts, differing as to location and the direction in which the fibres run, which is particularly apparent in their lower ends. Above the stifle joint both parts pass into an aponeurosis making contact with the very strong *fascia cruris*. The anterior part ends on the patellar ligaments and on the tuberosity of tibia from

the lateral side. The posterior part ends with one branch below this tuberosity, and the other (after joining with the tendinous bands of the *semimembranosus* and *semitendinosus*) on the *tuber calcis*.

On the boundary between the anterior and posterior parts on the medial side of the muscle venter, a very strong tendinous band runs originating on the ventral surface of ischium. It runs from the prominence located caudo-laterally in relation to *foramen obturatum*. This band, bordering with the caudal edge of *m. adductor femoris* (see description of this muscle) as it approaches the stifle joint, becomes increasingly strong and is so directed cranially that as a result it reaches to the anterior edge of the muscle and terminates on *ligamentum rectum patellae*.

The description of *m. biceps femoris* in Poleiner's work (1932) differs slightly from our observations of this muscle. The differences are particularly evident in the description of the lower part. The tendons of insertion of both parts are, according to this author, connected and terminate jointly. According to our observations this division applies both to the muscular parts and to the tendons of insertion, certain difficulties being encountered in separating these aponeuroses in older specimens.

The joining of the tendon of *m. biceps* with *m. gastrocnemius* described by Poleiner (l.c.) has, according to us, the character of a tendinous band, strongly coalesced with *fascia cruris*, which runs under the tendon of *m. triceps surae* to *tuber calcanei*. Similar relations were found in cattle (Martin & Schauder, 1938), goats, sheep (Reiser, 1903), and *Cervus elaphus* (Reiser, l.c., Štěrbá & Hegerová, 1958).

The structure and course followed by the tendinous band situated on the inner surface of the muscle corresponds to the behaviour of this band in sheep (Martin & Schauder, 1938).

2. *M. tensor fasciae latae* (Fig. 21, 30 — Tl.) connects closely in its origin with the aponeurosis of *m. gluteus superficialis* (with the cranial part of which it coalesces) and with the deep layer of the gluteal fascia covering *m. gluteus medius* from the medial side. The osseous origin of this muscle is located on the *tuber coxae* and lateral border of the ilium.

The venter, which is triangular in cross-section, passes on the lateral side into *fascia lata*, and on the medial side of the thigh into *fascia femoralis*.

The division, visible in cattle, of this muscle into an anterior and posterior part (corresponding to the cranial part of *m. gluteus superficialis*), was not found by us in the E. bison which we dissected. The complete fusion of these muscle units corresponds to the relations in small domestic ruminants (Reiser, 1903).

3. *M. gluteus medius* (Fig. 21, 22, 29, 30 — Gm.) is covered in its caudal part by *m. gluteobiceps*, and in the cranial part by the relatively thick

gluteal fascia, which fuses with its perimysium. The origin is located on *tuber coxae*, *crista ilica* and on *facies glutea* of ilium, above the insertion of *m. gluteus accessorius*. In addition it also attaches on *pars sacrospinalis* of the sacro-sciatic ligament. The venter of this muscle coalesces closely with *m. piriformis* forming its dorso-caudal margin. The clearly visible tendinous inscription separates the two muscles and terminates on the apex of *trochanter major*. The difference is also visible in the difference in the direction in which the fibres of both bellies run. The belly corresponding to the true *m. gluteus medius* terminates on the lateral surface of *trochanter major*.

4. *M. piriformis* (Fig. 22 — Pi.) originates on the *facies glutea* of ilium, and surrounds *trochanter major* with a flat venter, inserting on the caudal border of *trochanter major* and below.

5. *M. gluteus accessorius* (Fig. 23 — Ga.) is an elongated muscle originating on *tuber coxae* and *facies glutea* of the ilium between the insertions of *m. gluteus medius* and *m. gluteus profundus*. The venter, with fibres running caudo-ventrally, terminates in a strong tendon, crossing *trochanter major* laterally on the caudal border of this trochanter.

This muscle is considered by some scientists (M a r t i n & S c h a u d e r, 1938; Š t ě r b a & H e g e r o v á, 1958) as part of *m. gluteus medius* in ruminants. Both the innervation of these muscles and their close blending found in certain species argue in favour of this view. As both muscles separated distinctly from each other in the specimens we dissected, the use of the term *m. gluteus accessorius* may be considered as justified.

6. *M. gluteus profundus* (Fig. 23 — Gp.) originates on the outer surface of *spina ischiadica*, on *pars sacrospinalis* of the sacrosciatic ligament and on the shaft and lower part of the gluteal surface of the ilium. Single muscle bundles are attached in addition on the lateral border of the ilium. The flat venter consists of fibres radiating outwards and terminates in a strong, flat tendon along the border of *trochanter major*.

We did not find the insertion of *m. gluteus profundus* on the anterior surface of the proximal extremity of the femur as is the case in cattle (M a r t i n & S c h a u d e r, 1938), *Cervus elaphus* and *Capreolus capreolus* (R e i s e r, 1903).

### C. The medial muscles of the thigh

1. *M. sartorius* (Fig. 24 — Sa.) is a flat, thin muscle, one branch of which runs from the medial surface of *m. psoas major*, and the other from *crista iliopectinea*, this latter branch crossing the tendon of insertion of *m. psoas minor* from the medial side. Both branches join in a narrow venter, runn-

ing towards the foot and coalescing in its caudal border with the cranial border of *m. gracillis*. The aponeurosis of this muscle ends on *tuberositas tibiae* and below it.

2. *M. gracillis* (Fig. 24 — G.) is the most superficial muscle of the medial side of the thigh area. The broad, flat muscle originates in a flat tendon on the tendon of insertion of the *m. rectus abdominis* and along the ventral border of *symphysis pelvis*. The upper part of the venter of this muscle covers *m. adductor femoris* and *m. semimembranosus*, partly coalescing with it. It also fuses along the medial line with the venter of this same muscle from the opposite side. The anterior border touches the caudal border of *m. sartorius* and is connected with it by means of the medial femoral fascia. The cross-section of the venter increases gradually from the caudal border cranially, interchanging fibres near the thickest part with *m. pectineus* lying beneath it.

At the level of the lower  $\frac{1}{4}$  of the femur, the venter of *m. gracillis* passes into an aponeurosis, closely connecting with *fascia cruris* and terminating: a) by means of the aponeurosis of *m. sartorius* (with which aponeurosis it closely blends) on the medial epicondyle of the femur, b) on the medial condyle of the tibia and below it, c) blending with the *fascia cruris* described previously, which is very thick, on the tibial tuberosity and below it, d) by means of a tendinous band running from the caudal, thin border of this muscle on to *tuber calcis*. This band soon after leaving connects with a similar one running from *m. semimembranosus*.

Poleiner (1932) in describing the aponeurosis of insertion of *m. gracillis*, limits himself to mentioning its common insertion with *m. sartorius*, only adding that the aponeurosis passes into *fascia cruris*. As during dissection we succeeded in accurately tracing the insertions by means of this fascia, it has been taken into consideration in describing the muscle. In supplementing Poleiner's description emphasis is also laid on the presence of the tendinous band which is attached on *tuber calcis* and which was clearly visible in all the E. bison we dissected.

3. *M. pectineus* (Fig. 24 — P.), originates on the symphyseal branch of the pubis and partly on the cranial part of origin of *m. gracillis*, which it strongly blends. The relatively short, round venter in the upper  $\frac{1}{3}$  of the femur passes into an aponeurosis covering the tendon of *m. adductor femoris* from the cranio-medial side and terminating along the caudo-lateral border of the femur, as far as the margin of *fossa flexoria* from the lateral side.

*M. adductor femoris* was described jointly with *m. semimembranosus* (see description of this muscle).



#### D. The anterior muscles of the thigh

1. *M. quadriceps femoris* — the strong extensor of the knee joint, consists of four heads as it does in cattle.

a) *M. vastus lateralis* (Fig. 21, 22, 23, 24, 26, 29 — VL.) is a strongly developed muscle lying cranio-laterally in relation to the femur. It takes origin in a strong, flat tendon on the caudal and dorsal edge of *trochanter major* (the most superficially located of all those attached here). The venter, with fibres running cranio-ventrally, forms a hollow on the medial surface for *m. rectus femoris* and *m. vastus intermedius*. Above the stifle joint the venter passes into an aponeurosis attached on *ligamentum rectum patellae* and on the patella.

b) *M. vastus intermedius* exhibits a certain tendency to division in connection with the different origin. The fibres originating below *trochanter major* form a narrow flat venter with fibres running towards the foot, located laterally in relation to the bone. At the level of the lower  $\frac{1}{4}$  of the femur the venter passes on the dorsal side of the bone and joins with the second part of the muscle, which takes origin on the rough crest extending cranially between *trochanter major* and *caput femoris*. Both parts pass into a common tendon, terminating under the tendon of *m. vastus lateralis*.

c) *M. rectus femoris* (Fig. 23, 24, 26 — Rt.) is a strongly developed round muscle originating on the shaft of the ilium. It runs on the dorsal side of the femur and terminates on the patella.

d) *M. vastus medialis* (Fig. 24 — Vm.) is a flat muscle taking origin on the cranio-medial surface of the proximal extremity of the femur. It terminates, together with the remaining parts of *m. quadriceps* on patella and *ligamentum rectum patellae*.

The description given above of *m. quadriceps femoris* in the E. bison agrees in principle with that given by Poleiner (l.c.). He was unable to take the insertion of origin of *m. rectus femoris* into consideration, as he had only the limb without the pelvis at his disposal. The description as a whole corresponds to the relations found in cattle.

#### E. The posterior muscles of the thigh

1. *M. semitendinosus* (Fig. 21, 22, 29, 30 — Sn.) originates by means of an imperceptible tendon on the body of the ischium and on *tuber ischii*. The triangular muscle venter thrusts between *m. semimembranosus* and *m. biceps femoris*. This muscle passes towards the foot on to the medial side of the femur and at the level of the lower  $\frac{1}{4}$  of this bone forms an aponeurosis connecting with *fascia cruris* and terminating on *tuberositas*

*tibiae* and on *crista tibiae* from the medial side. From the caudal border of this muscle a tendon runs which is inserted on the *tuber calcis* — *teania calcanea*<sup>4</sup>).

Poleiner (1932) in describing the insertion of this muscle indicates the presence of the thin tendinous bands running from its caudal border, which halfway along the tibia connect with the tendon of *m. flexor digitalis pedis superficialis*. These fibres were described by us as *teania calcanea*, especially as in the majority of the cases they reached to the *tuber calcis* independently. The presence of the *teania calcanea* in *m. semitendinosus* in ruminants was established in sheep (Martin & Schuder, 1938) and among wild ruminants in *Cervus elaphus* (Reiser, 1903). Štěrba & Hegerová (1958), in describing this muscle in *Cervus elaphus*, state that "The thin tendinous branches connect with the tendon of Achilles", which differs slightly, it is true, from Reiser's opinion (l.c.) but may be confirmation of the existence of *teania calcanea* in this mammal.

2. *M. semimembranosus* (Fig. 21, 22, 23 — Sb.) in the European bison which we dissected blends completely, or occasionally only partly, with *m. adductor femoris*. They form a large, flat muscle located under *m. gracillis*, partly blending with it.

The caudal part corresponding to the true *m. semimembranosus* takes origin on *tuber ischii*, on the body of the ischium and on the *symphysis pelvis*. Thick in its cross-section, the triangular upper part of the venter of this muscle thrusts between *m. semitendinosus* and *m. gracillis*, next becoming flat and at the level of the lower  $\frac{1}{3}$  of the femur passing into an aponeurosis, which is attached on the medial condyles of the femur and tibia and on *ligamentum collaterale mediale* of the stifle joint. The tendinous band passing from the lower  $\frac{1}{3}$  of the caudal border of this muscle terminates on *tuber calcis*.

3. *M. adductor femoris* — separates from *m. semimembranosus* only in two of the six individuals which we dissected and only in the lower section. It takes origin on *symphysis pelvis* and partly on the acetabular branches of the pubis and ischium. The relatively thick venter terminates in a broad aponeurosis on the lower  $\frac{2}{3}$  of the *labium mediale* of the femur.

The tendinous band of *biceps femoris* (see description of *m. biceps femoris*) contacts the cranial border of this muscle.

Poleiner did not find, in the limb of the E. bison which he dissected, the adhesion between *m. adductor femoris* and *m. semimembranosus*. In describing in great detail the first of them, he gives in conclusion

<sup>4</sup>) Term introduced by R. Poplewski (1939).

a description not differing in principle from the description given above. In *m. semimembranosus* the above author does not distinguish *teania calcanea*, which we most undoubtedly did find.

The presence of the *teania calcanea* of *m. semimembranosus* has been established in small domestic ruminants (G r a u, cit. acc. to M a r t i n, & S c h a u d e r, 1938). The adhesion between the above muscle occurs in cattle, sheep and goats.

#### F. The muscles of the leg and foot

##### a. Dorso-lateral group

1. *M. tibialis anterior* (Fig. 22, 23, 24, 25, 26, 27 — Tb.) takes origin on the lateral surface of *tuberositas tibiae* and *crista tibiae* and on *condylus lateralis tibiae*. The flat venter, partly covered from the side by *m. fibularis tertius*, passes into a thin tendon located at the level of the hock joint under the tendon of *m. fibularis tertius* and terminating on the medial side of the proximal extremity of metatarsus.

P o l e i n e r (1932) also noted the lack of division of the origin of *m. tibialis anterior* into two heads. In cattle two heads occur, which initially maintain their autonomy, and blend halfway along the venter. The caudal head corresponds to *m. extensor hallucis longus*. The indivisible muscle venter of *m. tibialis anterior* is typical of small domestic ruminants. (R e i s e r, 1903) and of *Cervus elaphus* (Š t ě r b a & H e g e r o v á, 1958).

2. *M. fibularis tertius* (Fig. 22, 23, 25, 27, 29, 30 — Ft.) takes origin together with *extensor digitalis pedis longus* lying beneath it, with which, particularly in the upper section, it mixes numerous fibres. The large venter passes above the distal extremity of the tibia into a tendon covering the tendon of *m. tibialis anterior*. This tendon is inserted by means of a series of fibres on the calcaneus, II and III tarsal bone and on the medial side of the metatarsus.

The description given above of the course taken by *m. fibularis tertius* and its insertions in the E. bison corresponds to the one given by P o l e i n e r and is in accordance with the relations found in cattle.

3. *M. fibularis longus* (Fig. 26, 27, 29, 30 — Fi.). The flat, triangular venter of this muscle takes origin on the lateral femore-tibial ligament of the stifle joint and on the lateral condyle of the tibia, partly covering *m. fibularis tertius*. At the level of the upper  $\frac{1}{3}$  of the tibia the venter greatly narrows, passing into a thin tendon running superficially in the direction of the hock joint between *m. fibularis tertius* and *m. extensor digiti quarti proprius*. Above the tarsus the above-mentioned tendon passes more to the lateral side together with the tendon of *m. extensor digiti quarti proprius*, crossing it from the front and entering into the

canal bordered by *os centotarsale* and metatarsus. In this canal it runs along the medial side and terminates on the lateral surface of *os tarsale primum*.

The origin, described by Poleiner, on *tuberculum ligamentosum laterale* of the femur, instead of the insertion given by us on the lateral femoro-tibial ligament of the stifle joint, would seem to form a matter for discussion.

In view of the abundant material we had at our disposal, our observations should be considered as being more objective.

Regardless of whether the origin on the femur takes place directly on *tuberculum ligamentosum* of this bone (Poleiner) or by means of the lateral ligament (our observations) the presence of this insertion renders the behaviour of this muscle similar to that described in sheep (Reiser, 1903). In cattle this muscle takes origin on the tibial bone.

4. *M. extensor digitalis pedis longus* (Fig. 25, 26, 27 — El.) takes origin on the lateral condyle together with *m. fibularis tertius*. The venter of this muscle divides at the level of the upper  $\frac{1}{4}$  of the tibia into two heads, the deeper of which is called *m. extensor digiti terti proprius* and as such will be described later. The superficial head halfway along the tibia passes into a tendon running towards the digits, and at the level of the upper  $\frac{1}{4}$  of the metatarsus blends with the venter and next with the tendon of *m. extensor digitalis pedis brevis* (Fig. 25, 26, 27 — Eb.) which runs at the level of the tibial tarsal bone from the dorsal surface of the tarsus. The tendon of *m. extensor digitalis pedis longus* bifurcates immediately above the metatarso-phalangeal joint into branches running to the third phalanges of the third and fourth digits.

The description given above of this muscle in E. bison agrees with the description given by Poleiner and corresponds to the relations described in cattle.

5. *M. extensor digiti tertii proprius* (Fig. 25, 26, 27 — Et') takes origin jointly with *m. extensor digitalis pedis longus*, the initial sections of the bellies of both muscle closely blending with each other. Certain authors describe them as two heads of one muscle. The venter of *m. extensor digiti terti proprius* is located below the venter of *m. extensor digitalis pedis longus* and above the tarsus passes into a tendon, which in this region runs between the tendon of insertion of *m. fibularis tertius* and *m. extensor digitalis pedis longus* and above the metatarsus medially in relation to the latter. It terminates on the second phalange of the third digit, receiving above the metatarso-phalangeal joint reinforcement in the form of the branch of the deep part of *m. interosseus medius* in a similar way to that in the corresponding thoracic limb.

6. *M. extensor digiti quarti proprius* (Fig. 26, 27, 29, 30 — Eq'), takes origin on the lateral femoro-tibial ligament, on the lateral condyle and *proc. fibularis* of tibia and on the lateral border of this bone, along  $\frac{3}{4}$  of its length. The fusiform venter above the hock joint passes into a tendon crossed from the side by the tendon of *m. fibularis longus*. Above the metatarsus it runs along its dorso-lateral side, joining, in the majority of cases, with the venter of *m. extensor digitalis pedis brevis* and terminating on the dorso-lateral side of the second phalanx of the fourth digit. Above the metatarso-phalangeal joint it is reinforced by branches of the deep part of *m. interosseus medius*, like the corresponding extensor in the thoracic limb.

Poleiner (1932) does not distinguish the origin of this muscle on the fibular process of the tibia. This insertion was found by us in all the E. bison we dissected. The presence of this insertion was noted in sheep, while in cattle it was absent (Martin & Schauder, 1938).

#### b. Plantar group

1. *M. triceps surae* falls into two muscular units:

a) *m. gastrocnemius* in the E. bison is strongly developed and consists of two heads.

*Caput mediale* (Fig. 23, 24, 25, 28 — Gs') takes origin near the distal end of labium mediale of the femur and on the medial condyle of this bone above *fossa ligamentosa*. In addition a strong tendinous band running from the medial condyle of the tibia also radiates into the venter of this head.

*Caput laterale* (Fig. 22, 23, 26, 28 — Gs.) takes origin on the lateral border of the shaft of the femur at the level of *fossa plantaris*, then passes into a strong venter.

Both the above heads blend together below the passage between them of the tibial nerve, and envelop the superficial digital flexor from the sides and back. At the level of the distal  $\frac{1}{3}$  of the tibia the bellies of both heads pass into three tendons (Fig. 28 — a, b, c,) of which the middle is the strongest and common to both heads. In addition the medial head has its own tendon, initially located on the medial side, then the caudal side and finally passing on to the lateral side of the common tendon.

The lateral head has a similar tendon, considerably stronger and distinctly separating. Above *tuber calcis* all three tendons join and insert on this tuber below the tendon of the superficial digital flexor.

In very young individuals the tendon of the medial head cannot be clearly separated from the middle tendon. In older specimens (in our material specimens over 6 months) this tendon is clearly separated,

Poleiner, in describing the tendons of insertion of both heads of the *m. gastrocnemius* in the E. bison, found that they are joined. This "junction" on account of the direction in which the fibres run, the close blending with the bellies of both heads and also the possibility of dissecting it from the two remaining tendons of insertion, has been described by us as a separate, middle tendon of insertion of the *gastrocnemius* common to both its heads.

b) *m. soleus* (Fig. 22, 23, 26 — Sf.) is a weakly formed muscle running from the lateral condyle of tibia and blending with the tendon of origin of *m. extensor digiti quarti proprius*. The very thin, flat venter joins the lateral head of *m. gastrocnemius* by its tendon.

We did not find the tendinous band, described by Poleiner, which according to this author was supposed to correspond to *tendo solei*, in any of the specimens we dissected.

2. *M. flexor digitorum pedis superficialis* (Fig. 23, 25, 26, 28 — Fsc.) takes origin in a short but thick tendon of origin in *fossa flexoria* of the femur. A strong tendinous venter blends on its caudal border with the heads of *m. gastrocnemius*. In the distal  $\frac{1}{3}$  of the tibia this venter passes into a tendon located initially under, then laterally, and finally above the tendons of *m. triceps surae*. This tendon from above and from the sides envelops *tuber calcis*, inserts on it, and then runs towards the digits, being located superficially on the plantar surface of the foot. Above the metatarso-phalangeal joint this tendon divides into two branches, both of which connect with the corresponding branches of the superficial part of *m. interosseus medius*. Halfway along the first phalanx each of the branches of the tendon of the superficial digital flexor again divides into two, thus admitting into this bifurcation the corresponding branch of the tendon of the deep digital flexor and inserting on the proximal extremity of the second phalanx on plantar side.

The description given above agrees with the description of this muscle in the E. bison given by Poleiner, and does not in principle differ from the description of this muscle in cattle.

3. *M. flexor digitalis pedis profundus* (Fig. 25, 26, 29, 30 — Fpc.) is a group of flexor muscles terminated by a common tendon. These are:

a) *M. flexor hallucis longus* (Fig. 23, 25, 26 — Fh.) takes origin on the caudo-lateral side of the lateral condyle of the tibia and on the fascial septum lying between it and *m. extensor digiti quarti proprius*. The muscle venter above the tarsus passes into the tendon running from the muscle groove above *sustentaculum tali*. Below the hock joint this tendon joins with the tendon of *m. tibialis posterior*.

b) *M. tibialis posterior* (Fig. 25 — Tp.) takes origin on the lateral condyle of the tibia near the popliteal notch and on the muscular lines of this bone,

The flat, thin venter blends in the proximal section with the venter of the previous muscle and halfway along the tibia passes into a tendon, to which the tendon of the *m. flexor digitalis pedis longus* is joined below the tarsus.

c) *M. flexor digitalis pedis longus* (Fig. 25 — Fl.) takes origin on the lateral condyle and fibular process of the tibia. The muscle-venter halfway along the tibia passes into a flat tendon, running on the caudo-medial side of the tibia in the groove on *m. flexor hallucis longus*, and later in a similar groove on the tibial bone. This tendon continues on the medial side of the hock joint and joins with the tendon of the two remaining heads below the fibular tarsal bone.

The tendon of insertion common to the three above-mentioned muscles runs towards the digits along *m. interosseus* under the tendon of the superficial digital flexor. Above the metatarso-phalangeal joint this tendon is surrounded by a sheath formed by branches of the superficial part of *m. interosseus medius*. It divides into two branches terminating on the third phalanges of the third and fourth digits.

The description of this muscle in the *E. bison* agrees with that of the same muscle in cattle.

4. *M. popliteus* (Fig. 22, 23, 25 — Po.) takes origin on the lateral condyle of the femur in a strong tendon, thrusting under the lateral femoro-tibial ligament of the stifle joint. The muscle venter, initially rounded, covers *capsula articularis* from the back and then becomes flat, inserting fanwise in the medial border of the tibia.

This muscle behaves similarly in *E. bison* to that in cattle.

#### c. Muscles of metatarsus

1. *M. interosseus medius* is located on the plantar surface of the metatarsus and consists of two parts: the deep and superficial, the further division and course of which correspond to the relations present in the thoracic limb.

2. *M. extensor digitalis pedis brevis* (Fig. 25, 26, 27 — Eb.) originates in the European bison on the dorsal ligaments of the hock joint. The flat muscle venter, situated between the tendons of *m. extensor digiti quarti proprius* and *m. extensor digitalis pedis longus*, joins the latter at the level of the proximal  $\frac{1}{3}$  of the metatarsus.

#### IV. DISCUSSION AND RESULTS

The results given of our observations of the skeletal muscular system of the European bison indicate the existence of specific features in the formation of many muscle units compared with the corresponding muscles

in domestic cattle. This refers here both to features of structure and to the topography of individual muscles of different regions of the body of the E. bison.

Among the muscles of the head of the E. bison the following are worthy of note: the degree of development of the cutaneous muscle system and the differences in details of structure of such muscles as *m. temporalis* and *m. biventer*. The stronger development of the cutaneous muscle system in the E. bison is connected with the considerable thickness of the skin. This connection was emphasized in greater detail by Świeżyński & Pilar ski (1956).

Differences in the structure of the mandibular muscles result in the greater extent of the insertions of *m. temporalis* and *m. biventer mandibulae*. The degree of formation of *m. temporalis* in ruminants is, according to Borowiec (1950) dependent on the participation of the incisor teeth in the process of taking in food. The function of the venter anterior of the *m. biventer* is chiefly to depress the mandible. Consideration of these observations leads to the conclusion that the incisors play a greater part in the mechanics of taking in food in the E. bison than in domestic cattle. This is confirmed by observations of the biology of this species. Hard shoots and the bark of trees form a large part of the food of the E. bison, and to bite these off requires strong pressure of the incisors and wider opening of the mouth.

The appearance of a live E. bison is in itself sufficient to rouse interest in the structure of the muscles of the withers (*regio dorso-scapularis*) in that they participate in the formation of the characteristic "hump" of the European bison. This "hump" is the result on the one hand of the unusually high spinous processes of the thoracic vertebrae, and on the other of the strongly developed muscles of this region which contribute to its formation. The muscles involved in this formation are primarily *pars cervicalis muscoli rhomboidei*, *m. splenius*, *m. semispinalis capitis* and *m. spinalis cervicis*.

The explanation that the greatly developed *m. splenius* and *m. semispinalis capitis* are due to the effect of the considerable weight of the head of this animal does not seem convincing, despite the fact that the opinions of certain authors are unanimous in this respect and suggest the interdependence between the weight of the head and the degree of development of the spinous processes of the muscles of the withers region. This view is refuted both by the results of Krysiak's investigations (1951) and those of Roskosz & Empel (1960). The occurrence of massive muscle units intended solely for a function so little dynamic as supporting the head, with the simultaneous existence for this purpose of an "economical" construction in the form of *ligamentum nuchae* would be unjustified



"prodigality" in Nature. These muscles, in addition to the function of lifting the head, particularly important to the males during fights (hence probably, their specially strong development in the representatives of this sex) act on one side only and bend the spine in their direction. The living conditions of the E. bison, combined with the great mass of their bodies, make it essential for this mammal to be very agile, which is connected, *inter alia*, with the "elasticity" in the lateral movements of its spine, especially in the cervical region. This requirement is met by the strong development of the muscles referred to above. Confirmation of these suppositions is provided by the structure of certain muscles of the epaxial group. *M. iliocostalis* and *m. longissimus dorsi*, limited in the majority of E. bison to the lumbo-thoracic section of the spine, do not reach the cervical vertebrae, as is the case in domestic cattle. *M. semispinalis capitis* and *m. spinalis cervicis* are strongly developed in the E. bison and clearly separated from *m. semispinalis et spinalis dorsi*. Such "autonomy" in the extent to which the different sections of the spine are capable of movement is of great assistance to the E. bison under its living conditions.

The importance of *m. rhomboideus* in the mechanics of walking in these animals has not been specially emphasised, despite the fact that it fully deserves attention. The cervical part of the *rhomboideus*, during the free phase of the thoracic limb, contracts the cartilage and anterior angle of the scapula, thus drawing the shoulder joint backwards. P o p l e w s k i (1937) in his investigations of the mechanics of walking, considers the shoulder joint as the chief centre of movement in this phase, and the group formed by *biceps brachialis* and *m. brachiocephalicus* as the generators of this movement. He considers that the cause of the great development of *m. brachiocephalicus* in quadrupeds is the importance of this very function. All other movements take place in the remaining joints and, being the result of contractions of other muscles, possess in this sphere, according to this author, a secondary, compensatory character in relation to the action taking place in the region of the stylopodium. The question as to whether in the case of E. bison the activity of the cervical part of *rhomboideus* is of such a secondary character requires, in my opinion, further investigation. W r ó b l e w s k i, in describing the walk of the European bison writes: "... it gives the impression that the animal supports the whole weight of its body on the hind legs, testing the ground with the front ones, ready at any time to draw back. The hump, which . . . . . assists this original way of walking" <sup>5</sup>). Both W r ó b l e w s k i's observations cited above and the structure of this muscle, described in the detailed part of this work, indicate its important participation in the me-

---

<sup>5</sup>) Extract cited above translated from Polish.

chanics of walking. The function of this muscle in the support phase of the limb would seem to be of even great significance and worth investigating.

The remaining muscles of the thoracic limb in the E. bison do not exhibit special differences in comparison with the corresponding muscles in domestic cattle. The sole exceptions to this are *m. extensor carpi radialis*, and *m. abductor pollicis longus*, which in the E. bison unexpectedly inserts in the same way as in small ruminants. In the E. bison the *m. pronator teres* is absent, as it is in *Capreolus capreolus* and *Cervus elaphus*.

The muscular system of the walls of the thorax is similar to the muscular system of this region in domestic cattle — apart from the insertions of *m. transversus costarum*, which also behave similarly in the E. bison, to those in small ruminants.

Among the muscles of the abdominal walls of the E. bison, the strong development of the aponeurosis of *m. transversus abdominis* and the wide extent of *m. rectus abdominis* are noteworthy. Such structure of the above muscles, together with the very powerful fascia system, result in the abdomen of the E. bison being suspended very tautly, and even in highly pregnant females the abdomen does not hang down or become flaccid.

Among muscles of the pelvic limb which differ from the corresponding muscles in domestic cattle are *m. gluteobiceps*, *m. tensor fasciae latae*, *m. gracilis*, *m. semimembranosus*, *m. adductor femoris* and also *m. tibialis anterior*, *m. fibularis longus*, *m. extensor digiti quarti proprius*, *m. gastrocnemius*. The first five muscles form a group of units closely connected with the motor properties of the pelvic limb. The functional importance of this group is especially distinct in the support phase of the limb (with the exception of *m. tensor fasciae latae*), when the chief centre of movement is situated in the stifle joint, and the effect of contraction of *m. gluteobiceps* is manifested by the pushing forwards on its pelvico-vertebral attachments. The effect of this is to "push" the pelvis forwards, and with it the whole trunk. *M. semimembranosus* and *semitendinosus* in this phase of movement co-operate with *m. gluteo-biceps* and in cattle are bi-articular muscles (hip and stifle joints). In the E. bison, owing to the presence of *teania calcanea* of these muscles, they become tri-articular and are simultaneously extensors of the foot on account of the insertion of these bands on *tuber calcis*. Poplewski, in the work cited above, lays special emphasis on the importance of the movement of the foot in the function of the motor mechanism of the pelvic limb. He emphasises the part played in this movement of *teania calcanea* of the *biceps femoris*, and of the what he terms "tuberal flexores". In the light of these reasonings *m. semimembranosus* and *m. semitendinosus* in the E. bison

also play an auxiliary part in the movements of the foot and in this way increase the motor capacity of the pelvic limbs. A similar functional importance must be attributed to the *teania calcanea* of *m. gracillis*. *M. adductor femoris*, owing to its blending with *m. semimembranosus*, co-operates with it in the functions described above. *M. tensor fasciae latae* plays an important part in the sphere of the free limb, when the centre of movement shifts to the hip joint, and the distal extremity of the femur shifts forwards. The blending of both parts of *m. tensor fasciae latae* which occurs in the E. bison may affect its functional importance, not in the sense of the direction in which it acts, but in its dynamic capacity.

The functional consequences of the preservation in the E. bison of the *m. m. tibialis anterior*, *fibularis longus* and *extensor digiti quarti proprius* are difficult to define without making biomechanical investigation of these muscles. As stated in the introduction this was not the aim of our work. These muscles (similarly to many others mentioned above) exhibit similarity to the relations occurring in this respect in small ruminants, both domestic and wild.

## REFERENCES

1. Akajewsky, A., 1931: Zur Morphologie des *M. levator nasolabialis* und des *M. malaris* bei einigen Haustieren. Anat. Anz., 73, 1/3: 1—22. Jena.
2. Albrecht, R., 1944: Zur Anatomie des Bovidenherzens. Diss., Leipzig.
3. Bijvoet, W. F., 1908: Zur vergleichende Morfologie der *Musculus digastricus mandibulae* bei den Säugetieren. Ztschr. Morph. Antrop., 11. Berlin (acc. to Thiel).
4. Boas & Petersen, 1921: Dukkelen hos Zebuochsen. Den Kgl. Veterinair og Landbohøjskole Aarskrift. (acc. to Martin & Schauder, 1938).
5. Bochenek, S., 1955: Szczątki żubra *Bison bonasus* (L.) z Podhala. Acta theriol., 1: 15—25. Warszawa.
6. Borowiec, S., 1950: Współzależność mięśniowo-zębowa. Folia morphol., 1(9), 1: 88—120. Warszawa.
7. Chomiak, M., 1947: Mięsień policzkowy (*musculus buccinatorius*) u przeżuwaczy (krowa, owca, koza). Ann. Univ. M. Curie-Skłodowska, C2, 9: 214—233. Lublin.
8. Franck, L., 1838: Handbuch der Anatomie der Haustiere. Berlin. (acc. to Akajewsky, 1931).
9. Hampl, A. & Kaman, J., 1959: Hluboká svalovina *ni. facialis* u srnce a jelena. Čs. Morfol., 7, 2: 144—156. Brno.
10. Huber, E., 1924: Über die Bedeutung der experimentellen Methode in der Facialisforschung, nebst Betrachtungen über die phylogenetische Entwicklung der Facialismusculatur in der Vertebraten-Reihe. Anat. Anz., 58, 24: 177—205. Jena.
11. Kaman, J. & Hampl, A., 1958: Svaly krku jelena (*Cervus elaphus* L.). Sborník VŠZL, B, 6 (27), 2: 134—146. Brno.
12. Kaman, J. & Hampl, A., 1959: Povrchová svalovina *ni. facialis* u srnce (*Capreolus capreolus* L.). Sborník VŠZL, B, 7 (38), 1—3: 93—118. Brno.

13. Kolda, J., 1950: Srovnávací anatomie zvířat domácích. 3—4: 1—426, Stud. Org. Č. S. Vet.-Med., Brno.
14. Komárek, V., 1958: Některé poznámky ka svalovine hrudni končetiny jelena. Sbornik VŠZL, B, 6(27), 2: 147—159. Brno.
15. Krüger, W., 1927: *Musculus multifidus* und *Musculi rotatores* der Haussäugetiere und ihre Beziehungen zur Drehfähigkeit der Wirbelsäule. Anat. Anz., 63, 21/24: 305—327. Jena.
16. Krysiak, K., 1951: Więzadło karkowe (*Ligamentum nuchae*) żubra (*Bison bonasus* L.). Folia morphol., 2(10): 271—283. Warszawa.
17. Krysiak, K., 1960: The European Bison (*Bison bonasus*). State Counc. Conserv. Nat. Poland, 10: 1—38. Kraków.
18. Martin, P. & Schauder, W., 1938: Lehrbuch der Anatomie der Haustiere. 3: 1—560. Schickhard-Ebner, Stuttgart.
19. Maximienko, A., 1928: Zur Morphologie des *M. obliquus abdominis internus* einiger Säugetiere. Anat. Anz., 64, 18/19: 358—371. Jena.
20. Millot, J., 1945: Les bisons européens des collections du Muséum d'Histoire Naturelle. Mammalia, 9, 1: 1—19. Paris.
21. de Moulin, F., 1924: Die oberflächlichen Rücken- und Halsmuskeln des indischen Büffels und des Zebus. Anat. Anz., 58, 19/21: 460—471. Jena.
22. Mörike, K., 1954: Vergleichende-funktionelle Morphologie der Rumpf-Oberarmmuskulatur der Säugetiere und des Menschen. Gegenbaurs morph. Jb., 94, 1—2: 165—237. Leipzig.
23. Nickel, R., Schummer, A. & Seiferle, E., 1954: Lehrbuch der Anatomie der Haustiere, Bewegungsapparat., 1: 1—502. Paul Parey. Berlin—Hamburg.
24. Piękoś, M., Pilariski, W. & Roskosz, T., 1958: Obserwacje nad długością jelita u żubra (*Bison bonasus* L.). Folia morphol., 9(17), 1: 69—79. Warszawa.
25. Pilariski, W. & Roskosz, T., 1957: Zjawisko ukrzyżowania (*sacralisatio*) ostatniego kręgu lędźwiowego u samic żubra (*Bison bonasus* L.). Folia morphol., 8(16), 2: 110—119. Warszawa.
26. Pitzorno, M., 1905: *Musculus interflexorius*. Atti. Soc. Tosc. sc. nat. Pisa. Proc. verb., 14. Pisa.
27. Poleiner, R., 1932: Der anatomische Aufbau der Extremitäten beim Europäischen Wisent (*Bison bonasus* L.) in vergleich zum Hausrind. Diss. Wien.
28. Poplewski, R., 1937: Badania nad mechaniką chodu. Wiad. wet., 204: 249—278. Warszawa.
29. Poplewski, R., 1939: Anatomia ssaków. 3: 1—142. Kom. Wyd. Pol. Akad. Warszawa.
30. Reiser, E., 1903: Vergleichende Untersuchungen über Skelettmuskulatur von Hirsch, Reh, Schaf und Ziege, 1—42. Diss. Bern-Wien.
31. Roskosz, T. & Empel, W., 1961: The size of the head and the height of spinous processes in the region of the withers of the European bison, *Bison bonasus* (Linnaeus 1758). Acta theriol. 5, 6: 63—71. Białowieża.
32. Štěrba, C., 1958: Volární a plántarní krátké svaly metapodia skotu. Českoslov. Morfol., 6, 3: 252—256. Brno.
33. Štěrba, E. & Hegerová, E., 1958: Myologie pánevni končetiny jelena (*Cervus elaphus* L.). Sbornik VŠZL., B, 6(27), 2: 162—169. Brno.
34. Stimpel, J., 1934: Der Morphologie des medialen Muskelstranges der Stammzone bei den Haustieren. Morph. Jb. 74, 3: 337—363. Leipzig.
35. Świeżyński, K. & Pilariski, W., 1956: Umieśnienie skórne żubra (*Bison bonasus* L.). Folia morphol., 7(15), 2: 133—138. Warszawa.

36. Thiel, W., 1954: Der tiefe Facialmuskulatur und die Hyoidverbindung des *Musculus biventer* der Säugetiere. Gegenbaurs morph. Jb., 94, 3—4: 391—451. Leipzig.
37. Turkiewitsch, K., 1928: Zur Morphologie des *M. transversus trunci* der Säugetiere. Anat. Anz., 66, 16/18: 281—292. Jena.
38. Węgrzyn, M. & Serwátka, S., 1961: *Ligamentum sacrotuberale latum* bei *Bison bonasus* (Linnaeus 1758) und *Bos taurus* (Linnaeus 1758). Acta the-riol. 5, 7: 73—97. Białowieża.
39. Wilkus, E., 1957: Porównawczo-anatomiczne badania nad głową żubra, *Bison bonasus* (L.). I. *Cavum oris*. Acta theriol. 1, 7: 184—307. Warszawa.
40. Wróblewski, K., 1927: Żubr puszczy białowieskiej. Wyd. Polskie: 1—232. Poznań.
41. Żabiński, J., 1947—1951: Księgi Rodowodowe Żubrów. Wyd. Międzyn. Tow. Ochr. Żubra: 1—155. Warszawa.

Warsaw Agricultural University,  
Department of Animal Anatomy,  
Warsaw, Grochowska 272.

---

#### STRESZCZENIE

Piśmiennictwo z zakresu anatomii żubra nie jest bogate i dotyczy przede wszystkim szkieletu. Trudności w zdobyciu i przechowywaniu materiału w postaci tak rzadkiego a jednocześnie tak dużego obiektu badań spowodowały, że nieliczne publikacje dotyczące anatomii części miękkich tego gatunku mają w większości charakter przyczynków.

Jako materiał do badań posłużyły zwłoki 20 żubrów różnej płci i wieku, padłych w latach 1950—1960, będące w dyspozycji Ośrodka Badań nad Anatomią Żubra przy Zakładzie Anatomii Zwierząt Wydziału Weterynaryjnego S.G.G.W. w Warszawie. Preparacje anatomiczną prowadzono częściowo na materiale świeżym, głównie zaś na utrwalonym drogą nastrzykiwań dotętnicznych płynami konserwującymi lub przez przechowywanie zwłok w basenach z wodnym roztworem formaliny. Zamieszczone w pracy ryciny wykonano na podstawie fotogramów.<sup>6)</sup>

Porównanie wyników badań nad umięśnieniem szkieletowym żubra z danymi z tego zakresu u bydła domowego oraz innych przeżuwaczy domowych i dzikich, wykazało obecność szeregu różnic. Dotyczą one zarówno zewnętrznych cech morfologicznych jak i topografii jednostek mięśniowych różnych okolic ciała żubra.

Wśród mięśni głowy żubra na uwagę zasługują mięśnie skórne i szczególnie budowy takich mięśni jak *m. temporalis* i *m. biventer mandibulae*.

Specjalnie wyraźne różnice między mięśniami szkieletowymi żubra i bydła domowego zaznaczają się w okolicy grzbietowo-łopatkowej, *regio dorsoscapularis*. Dotyczy to *m. rhomboideus*, *m. splenius*, *m. semispinalis capitis*, *m. spinalis cervicis*.

W grupie mięśni nadosiowych żubra ze względu na topografię przyczepów podkreślenia wymagają takie mięśnie jak: *m. iliocostalis*, *m. longissimus dorsi*, *m. spinalis et semispinalis dorsi*.

Z mięśni kończyn, które budową swą odbiegają od stosunków występujących u bydła domowego, wymienić należy: *m. extensor carpi radialis*, *m. abductor pollicis longus*, *m. gluteobiceps*, *m. tensor fasciae latae*, *m. gracillis*, *m. semimembranosus*,

---

<sup>6)</sup> Rysunki wykonał lek. wet. Mieczysław Węgrzyn.

*m. adductor femoris, m. tibialis anterior, m. fibularis longus, m. gastrocnemius, m. extensor digiti quarti proprius* kończyny miednicznej.

Oprócz wymienionych wyżej mięśni mniej wyraźne różnice w porównaniu z umięśnieniem szkieletowym bydła wykazuje szereg innych jednostek mięśniowych żubra.

Zaobserwowane cechy umięśnienia szkieletowego żubra dają pewne podstawy do tłumaczenia ich specyficznymi warunkami bytowania tego zwierzęcia. Wyniki pracy stwarzają ponadto morfologiczne podstawy do dalszych badań tego zagadnienia pod kątem analizy biomechanicznej.

FIGURES

Plate XXX.

Fig. 1. Muscles of head of European bison (The superficial muscles are removed).

Fig. 2. Muscles of laryngeal region of European bison. *M. mylohyoideus*:

a — anterior part, a' — posterior part.



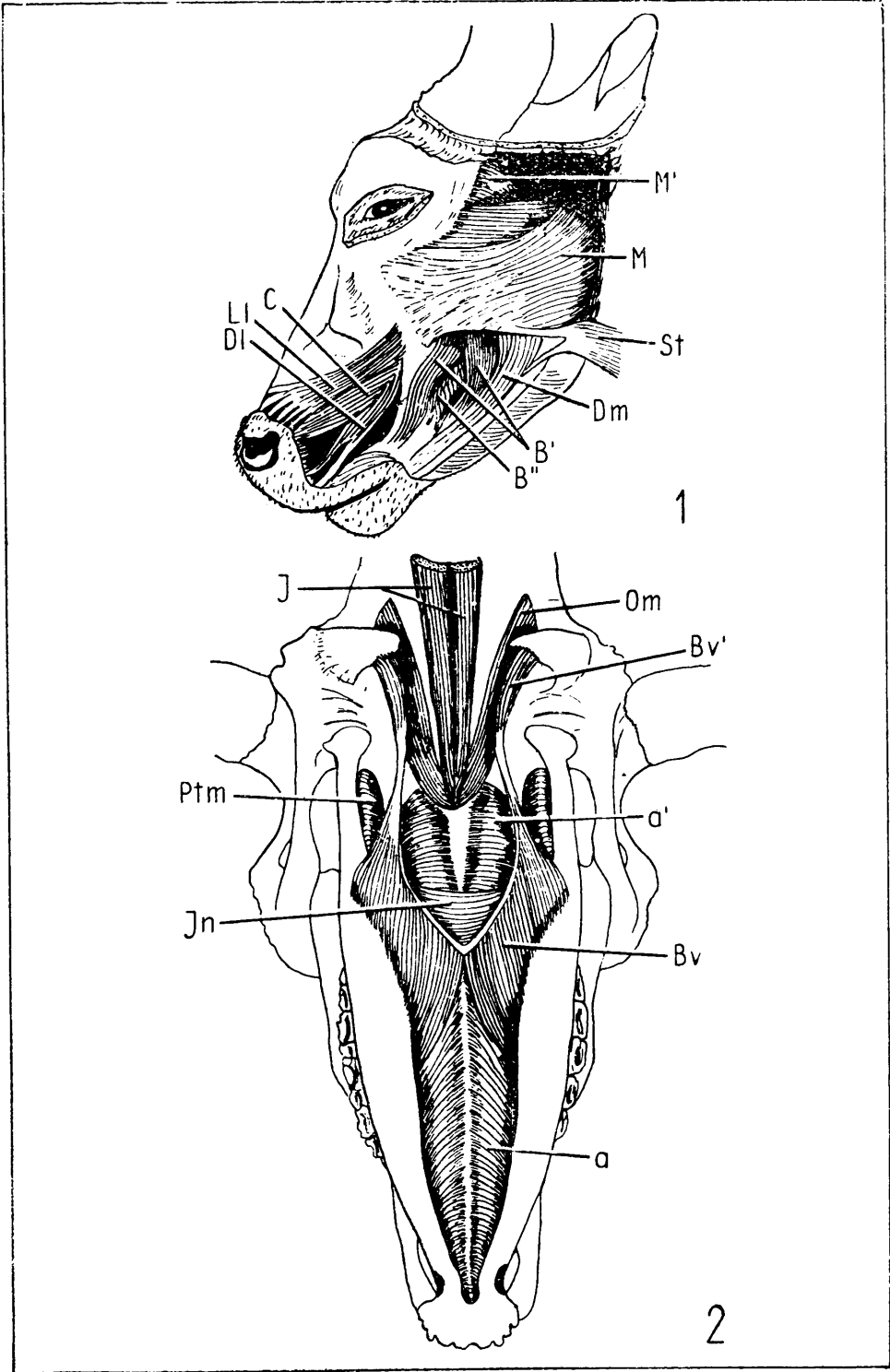
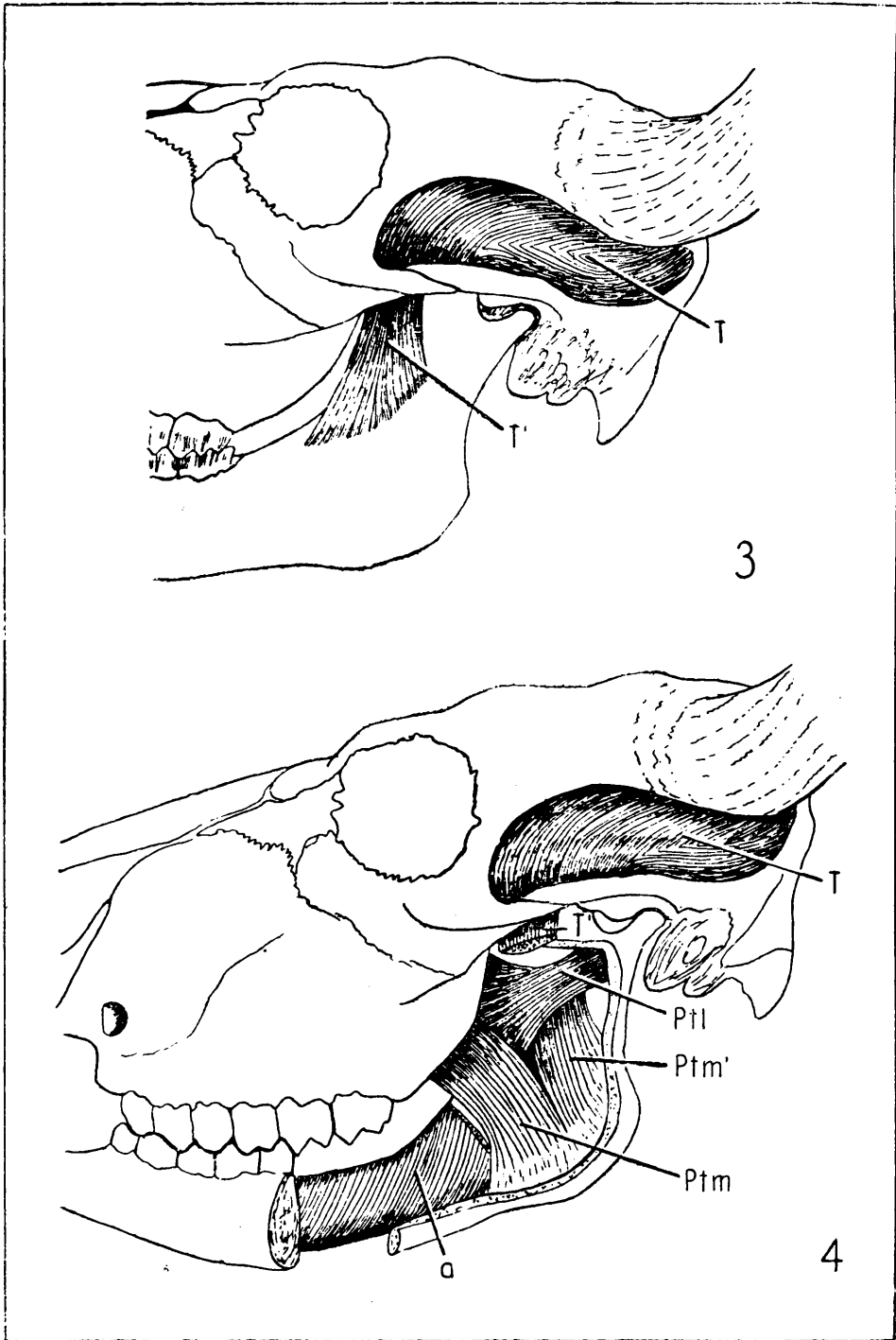


Plate XXXI.

Fig. 3. *M. temporalis* of European bison.

Fig. 4. Mandibular muscles of European bison. Deep dissection. Body and ramus of the left half of mandible are partially removed.





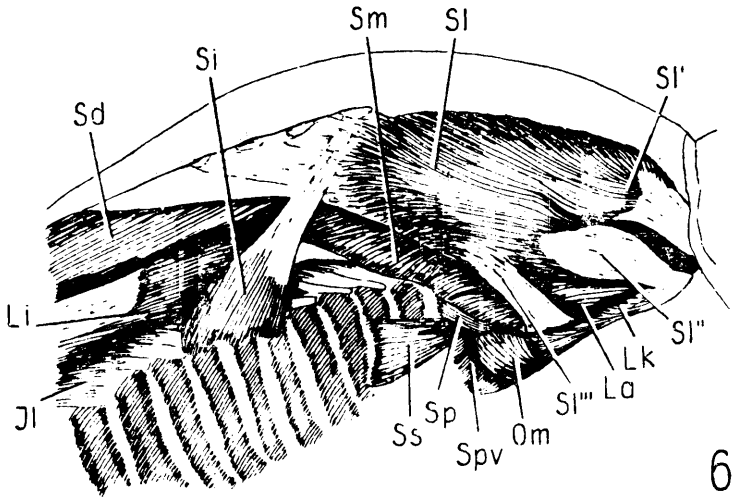
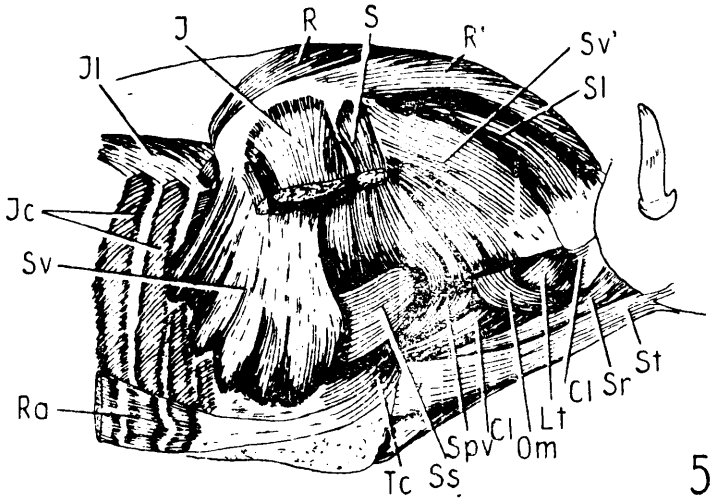


Plate XXXII.

Fig. 5. Muscles of neck and thorax of European bison, ♂. Right side. The superficial muscles and thoracic limb are removed.

Fig. 6. Topography of *M. splenius* of European bison, ♂. The preparation is viewed from the right side and somewhat dorsally.








Plate XXXIII.

Fig. 7. Muscles of the neck, back and loins of European bison, ♂. Right side.  
*M. splenius* is removed.

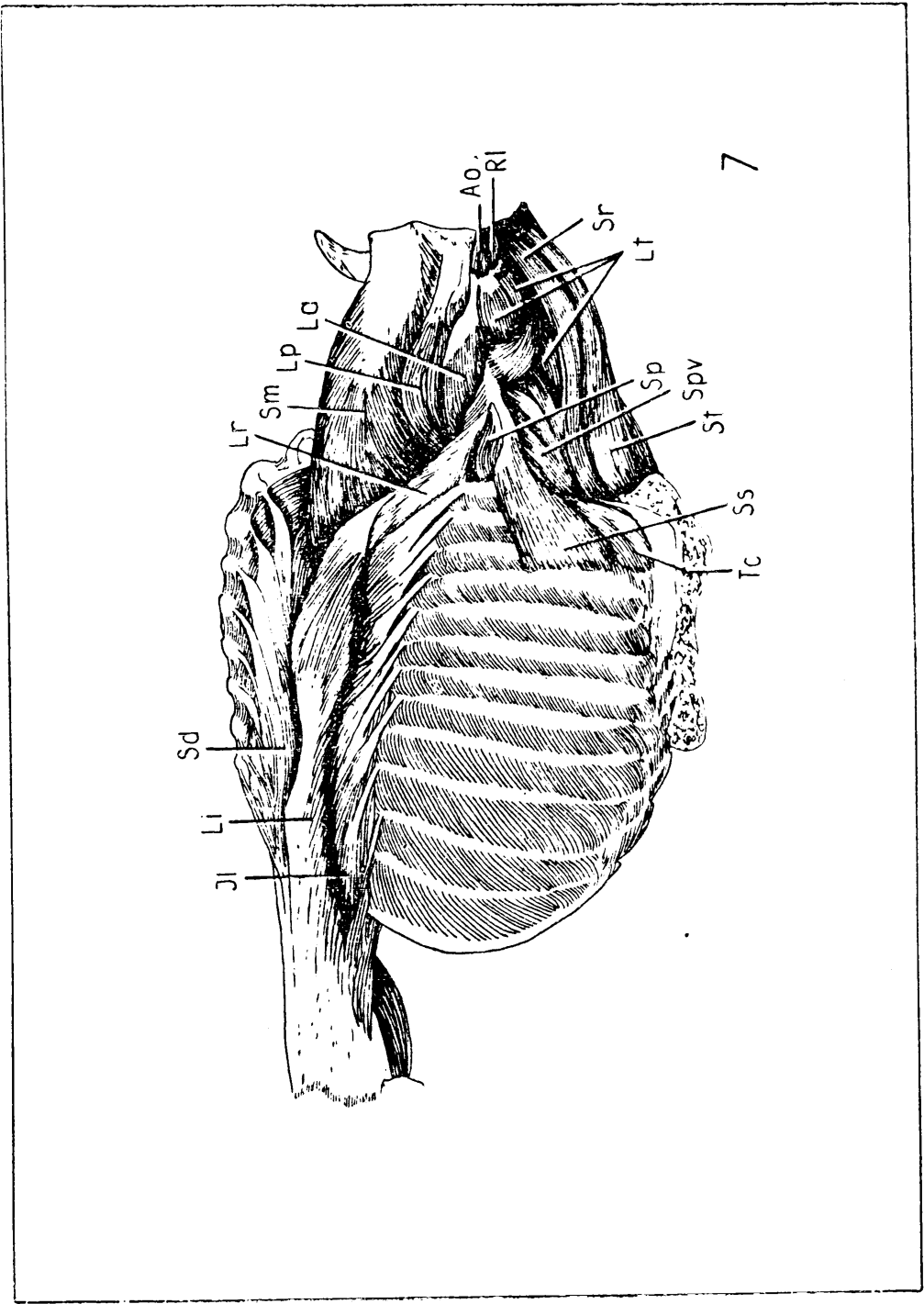


Plate XXXIV.

Fig. 8. Muscles of the neck, back and loins of European bison, ♂. Right side. *M. iliocostalis* is removed. *M. m. semispinalis capitis*, *longissimus capitis* and *longissimus atlantis* are partially removed.

Fig. 9. Muscles of the neck, back, and loins of European bison, ♂. Right side. Lateral part of *m. spinalis et semispinalis dorsi* and *m. longissimus cervicis* are entirely removed.



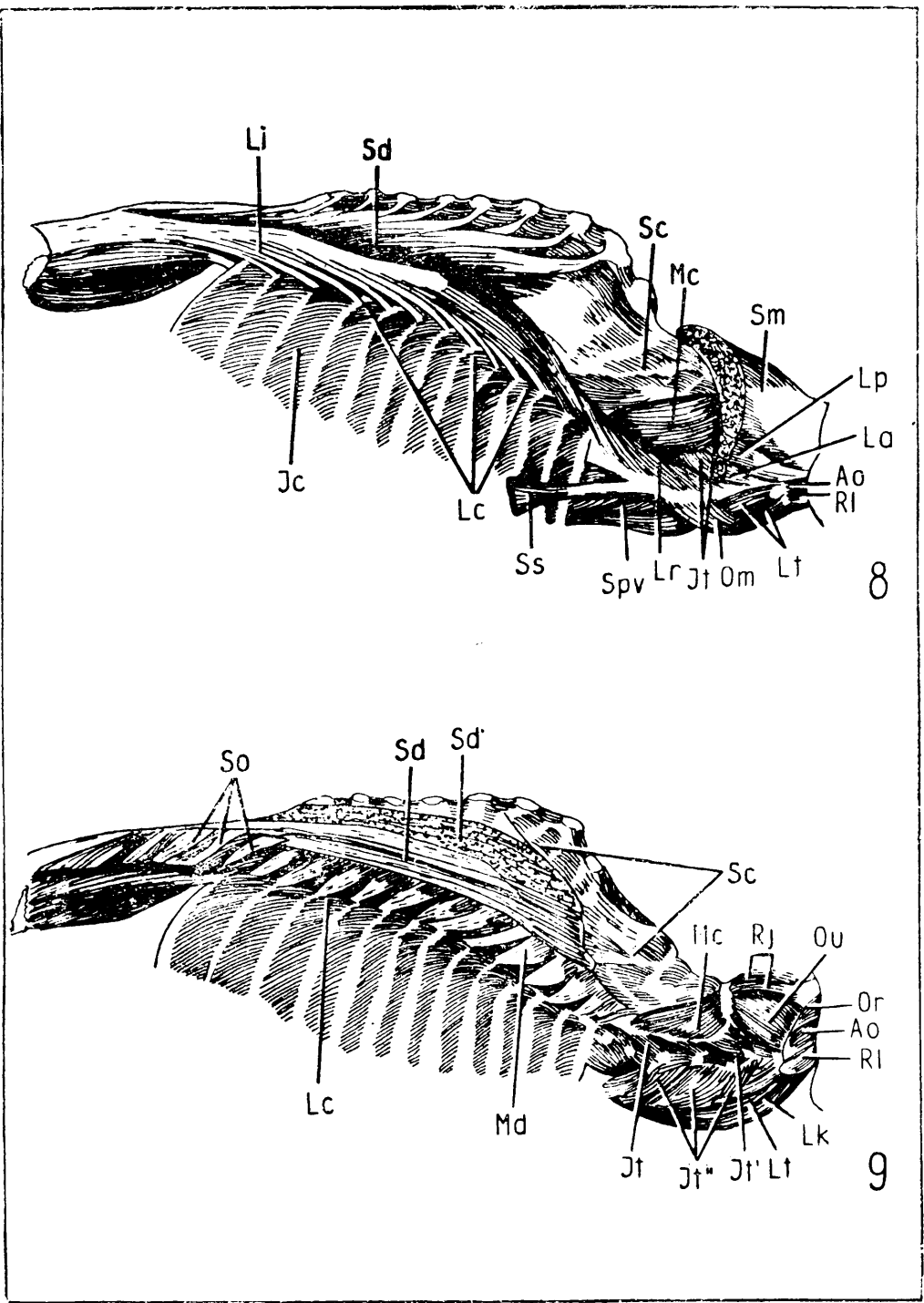


Plate XXXV.

- Fig. 10. *M. multifidus* of European bison. Right view.  
Fig. 11. *M. longus colli* of European bison. Ventral view.  
a — cervical part, b — thoracic part.

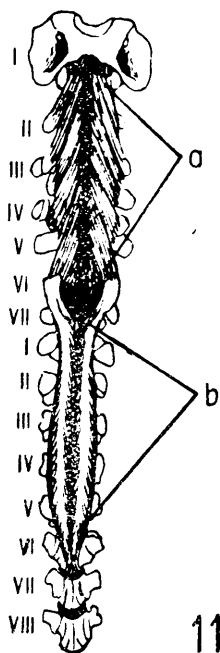
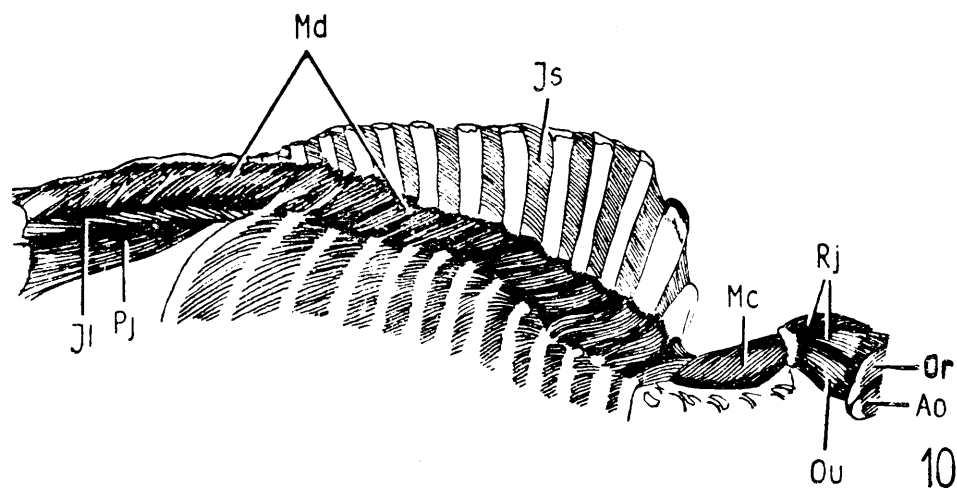


Plate XXXVI.

Fig. 12. *M. rectus abdominis* of European bison. Ventral view. Ra — lateral portion; Ra' — medial portion; 1 — placement of the xiphoid cartilage; 2 — placement of *linea alba*; 3 — placement of the attachment on the pelvis; 4,5 — fourth and fifth costal cartilages; 6 — placement of the costal arch.

Fig. 13. *M. transversus thoracis* of European bison. Dorsal view. 1 — *manubrium sterni*; b — *diaphragma* (cut).

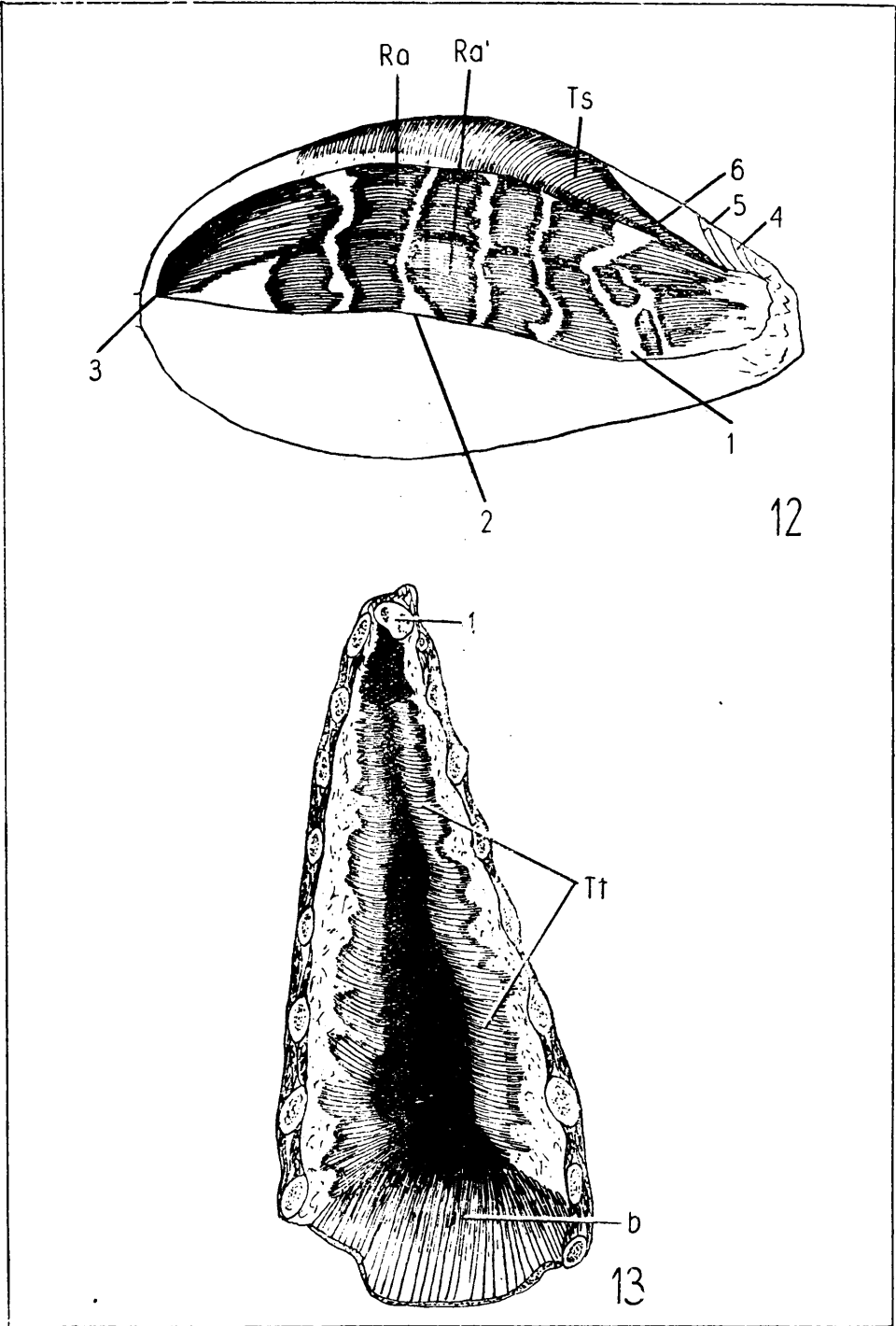
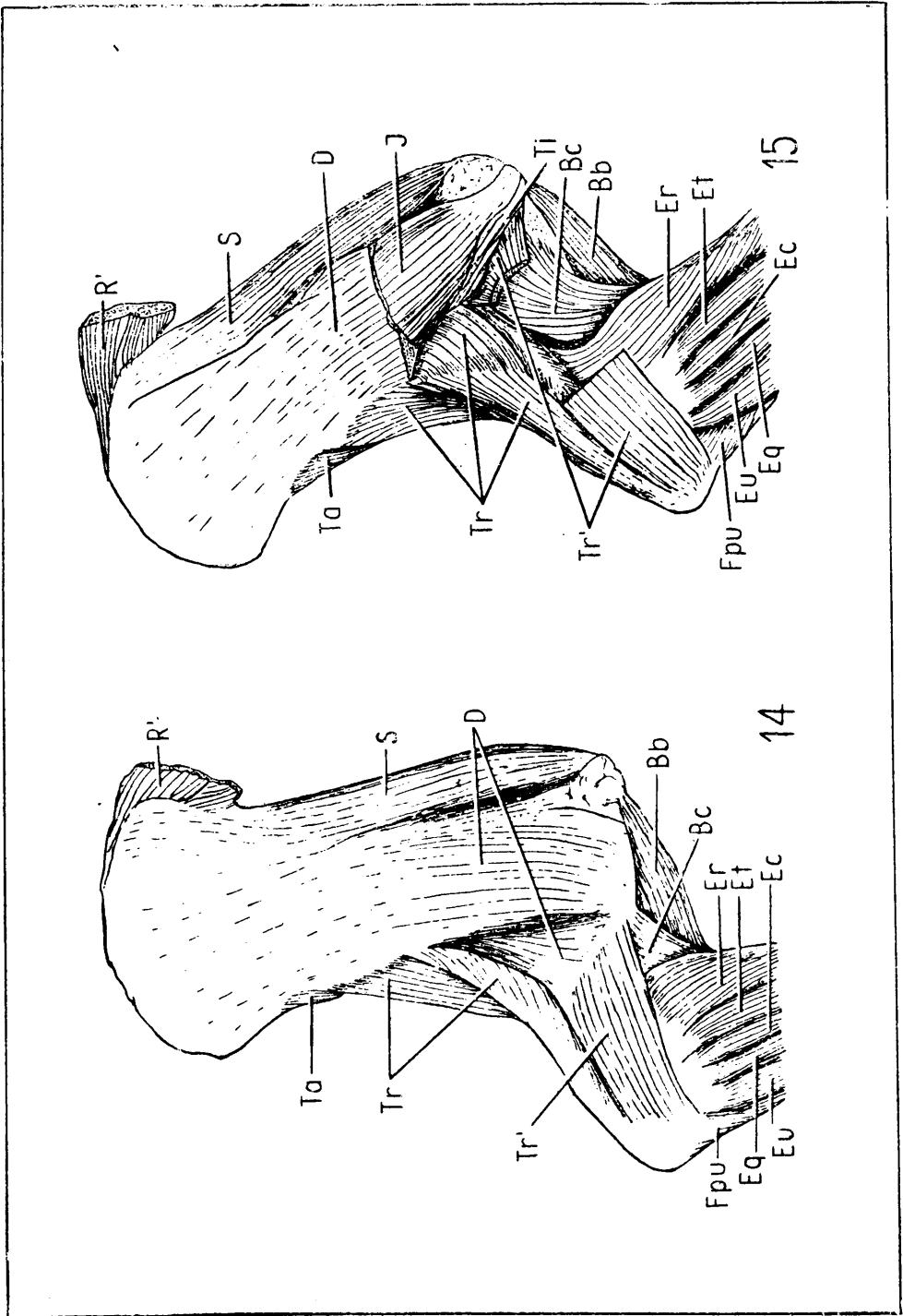


Plate XXXVII.

Fig. 14. Muscles of shoulder and arm of European bison. Lateral view.

Fig. 15. Muscles of shoulder and arm of European bison. Lateral view. *M.m. deltoideus* and *biceps brachii* are partially removed.






Plate XXXVIII.

Fig. 16. Muscles of shoulder and arm of European bison. Medial view. *M. tensor fasciae antebrachii* is partially removed.





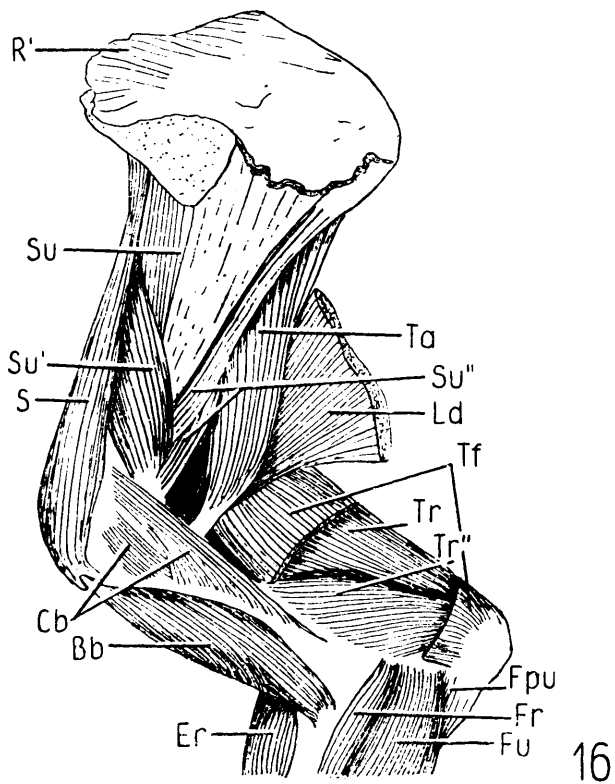


Plate XXXIX.

Fig. 17. Muscles of right thoracic limb of European bison from elbow downwards.  
Lateral view.

Fig. 18. Muscles of right thoracic limb of European bison from elbow downwards.  
Medial view.

Fig. 19. Muscles of right thoracic limb of European bison from elbow downwards.  
Volar view.

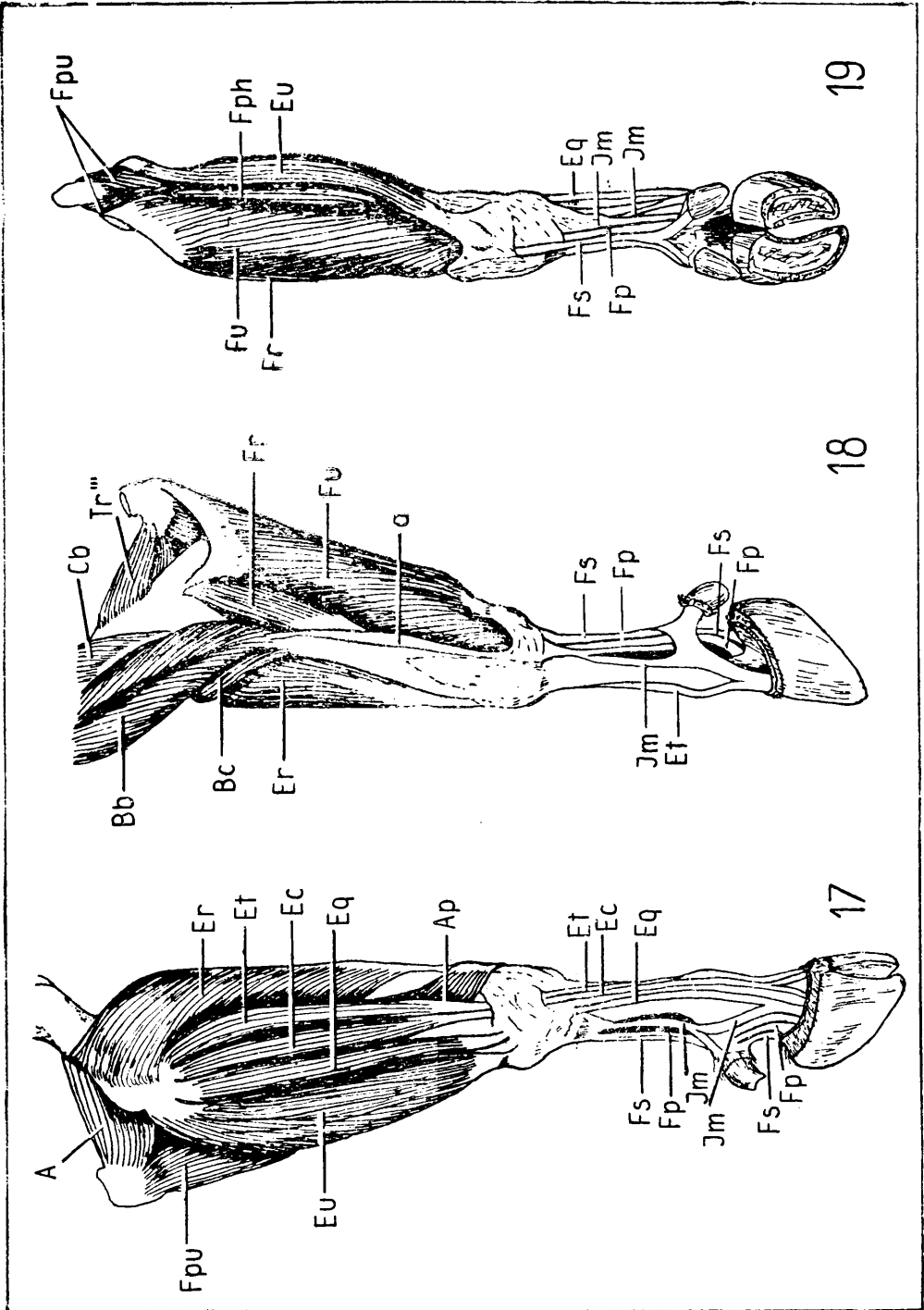


Plate XL.

Fig. 20. Muscles of antebrachium of European bison. Deep dissection, medial view. *M. flexor carpi ulnaris* is completely and *caput superficialis mi. flexoris superficialis* is partially removed. a — *m. interflexorius proximalis*; b — *m. interflexorius distalis*.

Fig. 21. Muscles of gluteal and femoral region of European bison. Left side.

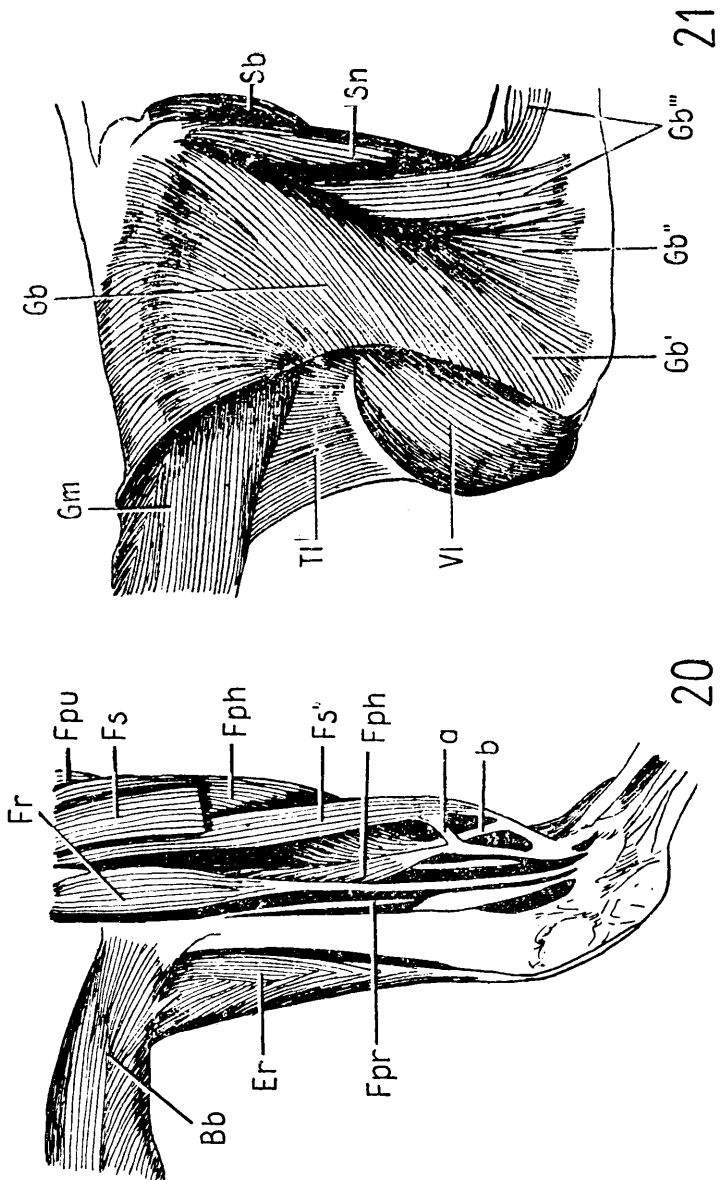
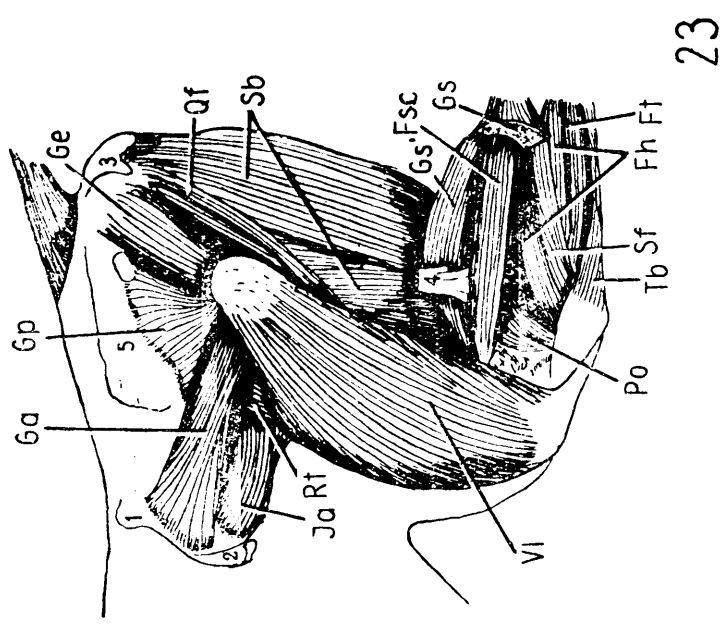


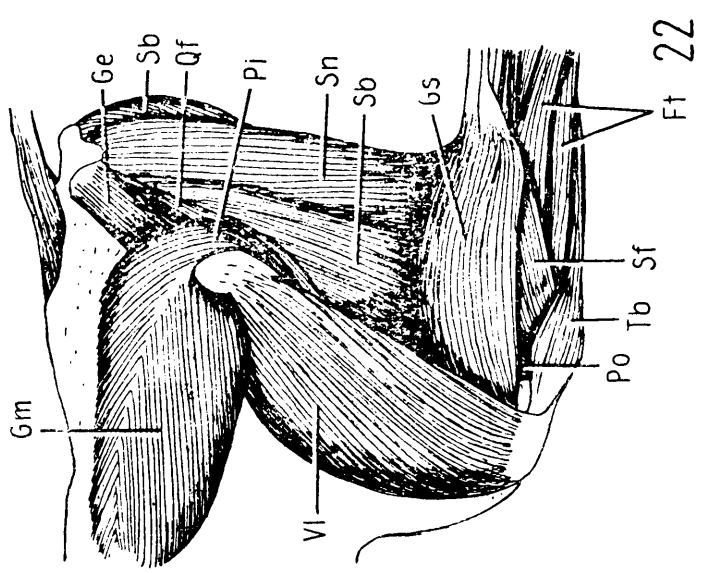
Plate XLI.

Fig. 22. Muscles of gluteal and femoral region of European bison. Left side.  
*M. gluteobiceps* is removed.

Fig. 23. Muscles of gluteal and femoral region of European bison. Deep dissection.  
1 — *tuber sacrale*; 2 — *tuber coxae*; 3 — *tuber ischii*, 4 — *N. tibialis*.



23

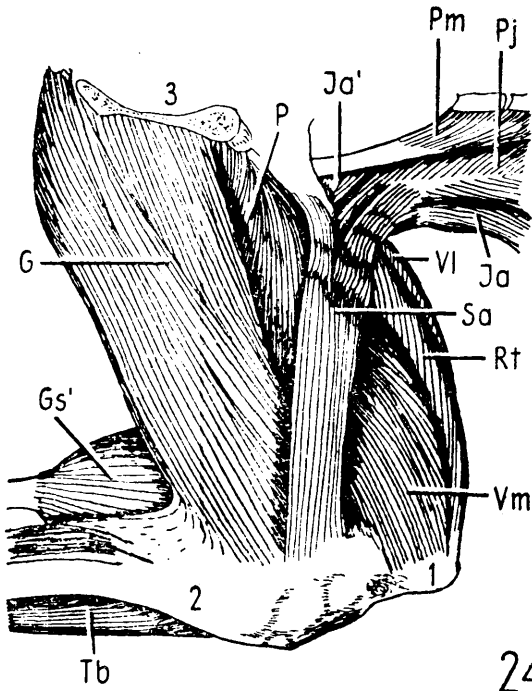


22

Plate XLII.

Fig. 24. Muscles of pelvis and thigh of European bison. Left side, medial view.



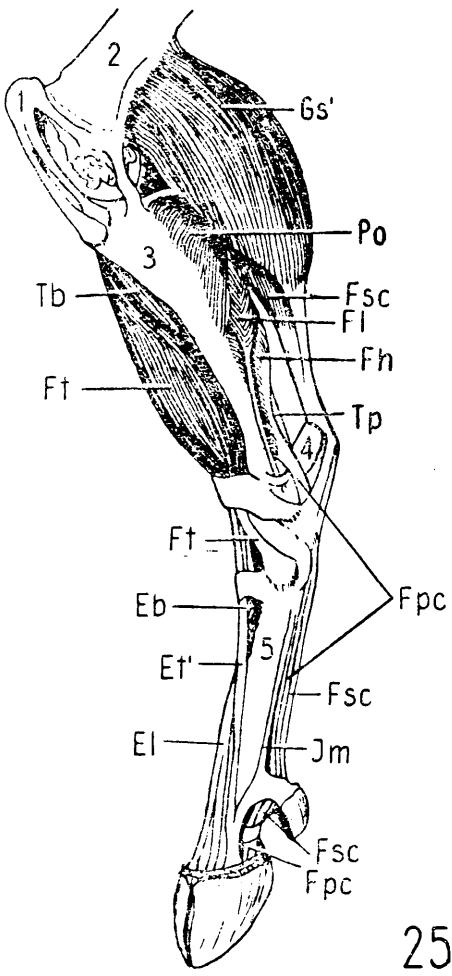


24

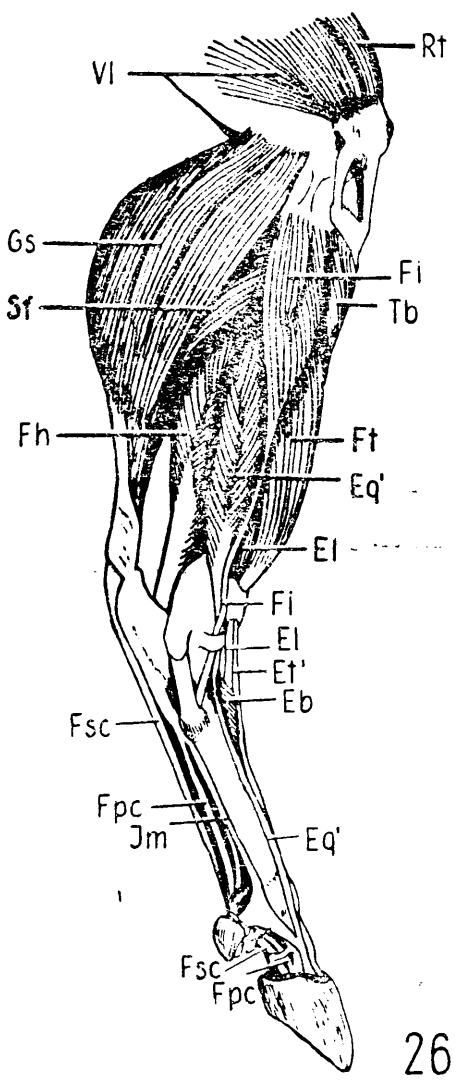
Plate XLIII.

Fig. 25. Muscles of leg and foot of European bison. Medial view. 1 — *patella*;  
2 — *femur*; 3 — *tibia*; 4 — *calcaneus*; 5 — *metatarsus*.

Fig. 26. Muscles of right leg and foot of European bison. Lateral view.



25

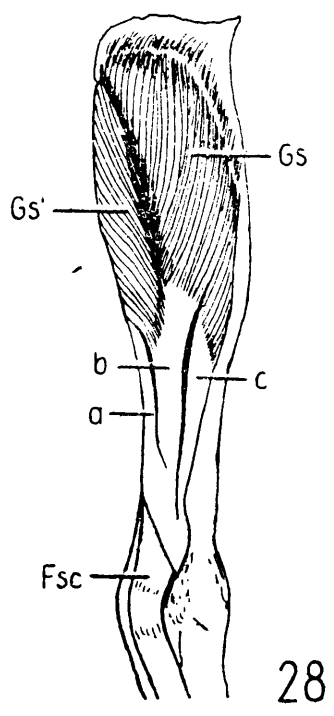
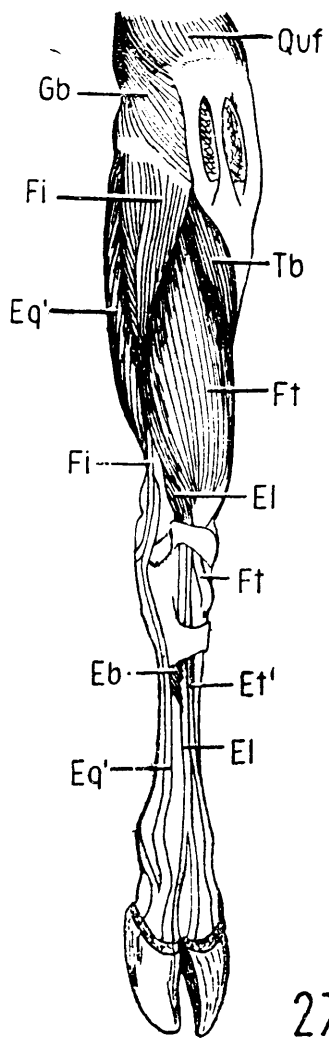


26

Plate XLIV.

Fig. 27. Muscles of right leg and foot of European bison. Dorsal view.

Fig. 28. *M. gastrocnemius* of European bison. Plantar view. a— medial tendon;  
b — middle tendon; c — lateral tendon.







Plate XLV.

Fig. 29. Musculature of European bison, ♂. The superficial muscle are removed.



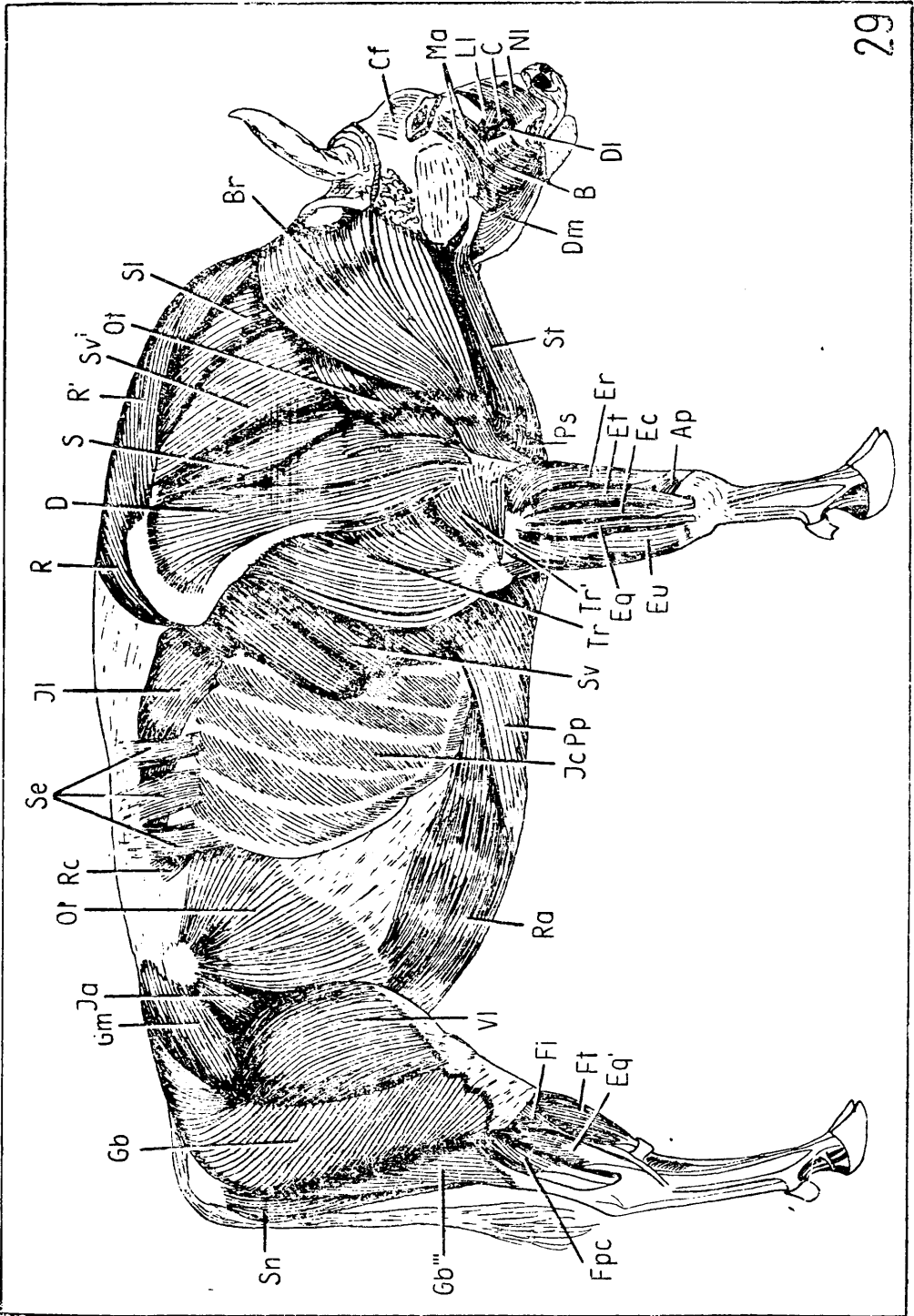
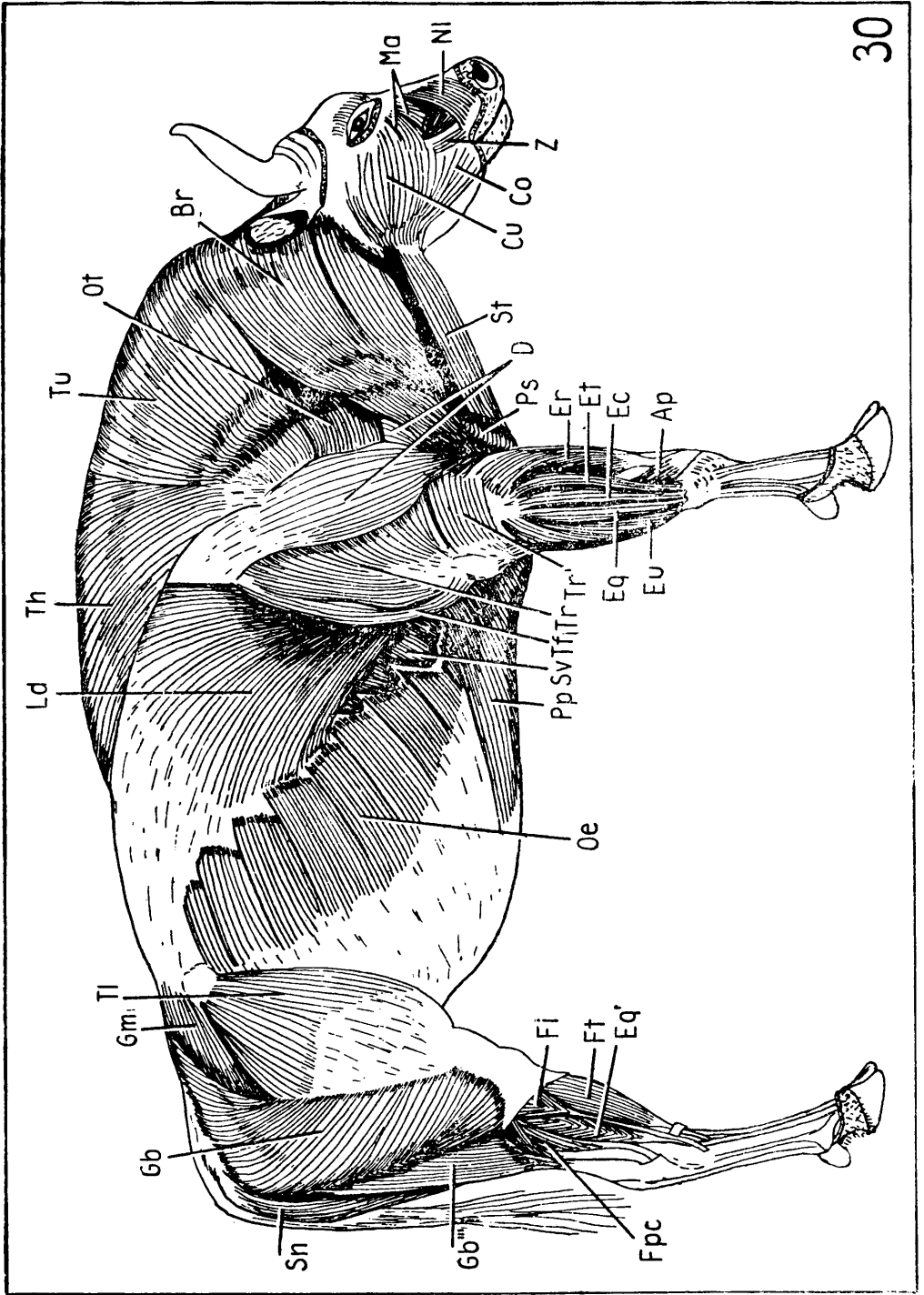



Plate XLVI.

Fig. 30. Musculature of European bison, ♂.







## KEY TO THE LETTERING

A — *m. anconeus*  
 Ap — *m. abductor pollicis longus*  
 Ao — *m. atlantoccipitalis*  
 B, B', B'' — *m. buccinatorius*  
 Bb — *m. biceps brachii*  
 Bc — *m. brachialis*  
 Br — *m. brachiocephalicus*  
 Bv — *m. biventer (venter anterior)*  
 Bv' — *m. biventer (venter posterior)*  
 C — *m. caninus*  
 Cb — *m. coracobrachialis*  
 Cf — *m. cutaneus frontalis*  
 Cl — *m. cleidomastoideus*  
 Co — *m. cutaneus labiorum*  
 Cu — *m. cutaneus faciei*  
 D — *m. deltoideus*  
 D' — *m. deltoideus (p. acromialis)*  
 Dl — *m. depressor labii maxillaris*  
 Dm — *m. depressor labii mandibularis*  
 Eb — *m. ext. digit. pedis brevis*  
 Ec — *m. ext. digit. communis*  
 El — *m. ext. digit. pedis longus*  
 Eq — *m. ext. digiti IV proprius*  
 Eq' — *m. ext. digiti IV proprius (pelvic limb)*  
 Er — *m. ext. carpi radialis*  
 Et — *m. ext. digiti III proprius*  
 Et' — *m. ext. digiti III proprius (pelvic limb)*  
 Eu — *m. ext. carpi ulnaris*  
 Fh — *m. flex. hallucis longus*  
 Fi — *m. fabularis longus*  
 Fl — *m. flex. digit. pedis longus*  
 Fp — *m. flex. digit. profundus*  
 Fph — *m. flex. digit. profundus caput humerale*  
 Fpr — *m. flex. digit. profundus caput radiale*  
 Fpu — *m. flex. digit. profundus caput ulnare*  
 Fpc — *m. flex. digit. pedis profundus*  
 Fr — *m. flex. carpi radialis*  
 Fs — *m. flex. digit. superficialis*  
 Fs' — *m. flex. digit. superficialis (caput profundum)*  
 Fsc — *m. flex. digit. pedis superficial.*  
 Ft — *m. fibularis tertius*  
 Fu — *m. flexor carpi ulnaris*  
 G — *m. gracillis*  
 Ga — *m. gluteus accessorius*  
 Gb — *m. gluteobiceps*  
 Gb' — *m. gluteobiceps (anterior part)*  
 Gb'' — *m. gluteobiceps (middle part)*

Gb''' — *m. gluteobiceps (posterior part)*  
 Ge — *m. gemellus*  
 Gm — *m. gluteus medius*  
 Gp — *m. gluteus profundus*  
 Gs — *m. gastrocnemius (caput laterale)*  
 Gs' — *m. gastrocnemius (caput mediale)*  
 I — *m. infraspinatus*  
 Ia — *m. iliacus (caput laterale)*  
 Ia' — *m. iliacus (caput mediale)*  
 Ic — *m. intercostalis externus*  
 Il — *m. iliocostalis*  
 Im — *m. interosseus medius*  
 In — *m. interdigastricus*  
 Is — *m. interspinalis*  
 It, It', It'' — *m. intertransversarius*  
 J — *m. sternohyoideus*  
 La — *m. longissimus atlantis*  
 Lc — *m. levator costae*  
 Ld — *m. latissimus dorsi*  
 Lg — *m. longus colli*  
 Li — *m. longissimus dorsi*  
 Lk — *m. longus capitis*  
 Ll — *m. levator labii maxillaris proprius*  
 Lp — *m. longissimus capitis*  
 Lr — *m. longissimus cervicis*  
 Lt — *m. longus atlantis*  
 M, M' — *m. masseter*  
 Ma — *m. malaris*  
 Mc — *m. multifidus cervicis*  
 Md — *m. multifidus dorsi*  
 Nl — *m. levator nasolabialis*  
 Oe — *m. obliquus abdominis externus*  
 Oi — *m. obliquus abdominis internus*  
 Om — *m. omohyoideus*  
 Or — *m. obliquus capitis cranialis*  
 Ot — *m. omotransversarius*  
 Ou — *m. obliquus capitis caudalis*  
 P — *m. pectineus*  
 Pi — *m. piriformis*  
 Pj — *m. psoas major*  
 Pm — *m. psoas minor*  
 Po — *m. popliteus*  
 Pp — *m. pectoralis profundus*  
 Ps — *m. pectoralis superficialis*  
 Ptl — *m. pterygoideus lateralis*  
 Ptm — *m. pterygoideus medialis (superficial layer)*  
 Ptm' — *m. pterygoideus medialis (deep layer)*

Qf — *m. quadratus femoris*  
 Ql — *m. quadratus lumborum*  
 Quf — *m. quadriceps femoris*  
 R — *m. rhomboideus (pars thoracalis)*  
 R' — *m. rhomboideus (p. cervicalis)*  
 Ra — *m. rectus abdominis*  
 Rc — *m. retractor costae*  
 Rj — *m. rectus capitis dorsalis major*  
 Rl — *m. rectus capitis lateralis*  
 Rt — *m. rectus femoris*  
 S — *m. supraspinatus*  
 Sa — *m. sartorius*  
 Sb — *m. semimembranosus*  
 Sc — *m. spinalis cervicis*  
 Sd, Sd' — *m. spinalis et semispinalis dorsi (pars lateralis et medialis)*  
 Se — *m. serratus dorsalis (pars caudalis)*  
 Sf — *m. soleus*  
 Si — *m. serratus dorsalis (pars cranialis)*  
 Sl, Sl', Sl'', Sl''' — *m. splenius*  
 Sm — *m. semispinalis capitis*  
 Sn — *m. semitendinosus*  
 So — *m. semispinalis lumborum*  
 Sp — *m. scalenus primae costae (p. dorsalis)*  
 Spv — *m. scalenus primae costae (p. ventralis)*  
 Sr — *m. sternomastoideus*  
 Ss — *m. scalenus supracostalis*  
 St — *m. sternomandibularis*  
 Su, Su', Su'' — *m. subscapularis*  
 Sv, Sv' — *m. serratus ventralis (p. thoracalis et cervicalis)*  
 T, T' — *m. temporalis*  
 Ta — *m. teres major*  
 Tb — *m. tibialis anterior*  
 Tc — *m. transversus costarum*  
 Tf — *m. tensor fasciae antibrachii*  
 Th — *m. trapezius (p. thoracalis)*  
 Ti — *m. teres minor*  
 Tl — *m. tensor fasciae latae*  
 Tp — *m. tibialis posterior*  
 Tr, Tr', Tr'', Tr''' — *m. triceps brachii*  
 Ts — *m. transversus abdominis*  
 Tt — *m. transversus thoracis*  
 Tu — *m. trapezius (p. cervicalis)*  
 Vl — *m. vastus lateralis*  
 Vm — *m. vastus medialis*  
 Z — *m. zygomaticus*