

JAN NIELUBOWICZ, BERTOLD KASSUR, TADEUSZ ORŁOWSKI, WALDEMAR OLSZEWSKI, WOJCIECH ROWIŃSKI, MIECZYŚLAW SZOSTAK, TADEUSZ TOŁŁOCZKO, JERZY POLAŃSKI, HANNA ŁUKASIEWICZ, MARIA ROSNOWSKA, BOGDAN KAMIŃSKI, JANUSZ KĄCKI, WŁODZIMIERZ KARDASIEWICZ, ZDZISŁAW MACHOWSKI, EWA MAYZNER, BOGDAN MICHAŁOWICZ, ZBIGNIEW OLEJNIK, KAZIMIERZ OLSZEWSKI, BARBARA RYCHALSKA, SŁAWOMIR PLUCIŃSKI, IRENEUSZ POMASKI, ZBIGNIEW PRZETAKIEWICZ, ZBIGNIEW SAWICKI, JERZY SIEDLECKI, MAREK SKOŚKIEWICZ, JERZY SOKOŁOWSKI, JERZY SZCZERBAŃ, JACEK SZMIDT, STANISŁAW ZAJĄC, ANDRZEJ ZAWADZKI, ADAM TOPPERCER

EXTRACORPOREAL HETEROLOGOUS LIVER PERFUSION IN MAN

Department I of Surgery, Medical Academy in Warsaw, Surgical Research Laboratory, Polish Academy of Sciences in Warsaw, Department I of Internal Diseases, Medical Academy in Warsaw

The authors described four cases of acute liver insufficiency, treated by means of extracorporeal perfusion of pig liver. Three patients developed acute liver insufficiency in the course of acute viral hepatitis, and one as the sequel of liver cirrhosis. In total, eleven perfusions were carried out, each lasting for 3—6 hours. Alterations in body fluids composition as well as disorders of blood clotting arisen during the perfusion, are described in detail. Two patients were cured.

In 1966—1969 eighty experimental extracorporeal liver perfusions were performed on pigs in the Surgical Research Laboratory of the Polish Academy of Sciences in Warsaw (10, 11, 13, 14, 17, 18, 19). The experiments were planned as a preparatory step for extracorporeal liver perfusion in patients with hepatic coma, and also as a supportive measure before, during and after liver transplantation. As a result of the studies the technique of isolated liver perfusion was elaborated. It also became evident that thorough biochemical studies of the liver function, and of the patient perfusing the heterologous liver should be carried out continuously during the perfusion procedure. To evaluate the function of the liver and the state of its recipient, and to maintain them within proper limits the coagulation and fibrinolysis system should be checked continuously, arterial blood pH maintained between 7.35—7.45, blood glucose level kept at 120—200 mg%, and hypovolemia avoided.

MATERIAL AND METHODS

Patients, candidates for extracorporeal liver perfusion, were transferred to a specially designed Liver Perfusion Unit. The procedure was usually started with two intravenous drips, one into the cubital veins, the other to the large saphenous vein in the ankle region. The central venous pressure was measured by means of a cannula inserted through the cubital vein. Blood samples were taken from another cannula in the veins of a lower limb or hand. The arterial pressure was monitored continuously in the radial artery. An interval catheter was placed in the bladder to measure the hourly diuresis.

The removal of pig liver was started in the Research Laboratory (13, 14, 17) at the same time with cannulation of patient's blood vessels. Through a vertical 10–12 cm long incision below the inguinal ligament the common, superficial and deep femoral artery were dissected along with the neighboring veins. A metal cannula was inserted into the common femoral artery through an incision in the superficial femoral artery. A high arterial flow could thus be obtained with an adequate blood supply for the arterial and portal systems. Another cannula was placed in the femoral vein. Polyvinyl tubing was used to connect cannulae with the patient's vessels. The tubing was filled with a heparin saline solution. In the meantime the liver container was prepared for liver reception, all the connections being sealed off with pliable wire.

Pig liver transported to the Perfusion Unit in a sterile bag was placed in the container, the patient's femoral artery being connected with the hepatic artery and portal vein, and the suprahepatic portion of the inferior vena cava of the liver with the femoral vein. The whole perfusion system was checked for the presence of air bubbles. The clamps were taken off and perfusion was started. The ischemia time of the liver ranged between 40 and 56 minutes. The cystic duct was then ligated and the common bile duct cannulated. The bile cannula was given an external outlet (Fig. 1).

The amount of excreted bile and its bilirubin concentration was measured every hour. The liver blood flow was estimated every 30 minutes, and calculated in ml/g of liver weight/minute. The liver container was filled with Ringer's solution at the temperature of 38°C, so that the liver temperature could be kept at the physiological level. Perfusion of the extracorporeal liver lasted for 3 or 6 hours depending on the condition of the patient and the gross appearance of the liver. After termination of the perfusion the cannulae were removed from the vessels. The femoral superficial artery was sutured or ligated close to the deep femoral artery and the femoral vein ligated. The wound was then stitched and suction drainage instituted. During the second perfusion, on the next day, the same vessels were cannulated or the other side dissected. After termination of the perfusion (6, 12, 24 hours) the patients were transferred back to the Department of Infectious Diseases.

The following laboratory tests were performed in all patients before the perfusion: blood group, RBC count and hemoglobin level, platelet count, total protein content, paper electrophoresis, BUN, glucose, bilirubin, electrolyte, ammonia, lactic acid, pyruvic acid concentration, SGOT, SGPT, LDH, GLDH and alkaline phosphatase activity. Oxygen and carbon dioxide partial pressure as well as serum bicarbonate and blood pH were measured. The coagulation and fibrinolysis system was studied with clotting time, prothrombin time, calcium clotting time, thrombin time, factor V and VII, prothrombin consumption test, fibrinogen concentration, whole blood fibrinolysis and euglobulin lysis time estimations.

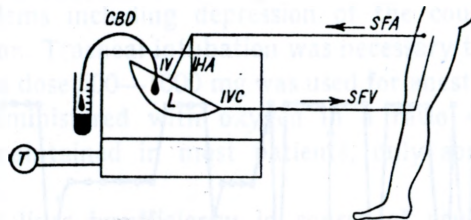


Fig. 1. SFA: superficial femoral artery, SFV: superficial femoral vein, IVC: inferior vena cava HA: hepatic artery, PV: portal vein, CBD: common bile duct, L: liver, T: thermostat

Bilirubin concentration was measured in the bile, and also in the fluid surrounding the liver in the container.

Serum total protein was measured by the biuret method, electrophoretic pattern with paper electrophoresis, BUN by the method of Kowarski, blood glucose concentration colorimetrically with ortotoluidine, electrolytes with Zeiss flame photometer, blood ammonia level by the Jouany and Reynier diffusion method (7), lactic acid by the method of Homolka (5), and pyruvic acid by that of Nateslson (12), serum bilirubin level by the modified method of Malloy and Evelyn (12, 22), aminotransferase activity by the colorimetric method of Umbreit (1, 23). The DeRitis factor was calculated from the ratio SGOT to SGPT. Paranitrophenylophosphate sodium (1, 20, 22) was used for the estimation of alkaline phosphatase activity. Oxygen and carbon dioxide partial pressure and blood pH was measured with Astrup's equipment. For clotting time measurement Lee-White's method was used. Prothrombin time was estimated by Quick's method, calcium clotting time according to *Niewiarowski* (16), thrombin time also according to *Niewiarowski* (16), factor V by the method of Wolff, factor VII with that of Keller, prothrombin consumption according to Quick, Fayre-Gilly, fibrinogen concentration according to Quick, whole blood fibrinolysis by Halse's method, and euglobulin lysis time with that of *Niewiarowski* (16). Bile was diluted 100-fold for bilirubin concentration measurement, and fluid from the container spun down, the supernatant being used for the estimation of the bilirubin level.

The following laboratory tests turned out to be most useful in the evaluation of the extracorporeal perfusion: 1) hematocrit, 2) platelet count, 3) coagulation and fibrinolysis, 4) acid-base balance (pH, $p\text{CO}_2$, $p\text{O}_2$, HCO_3), 5) serum electrolytes with potassium in the first place, 6) blood glucose level, 7) blood ammonia level, 8) BUN. All the abnormalities detected by these tests prompted us to take immediate protective measures. Low hematocrit gave the indication for blood transfusion, low platelet count for fresh blood transfusion, pH below 7.35 for infusion of 5% sodium bicarbonate solution. Low potassium concentration was controlled by means of an intravenous drip of a 1 M potassium chloride solution and aldacton. An intravenous 5% glucose solution infusion was done throughout the whole perfusion period to maintain a blood glucose level of about 200 mg%.

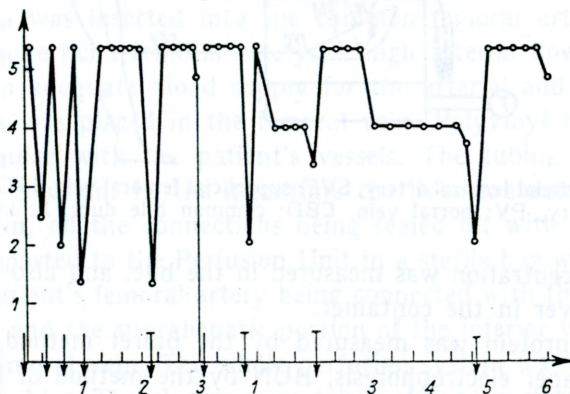


Fig. 2. Thrombin clotting time (measured after addition of potent thrombin, normal values 5 minutes). On the ordinate clotting time, on the abscissa time of perfusion. Arrows show heparin dosage, — 50 mg, — 100 mg. Perfusion in patient J. R.

Particular attention was paid to the changes in the coagulation and fibrinolysis system (10, 11). Heparin was administered in high and frequent doses to prevent clot formation in the tubings. A rapid drop in fibrinogen concentration and increased fibrinolytic activity of the plasma had to be controlled by inhibitors of fibrinolysis. Before the release of clamps at the beginning of perfusion the patient was given 100 mg of heparin, followed by clotting time estimation with a potent thrombin solution every 10 minutes. Normally clotting time measured by this method did not exceed 5 minutes, which corresponds to 30 minutes using normal techniques. In case the clotting time decreased to 2.5 minutes an additional dose of 50 mg of heparin was given. Treatment with high doses of heparin quite often resulted in profuse wound bleeding, and also in complications in arterial and venous suture.

More than ten doctors and technicians took part in every perfusion procedure. During one typical procedure 312 laboratory tests were performed. Out of that number 188 were necessary for the proper and safe continuation of the perfusion. Some 480 ml of blood were used for the biochemical studies.

Extracorporeal porcine liver perfusion was carried out in four patients with hepatic coma complicating liver insufficiency. The patients were unconscious for a period of 2 to 4 days. Three patients demonstrated typical cerebral focal symptoms. One patient was completely areflexive including a lack of reaction to light. In one clonic tremor was seen. All patients had visible jaundice, with an average bilirubin concentration of 22 mg%.

All patients remained under the continuous care of anesthetists. Most patients had respiratory problems including depression of the coughing reflex, and bronchial hypersecretion. Tracheal intubation was necessary to maintain proper ventilation. Viadril in a dose 500—1000 mg was used for anesthesia, in two cases nitrous oxide was administered with oxygen in a ratio 4:2. Spontaneous breathing could be maintained in most patients, only sometimes requiring mechanical assistance.

Three patients had liver insufficiency in course of acute viral hepatitis, one was cirrhotic, 4 months after a spleno-renal shunt. Extracorporeal perfusion lasted 3 or 6 hours, three patients had two perfusions, the one with liver cirrhosis only one perfusion.

RESULTS

Two patients with viral hepatitis recovered, two others died. In one of them, the cause of death was an acute viral process, in the other one — advanced cirrhosis. Patients who recovered were discharged from the Department of Infectious Diseases 5 and 2 months after the perfusion. Various complications developed in those patients at the initial period after the perfusion. They were: acute non-inflammatory renal insufficiency, wound infection, septic hemorrhages from the site of arteriotomy, pneumonia and septicemia.

At the moment of clamp release many untoward reactions were observed in them. Increased vascular space resulted in a rapid accumulation of blood in the extracorporeal liver. Transfusion of blood and electrolyte solutions were necessary to avoid temporary hypotension. If the transfusion was not adequate the central venous pressure dropped rapidly, so did the arterial pressure. The pulse rate increased and liver blood flow diminished. The amount of blood necessary to maintain normal pressure and flow was 500—750 ml. Post-perfusion anesthetic care required an endotracheal tube for 6—8 hours, oxygen therapy, removal of tracheal secretion, and sometimes, assisted ventilation.

Major coagulation and fibrinolysis changes were encountered in all patients. The platelet count dropped rapidly during the first hour of perfusion. In patient

R. J. the platelet concentration decreased in the initial two hours from 180,000 to 50,000, in the 6th hour reaching 20,000 in cu mm. On the day following the perfusion the platelet count stayed at a low level of 30–50,000 despite transfusion of fresh blood. High heparin consumption was noted. This required administration of rather high doses of heparin, in patient R. J. reaching 500 mg in 6 hours.

The results of the biochemical studies are listed below. Before perfusion, the total serum protein concentration was 6.7 g%, dropping after a 6-hour perfusion to 4.68 g%, and remaining at that low level during the next perfusion, and also for some days afterwards. The most prominent was the fall in albumin concentration, with a low albumin : globulin ratio reaching 0.55 in patient R. J.

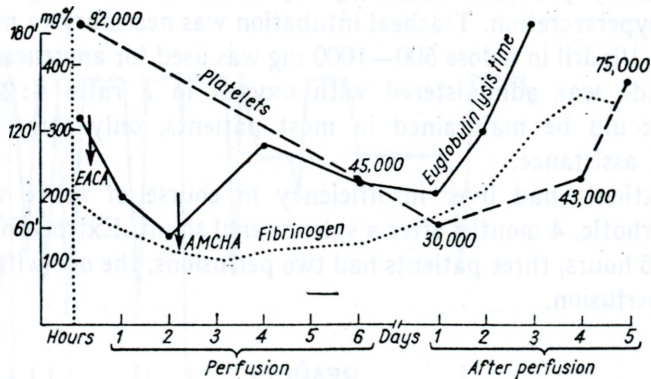


Fig. 3. 6-hour perfusion, platelet count, euglobulin lysis time, and fibrinogen concentration.

A blood glucose level of 200 mg% was maintained more or less steadily with intravenous glucose infusion. Large amounts of glucose had to be infused. During a 3-hour perfusion, patients R. J. received 1500 ml of 5% glucose solution, and 2000 ml during the second, 6-hour perfusion. No changes in sodium or chloride concentration were observed. A substantial drop in potassium concentration was noted, in patient R. J., down to 2.21 mEq/l. That drop could have been prevented by continuous potassium and aldacton administration. No specific changes in ammonia, BUN, lactate, pyruvate level were found. Also SGOT activity remained unchanged. The DeRitis factor rose to above 1 in all but one patient in whom it was 8.

LDH activity decreased considerably in all patients. Alkaline phosphatase activity had a tendency to decrease steadily with end values below 20 units. On the other hand GLDH activity tended to increase and reached high values by the end of each perfusion. Serum bilirubin concentration dropped in all patients from the average 22.2 mg% to 7.7 mg%.

Arterial blood pH remained unchanged. There were minor fluctuations in arterial blood O₂ partial pressure, bicarbonate level and carbon dioxide partial pressure.

The liver blood flow ranged from 0.45 to 0.66 ml/g of liver/min. Bile production reached highest values in the first hour of perfusion, its average values throughout the entire time of perfusion were 0.34 to 1.59 ml/100 g of liver/hour (Table I). Bile collected from the extracorporeal liver was alkaline and light yellow in color.

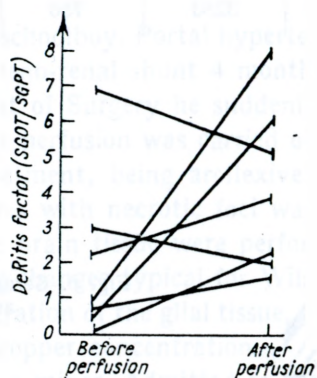


Fig. 4. De Ritis factor in various patients.

Table I
Blood flow and bile excretion during liver perfusion

Patients	Time of perfusion	Blood flow in ml/g/min	Bile excretion in ml/100 g/hr
I. R.	180	0.64	1.59
40 years	360	0.55	0.15
A. J.	360	0.56	0.625
15 years			
J. B.	360	0.45	1.1
26 years	180	0.66	0.34
P. R.	270	0.125	0.626
23 years	270	0.79	0.084

Some of the liver enzymes and bilirubin transudated through the liver capsule to the fluid in which pig liver was immersed. SGOT and SGPT activity in that fluid amounted to 180 and 68 u/ml, LDH activity to 340, and that of GLDH to 8.73 units. Bilirubin concentration was on the average 3.8 mg%.

Every patient had multiple transfusions of blood and electrolyte solutions. The average amounts were: for blood 2070 ml, for dextran 400 ml, and for 5 percent glucose 2370 ml (Table II).

Table II
Amount of blood and fluids transfused during perfusion

Patients	Blood in ml	Plasma in ml	Dextran in ml	5% glucose sol. in ml
I. R. J. — 3 hours	1000	600	500	1000
II. R. J. — 6 hours	2750	2000	500	2500
I. P. R. — 4.5	1750	2000	—	3500
II. P. R. — 4.5	2500	800	1000	2500
I. B. J. — 6	1000	900	—	1500
II. B. J. — 3	1750	300	—	1500
I. J. A. — 6	3250	750	1000	4000

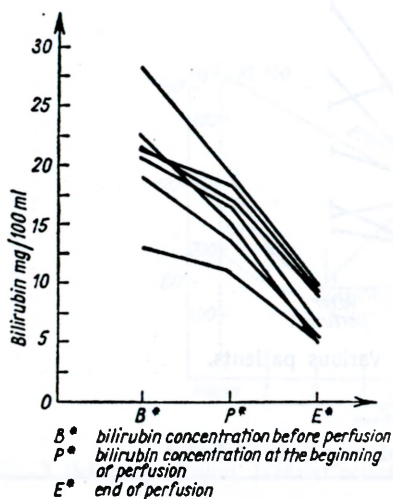


Fig. 5. Serum bilirubin concentration before and after the perfusion.

SUMMARY OF CLINICAL HISTORIES

Patient J. R., aged 40, physical worker. Admitted on March 31, 1969 to the Department of Infectious Diseases with a diagnosis of viral hepatitis. Eight days later precomatose symptoms developed. He was first slightly disoriented and apathetic, then drowsy, only to become fully comatose on the following day. At that time, he was unconscious and had paralysis of the right facial nerve, positive Balinski, Oppenheim and Rossolimo reflexes, pain and stiffness in the neck and back, and respiratory disturbances. The general condition of the patient deteriorated rapidly despite intensive conservative treatment, and he was transferred to the Department I of Surgery for extracorporeal heterologous liver perfusion.

Biochemical data before the perfusion: serum bilirubin 8.9 mg%, SGOT activity 340 u, SGPT 1400 u, alkaline phosphatase 5.6 u, total protein 6.7 h%, albumin 58%, HCO_3^- 33.3 mEq/l. Two perfusions were carried out on April 9 and 11, 1969. The first lasted for 3, the second for 6 hours. Ten hours after the

second perfusion the patient became conscious, responded to voice stimuli, could even pronounce his name. Several complications developed at the post-perfusion period. They were: non-inflammatory renal insufficiency treated with five peritoneal dialyses, *Staphylococcus aureus* and *E. coli* septicemia, hemorrhagic diathesis, three profuse septic bleedings from the sites or arteriotomy leading to ligation of the superficial femoral artery, and left ventricular insufficiency with pulmonary edema. He was discharged on September 18, 1969 in satisfactory condition. No complaints in the follow-up period, except of slight intermittent claudication.

2. Patient A. J., aged 15, schoolboy. Portal hypertension in the past history, treated surgically with a spleno-renal shunt 4 months ago. Four days before admission to the Department of Surgery he suddenly fell into hepatic coma. A 6-hour extracorporeal liver perfusion was carried out. The patient remained in a deep coma despite treatment, being areflexive he died 10 hours later. Atrophic cirrhosis of the liver with necrotic foci was found at autopsy.

Histological studies of the brain tissue were performed in the Neuropathological Laboratory, revealing changes typical for Wilson's disease. They were: medium-grade edema, degeneration of the glial tissue, Alzheimer's cells I and II, Opalski's cells, and a high copper concentration.

3. Patient J. B., aged 26, a miner. Admitted to the Hospital for Infectious Diseases on August 25, 1969 because of viral hepatitis on the 10th day of its duration. He became rapidly comatose and was transferred to Department I of Surgery for extracorporeal liver perfusion. Two consecutive perfusions were carried out on September 5th and 6th, 1969, lasting for 5 and 3 hours. After a time-lapse of 16 hours after the last perfusion he regained consciousness. At the post-perfusion period septic bleedings from the sites of arteriotomy occurred requiring ligation of the common and external iliac artery. Discharged on November 15, 1969 in satisfactory condition. No complaints during the follow-up period.

4. Patient R. P., aged 23, scientist. Admitted to the Department of Infectious Diseases in Warsaw on October 20, 1969 with the diagnosis of hepatic coma due to acute viral hepatitis. She deteriorated despite intensive conservative treatment with steroids. At the time of admission to the Department of Surgery she was areflexive, and with clonic tremor. Two consecutive 4 and 5 hour lasting perfusions were carried out on October 20 and 21, 1969. No improvement was observed afterwards. Transferred back to the Department of Infectious Diseases where she remained unconscious and died on October 25, 1969.

DISCUSSION

Extracorporeal heterologous liver perfusion for treatment of hepatic coma in man was designed and first performed by *Eiseman* (3, 4, 5, 8, 9). According to the available literature on this subject (14) 73 patients were treated with this

method until 1970 and 16 out of that number recovered. The author's experience is limited to four cases with two recoveries.

Extracorporeal perfusion remains at the stage of clinical therapeutical experimenting, being based on sound theoretical grounds. The liver belongs to organs indispensable for the preservation of life. Its metabolism is a complex one and not well understood by physiologists. This being so, there exists no possibility of repairing the liver in case of major degenerative changes. In such a situation the organ should be replaced by a new one. However, liver possesses some regenerative properties, and if changes in the liver tissue are reversible like in viral hepatitis or at the initial stages of hepatic cirrhosis, they may allow the patient to survive if the deficient metabolic function can be supported for some time with measures like extracorporeal perfusion.

One of the main problems in liver perfusion is the proper selection of patients for this type of treatment. There are no objective data which would indicate that the liver function is deficient enough to discontinue conservative treatment and transfer the patient to the Department of Surgery for liver perfusion. According to our experience the patient in deep coma for 24—48 hours with progressing deterioration of his neurological state should be perfused as quickly as possible.

In this paper we do not discuss the immunological problems connected with heterologous liver perfusion. Extracorporeally placed liver behaves like a xenograft, nevertheless no major clinical allergic reactions have been observed in our patients or reported in the literature (3, 4, 5, 14), even if the perfusion was repeated several times at short intervals.

On the whole extracorporeal liver perfusion remains still at the stage of clinical experimentation. Its value in the treatment of hepatic coma in patients with acute liver insufficiency is awaiting proper evaluation with the increase in clinical experience.

Translated by W. Olszewski, M. D.

REFERENCES

1. *Bergmayer, H.*: Methods of enzymatic analysis. Verlag Chemie G. M. B. H., 1963.
2. *Bogdanikowa, B.*: Klinika białek krwi (Blood proteins). P.Z.W.L., Warsaw 1960.
3. *Eiseman, B. et al.*: Heterologous liver perfusion in treatment of hepatic failure. *Ann. Surg.* 1965, 162, 329.
4. *Eiseman, B.*: Methods for extracorporeal hepatic assist. *Surg. Gynec. Obst.*, 1966, 23, 522.
5. *Eiseman, B.*: Treatment of hepatic failure. In the textbook of *A. E. Read*, the Liver Burtherworths, London 1967.
6. *Homolka, J.*: Diagnostyka biochemiczna (Biochemical diagnostic methods). P.Z.W.L. Warsaw 1961.
7. *Jouany, J., Reynier, M.*: Une mesure de l'ammoniémie par diffusion. *Anesth. Analg. Reanim.*, 1959, 16, 393.

8. *Kestens, P. J.*: La perfusion du foie isole. Edition Arscia S. A., Bruxelles, Liblirie Maloine S. A., Paris 1964.
9. *Kommerall, B.*: Möglichkeiten und Grenzen der modern Leberkoma Therapie. Deut. Med. Wochenschr., 1969, 43, 22, 35.
10. *Łukasiewicz, H.*: Badania krzepnięcia i fibrynolizy krwi u chorego w czasie perfuzji pozaustrojowej wątroby świni (Blood coagulation and fibrinolysis in patient during the extracorporeal liver perfusion). Pol. Przegl. Chir. (in press).
11. *Łukasiewicz, H. et al.*: Układ krzepnięcia i fibrynolizy u świni podczas pozaustrojowego podłączenia wątroby (Coagulation nad fibrinolysis system in the pig during extracorporeal liver perfusion). Pol. Przegl. Chir. (in press).
12. *Nateslson, S.*: Microtechniques of clinical chemistry. Illinois 1957.
13. *Nielubowicz, J., Olszewski, W., Rowiński, W., Bulien, D., Gruchalski, J., Machowski, J., Meyzner, E., Polański, J., Pluciński, S., Sokolowski, J., Skośkiewicz, M., Szmidt, J.*: Badania doświadczalne pozaustrojowej perfuzji wątroby (Experimental studies on extracorporeal liver perfusion). Pol. Przegl. Chir., 1969, 50, 1.
14. *Nielubowicz, J.*: Pozaustrojowa perfuzja wątroby (Extracorporeal liver perfusion). Biul. Akad. Med., 1969, 2, 157.
15. *Nielubowicz, J., Kassur, B.*: Pozaustrojowa perfuzja wątroby (Extracorporeal liver perfusion). Pol. Arch. Med. Wewn. Editorial (in press).
16. *Niewiarowski, S.*: Metody badania układu krzepnięcia krwi i ich interpretacja (Methods of study of the coagulation system and their interpretation). In the textbook: Clinical Hematology. P.Z.W.L., Warsaw 1962.
17. *Olszewski, W., Polański, J., Bulien, D., Graban, W., Nielubowicz, J.*: Zaburzenia metaboliczne i hemodynamiczne w perfundowanej pozaustrojowo wątrobie (Metabolic and hemodynamic changes in the extracorporeal liver perfusion). Pol. Przegl. Chir., 1969, 42, 757.
18. *Olszewski, W. et al.*: Przechowywanie wątroby świni za pomocą stałej perfuzji w hipotermii. I. Zmiany biochemiczne i przepływu w przechowywanej przez 3 godziny wątrobie (Liver preservation under continuous hypothermic perfusion. I. Biochemical and flow changes during 3-hour preservation). Pol. Przegl. Chir. (in press).
19. *Olszewski, W. et al.*: Przechowywanie wątroby świni za pomocą stałej hipotermii. II. Ocena czynności przechowywanej wątroby po podłączeniu do zwierzęcia (Liver preservation under continuous hypothermic liver perfusion. II. *In vivo* evaluation of liver function). Pol. Przegl. Chir. (in press).
20. *Rosnowska, M. et al.*: Aktywność niektórych enzymów podczas perfuzji i perfuzji izolowanej wątroby świńskiej (Enzyme activity during extracorporeal liver perfusion). Diagn. Lab. (in press).
21. *Rosnowska, M. et al.*: Próba oceny przemiany węglowodanowej w perfundowanej wątrobie świńskiej (Evaluation of carbohydrate metabolism in the perfused liver). Diagn. Lab. (in press).
22. *Rosnowska, M. et al.*: Czynność wątroby i niektóre wskaźniki laboratoryjne podczas 3 godzinnej perfuzji pozaustrojowej u chorego z ostrą niewydolnością wątroby (Liver function and laboratory data during 3-hour liver perfusion in patient with hepatic coma). Diagn. Lab. (in press).
23. *Umbreit, W., Kingsley, G., Schlaffert, R. A.*: Calorimetric method for determination of transaminases in serum or plasma. J. Lab. Clin. Med., 1957, 49, 454.

Author's address: ul. Nowogrodzka 59, Warszawa (Poland).