

J. NIELUBOWICZ, W. OLSZEWSKI, Z. MACHOWSKI, J. SOKOŁOWSKI

EXPERIMENTAL INVESTIGATIONS ON LYMPHATICO-VENOUS COMMUNICATIONS IN EXTREMITIES

Department of Experimental Surgery, Polish Academy of Sciences, Warsaw

In search for natural lymphatico-venous communications in the extremities of healthy dogs, the authors revealed in 30 percent of the examined animals the passing of an aqueous contrast medium from lymphatic vessels of the shin and from the popliteal lymph node to the popliteal vein.

The problem of lymphatico-venous communications plays an essential part in the studies on lymphostasis in extremities. It is known that in cases of occlusion of the iliac or axillar lymphatic vessels due to a neoplastic process the communications between peripheral lymphatic vessels and extremital veins open (or develop?). This phenomenon presents a common mechanism aiming at decompression of lymphostasis (2, 3, 12). Similarly, a lymphostasis produced by ligation of the thoracic duct rapidly subsides because of opening of communications between the cisterna chyli, and the lower part of thoracic duct, and the inferior vena cava and the azygos vein (2).

The problem whether such connections exist under normal conditions, whether they can be seen in anatomical specimens, and what part they have in lymph circulation was studied by many authors (1, 5, 11, 13, 14, 15).

We have undertaken investigations on experimentally induced lymphostasis and attempted to explain, at the initial stage of the work, the following problems:

1. Do lymphatico-venous communications exist in dog's extremity under normal conditions, and whether they can be visualized by means of lymphography?
2. Do these connections unite magistral extremital lymphatic vessels or, are they situated within the lymph nodes?

METHODS

Investigations were carried out on 20 mongrel dogs weighing 12—16 kg. With the scope of making the lymphatic vessels visible 0.1 ml of a 5 percent solution of patent blue was injected intradermally into the dorsal surface of the

animal's hind leg. Consequently, one of lymphatic vessels in the tinted region was exposed by means of an incision and its lumen was cannulated. The animals were destroyed with a lethal dose of eunarcone, and 15 minutes later lymphography was carried out. Five ml of urographin (molecular weight 809) was injected within 30 sec through the previously inserted cannula into the lymphatic vessel. The pressure in lymphatic vessel on injecting the radioopaque medium amounted to 50—60 cm H₂O. After the injection was completed an X-ray picture of the extremity was taken.

RESULTS

Of 40 extremital lymphograms thus performed the contour of popliteal vein was visible in 15 specimens. Among the last, veins situated near the popliteal lymph node and the popliteal vein communicating with them, were perceptible in 7 (Fig. 1, 2). Eight lymphograms showed that the contrast medium proceeded from the lymphatic vessels of the shin, at a distance of 6—8 cm below the level of the popliteal lymph node, into the saphenous vein and the popliteal one (Fig. 3, 4). In none of these lymphograms could a distinct picture of the anatomical lymphatico-venous communication be demonstrated.

DISCUSSION

Direct communications between the lymphatic vessels and veins are not limited to the well known ones between the terminal segment of the thoracic duct and the left subclavian vein, or to that between the right thoracic duct and the right subclavian vein. Accessory communications, connecting peripheral lymphatic vessels with the veins were reported to be found in healthy humans (1, 14). Such accessory communications were found mainly between cisternae chyli and the inferior vena cava. Similar communications were encountered in anthropoid monkeys and other mammals (5, 8). Following ligation of the thoracic duct in a dog, the lymph outflow may be effected through newly developed or already previously existing communications between the thoracic duct and the azygos vein, between the cisterna chyli and the inferior vena cava and between iliac lymphatic vessels and vertebral veins (2). Also lymphatico-venous communications between the lumen of the lymphatic vessels and their *vasa vasorum* were found to exist (16). In edematous conditions due to neoplastic occlusion of lymphatic vessels and metastases to the pelvic as well as to the axillar lymph nodes, an outflow of a certain amount of lymph is effected through the connections existing between peripheral extremital lymphatic vessels and veins (3, 12).

Another point, where the lymph or at least part of its components may proceed into the systemic circulation, are the lymph nodes. It was demonstrated

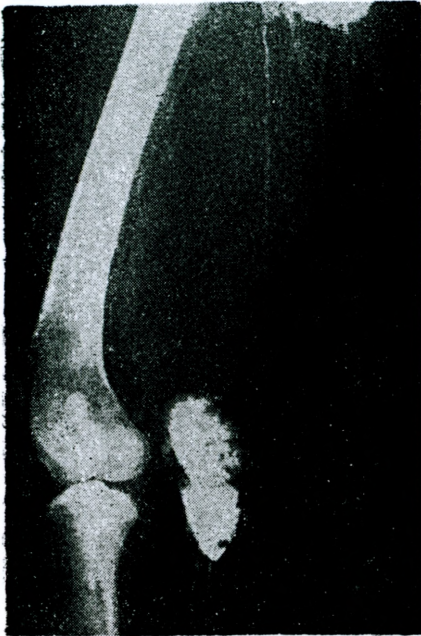

Fig. 1

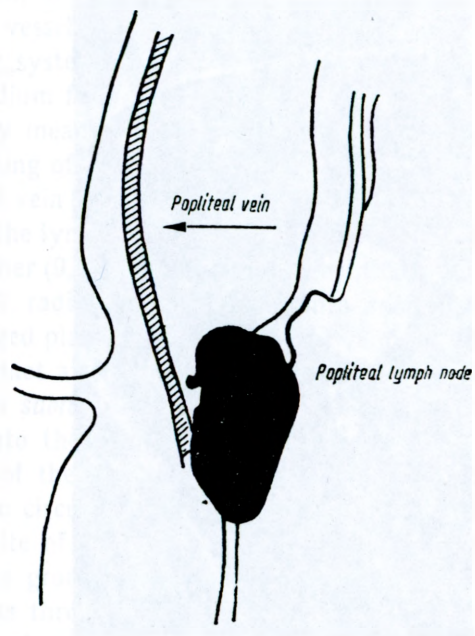


Fig. 1a

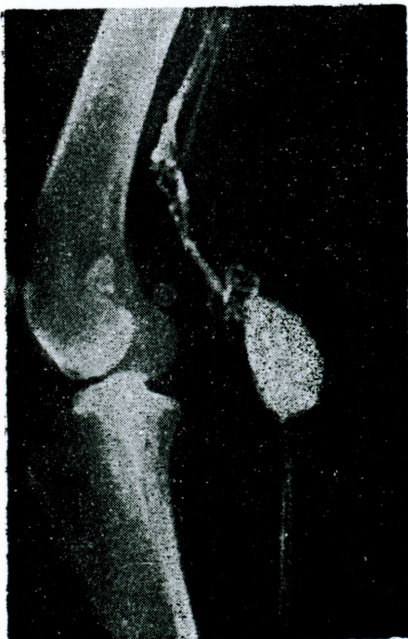

Fig. 2

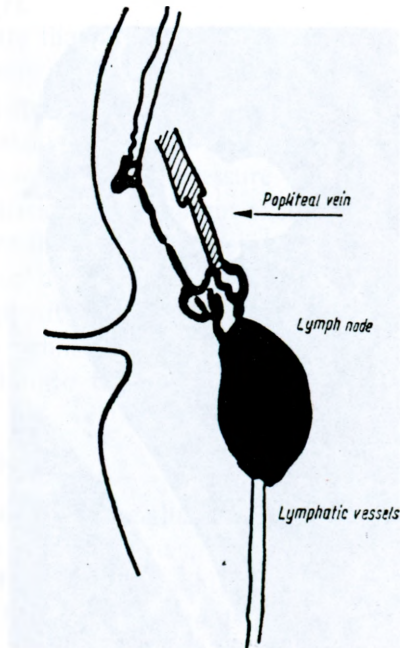


Fig. 2a

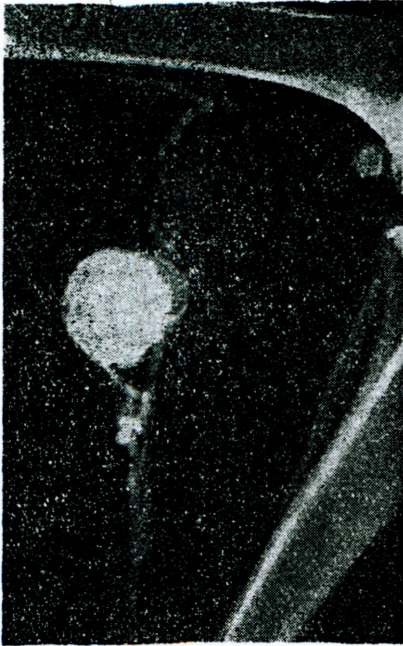

Fig. 3

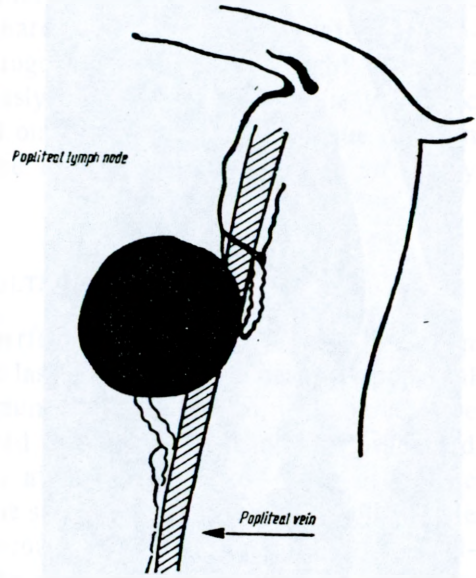


Fig. 3a

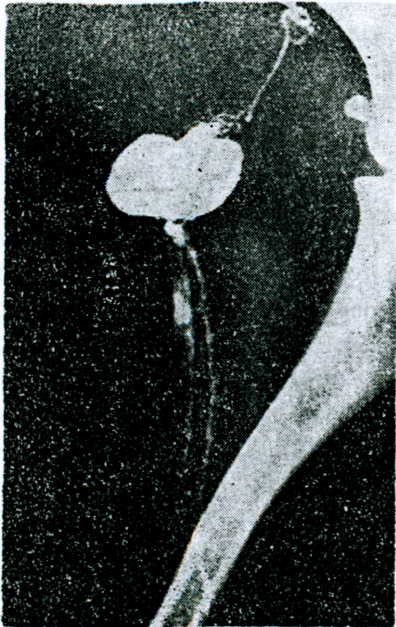


Fig. 4

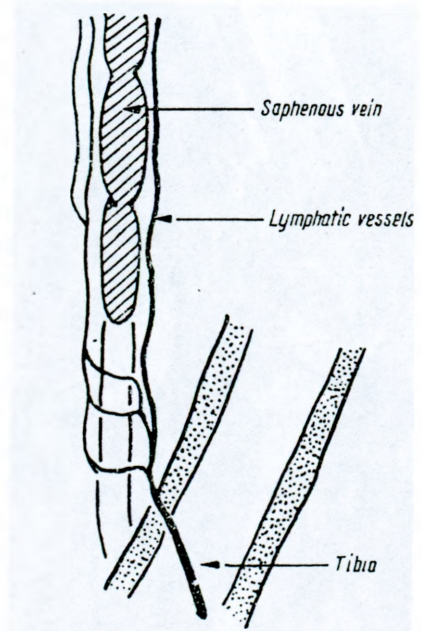


Fig. 4a

that a 13 volume percent of a solution of paraaminohippuric acid (molecular weight 200) injected into an afferent vessel proceeded within the lymph node into the capillaries of the circulatory system (11).

Passing of an aqueous contrast medium from the popliteal lymph node into the popliteal vein was also proved by means of lymphography performed on dogs (4). The phenomenon of the passing of an oily contrast medium from the popliteal lymph node into the popliteal vein was observed at cinelymphography. The rapid passing of air injected into the lymph nodes of rats and dogs into the lumen of a regional vein was noted, either (9, 14). Another experiment consisting of an injection of plasma labeled with radioactive iodine ^{131}I into an afferent vessel resulted in the passing such tagged plasma into the regional vein (10, 15). This passing of plasma was more distinct after ligation of the afferent vessels. Also microorganisms, such as *Bacillus subtilis* measuring $1\ \mu$ in diameter and $6\ \mu$ in length, passed very rapidly into the vein.

Both the mechanism and the site of the anatomical passing of the lymph from a lymph node into the systemic circulation are not explained yet. The assumption that the most probable site of lymph transfer or passing are the "pores" in the capillaries seems to be grounded (10). Molecules of molecular weight not exceeding 22,000 may pass through the pores under physiological conditions. Besides pores, there exist also "capillary slits" (6) through which molecules of a molecular weight of up to 300,000 may penetrate. If the vascular wall is distended the pores also dilate, thus permitting the penetration of molecules of molecular weight of 412,000 (7).

Radiograms presented in this paper indicate that in a healthy animal a contrast medium of the molecular weight of 809 may pass from the lymphatic vessels of the shin and lymphatic sinuses of the popliteal lymph node into the extremal veins. The anatomical site of the passing of the contrast medium into the vein could not be made distinctly visualized. The pressure exerted on injecting the contrast medium into the lymphatic vessels did not exceed physiologic values and was lower than the pressure during active movements of the extremity. Lymphography was carried out on dead animals, because the considerable velocity of blood flow through the popliteal vein in live animals makes impossible to render radiologically visible the inconsiderable amounts of contrast medium, passing from the lymphatic vessels into the vein.

CONCLUSIONS

1. An aqueous contrast medium of a molecular weight of 809 may pass, in healthy dog, from the lymphatic vessels into the veins.
2. The passing of the contrast medium from the lymphatic vessels of the shin into the nearest regional vein as well as from the popliteal lymph node into the popliteal vein was shown.

3. The anatomical site of the connection between the lymphatic circulation and the venous one, could not be made visible.

Translated by M. Schmidt, M. D.

REFERENCES

1. *Bartels, P.*: Das Lymphgefäßsystem. Handbuch der Anatomie des Menschen. G. Fischer, Jena 1909.
2. *Belan, A., Malek, P., Kolc, J.*: Roentgenkinematographischer Nachweis lymphovenöser Verbindungen im *in vivo*.
3. *Blalock, A., Robinson, C. S., Cunningham, R. S., Gray, M. E.*: Experimental studies on lymphatic blockage. Arch. Surg., 1937, 34, 1049.
4. *Chavez, C. M., Berrong, L. G., Evers, C. G.*: Hepatic oil embolism after lymphangiography. Amer. J. Surg., 1965, 110, 456.
5. *Danese, C., Howard, J. M., Bower, R.*: Aberrant venolymphatic communication noted in a dog. J. Surg. Res., 1962, 2, 317.
6. *Freeman, L. W.*: Lymphatic pathways from the intestine in dog. Anat. Rec., 1962, 82, 543.
7. *Grotte, G.*: Passage of dextran molecules across the blood-lymph barrier. Acta Chirur. Scand., 1965, Suppl. 211, 1.
8. *Mayerson, H. S.*: Observations and reflections on the lymphatic system. Tr. Coll. Physicians, Philadelphia 1961, 28, 109.
9. *McClure, Ch. F., Silvester, Ch. F.*: A comparative study of the lymphatico-venous communications in adult mammals. Anat. Rec., 1909, 3, 534.
10. *Pressman, J. J., Simon, B. M.*: Experimental evidence of direct communication between the lymph nodes and veins. Surg. Gyn. Obst., 1961, 113, 537.
11. *Pressman, J. J., Burtz, M. V., Shafer, L.*: Further observation related to direct communications between lymph nodes and veins. Surg. Gyn. Obst., 1964, 119, 984.
12. *Rusznay, J.*: Lymphatics et lymph circulation. Pergamon Press, London 1960.
13. *Shanbrom, E., Zheullin, N.*: Radiographic studies of the lymphatic system. Arch. Int. Med., 1959, 104, 589.
14. *Silvester, C. F.*: On the presence of permanent communications between the lymphatic and the venous systems at the level of the renal veins in adult South American monkeys. Am. J. Anat., 1912, 12, 447.
15. *Threefoot, S. A., Kent, W. T., Chatchett, B. F.*: Lymphatico-venous and lymphatico-lymphatic communications demonstrated by plastic corrosion models of rats and by post mortem lymphangiography in man. J. Lab. Clin. Med., 1963, 61, 9.
16. *Threefoot, S.*: Radioisotope desection of lymphatico-venous communications in living animals. J. Lab. et Clin. Med., 1965, 65, 688.
17. *Zerbino, D. D.*: Tezy Czerniowickiego Instytutu Medycznego (Theses of the Medical Institute of Czerniowce). 1964, U.S.S.R.