

## **Experimental lymphedema in dogs**

W. OLSZEWSKI, *M.D.*, Z. MACHOWSKI, *M.D.*, J. SOKOLOWSKI, *M.D.*,  
and J. NIELUBOWICZ, *M.D.*

(from the Surgical Research Laboratory, Polish Academy of Sciences,  
Warsaw, Poland)

Experimental lymphedema in dogs

**THE JOURNAL OF CARDIOVASCULAR SURGERY**

---

Vol. 9 - No. 2 - pp. 173-183 (March-April 1968)

<http://rcin.org.pl>

W. OLSZĘWSKI, M.D., Z. MACHOWSKI, M.D., J. SOKOLOWSKI, M.D.,  
and J. NIELUBOWICZ, M.D.

(from the Surgical Research Laboratory, Polish Academy of Sciences,  
Warsaw, Poland)

---

# Experimental lymphedema in dogs

The aim of this study was to develop a method for the production of permanent lymphedema in hind limbs of dogs. Our previous experiments demonstrated that simple transection of the lymphatics of the thigh does not produce long-lasting edema. It causes only transient pitting edema which usually disappears within 8-10 weeks when the interrupted lymph flow is restored through regenerated lymph vessels or capillaries. After many experiments and tests we found that a block of the lymph flow and a long-lasting resistant lymphedema may be obtained if in addition to transection of the lymphatics a circular strip of skin, subcutaneous tissue, fascia and periosteum is removed from the thigh and a gap is left for secondary healing by granulation. In due time a firm scar develops closing the network of capillaries which usually restore the lymph flow. Consequently, a few months after the experiment a permanent lymphedema of the elephantiac type develops.

#### MATERIAL AND METHODS

Twenty five mongrel dogs with an average weight of 16 kg. were used for experiments. Under Eunarcon anesthesia a 2 cm. wide circular strip of skin and subcutaneous tissue was excised from the

upper part of the thigh (Fig. 1). After careful hemostasis the fascia was incised all around but the muscles were left intact. Then 4 cm. of femoral lymphatics with connective tissue surrounding the femoral neurovascular bundle were resected. The periosteum of the femur was incised circularly and stripped off for 1 cm. The margins of the skin were sutured to the muscles and a gap was left for gra-

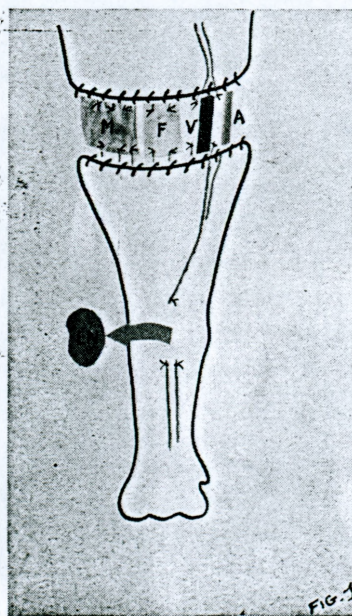


Fig. 1.—The technique used for the production of experimental lymphedema. A circular strip of skin, subcutaneous tissue, fascia, periosteum, together with a 4 cm.-long segment of femoral lymph vessels and popliteal lymph node have been removed. The margins of skin are sutured to the muscles and a gap is left between them for granulation. M = muscle, F = femur, A, V = artery and vein, LN = popliteal lymph node.

Paper presented at the 8th Congress of the International Society of Cardiovascular Surgery, Vienna, September 7-9, 1967.



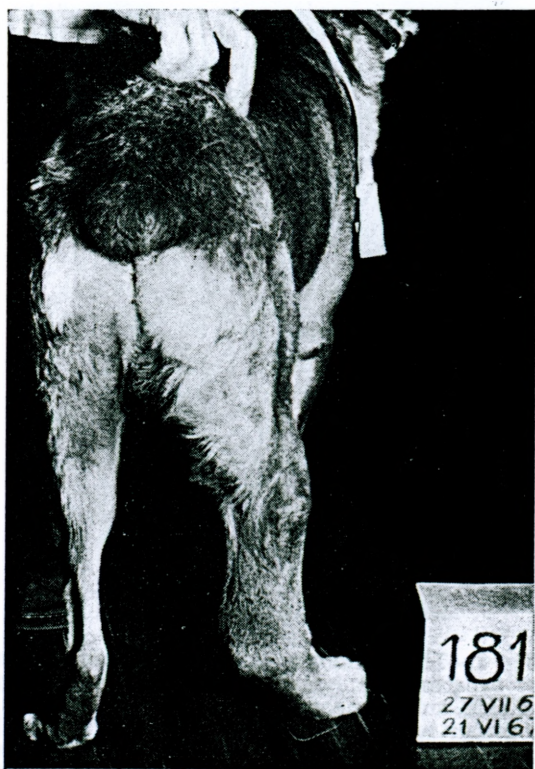
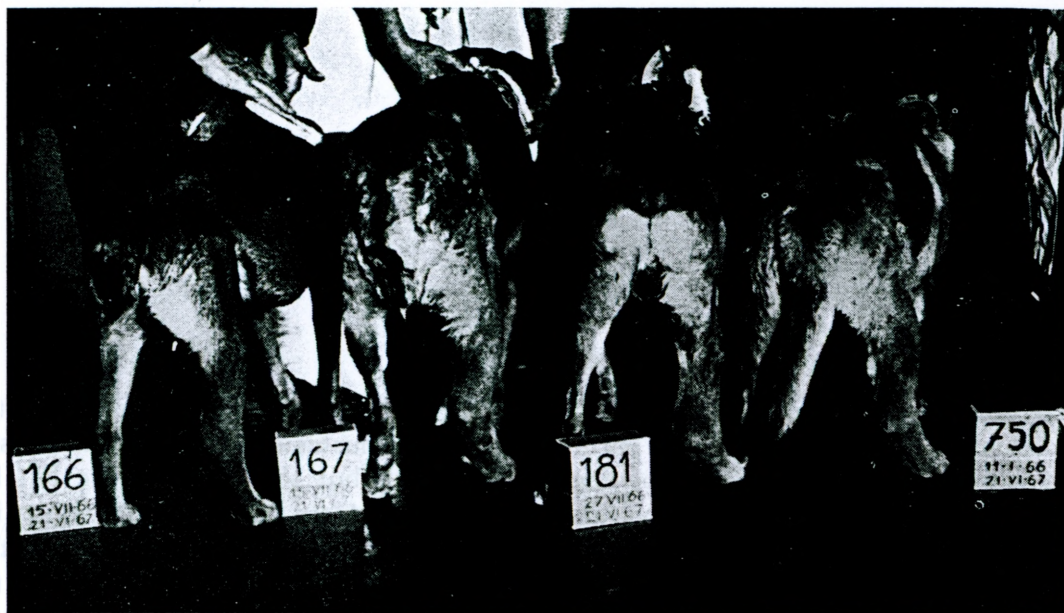
Fig. 2.—Lymphedema of the right hind limb 11 months after the operation,



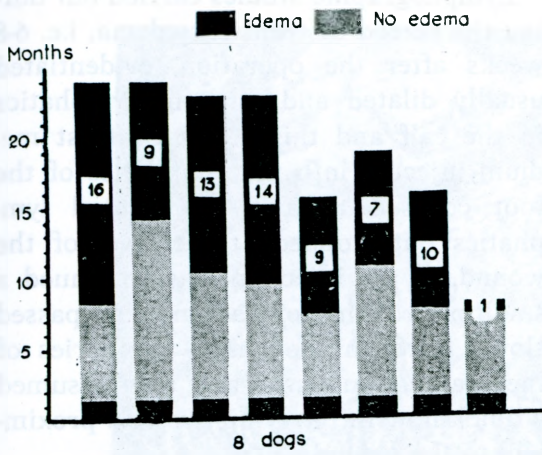


Fig. 3.—Follow-up periods of 8 dogs with permanent lymphedema.

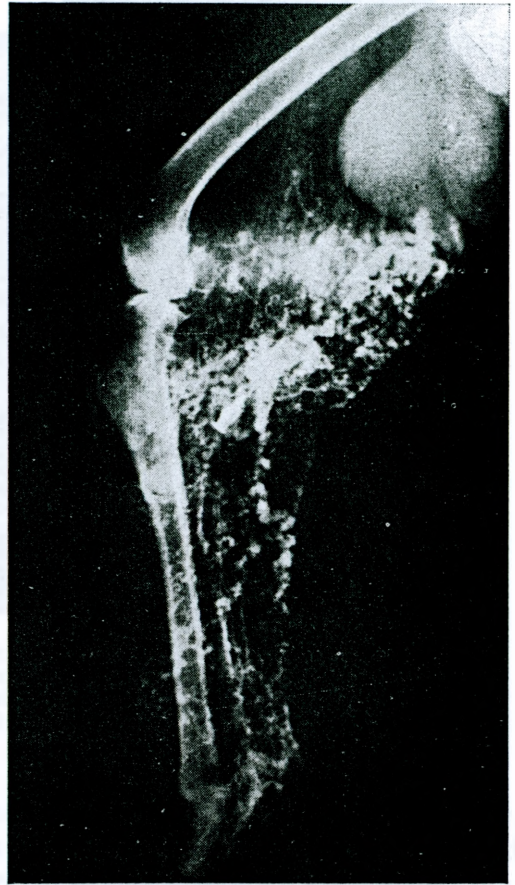


Fig. 5.—Lymphogram of a dog with permanent lymphedema 12 months after the operation. A network of dilated and tortuous lymph vessels with incompetent valves and dermal backflow.

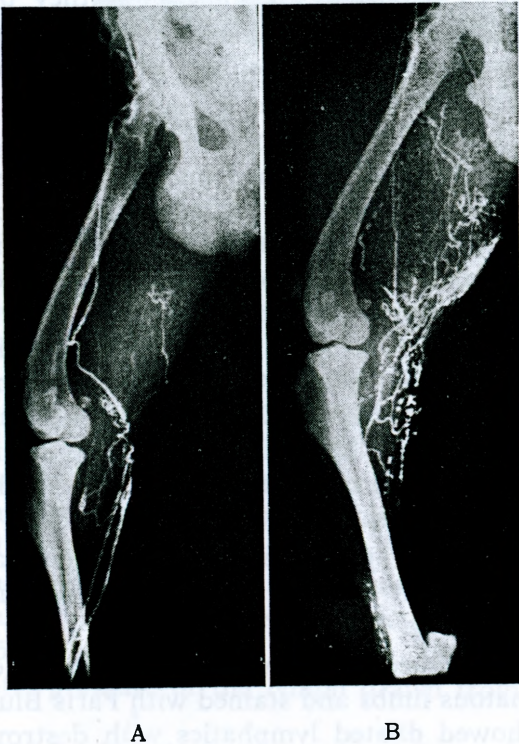


Fig. 4 A, B.—Two lymphograms performed in the same limb at 5 months interval. Clinically no edema, radiologically increasing signs of lymph stasis.

nulation. An antiseptic dressing was put on the wound and antibiotic therapy was initiated. The popliteal lymph node was removed through a separate incision. During the follow-up period the circum-

ference of the operated and control limbs was measured every month. Lymphographic and phlebographic studies were carried out at three months intervals. When permanent edema developed, the volume of the edematous and control limbs was measured by the water displacement technique. In all cases cinelympho- and phlebography were performed, lymph was drawn for biochemical studies and a skin biopsy was performed for histologic examinations. One of the dogs with long-lasting lymphedema was sacrificed, the lymphatics were filled with 1 per cent Paris Blue Solution and preserved in methylsalicylate for stereomicroscopic examination.



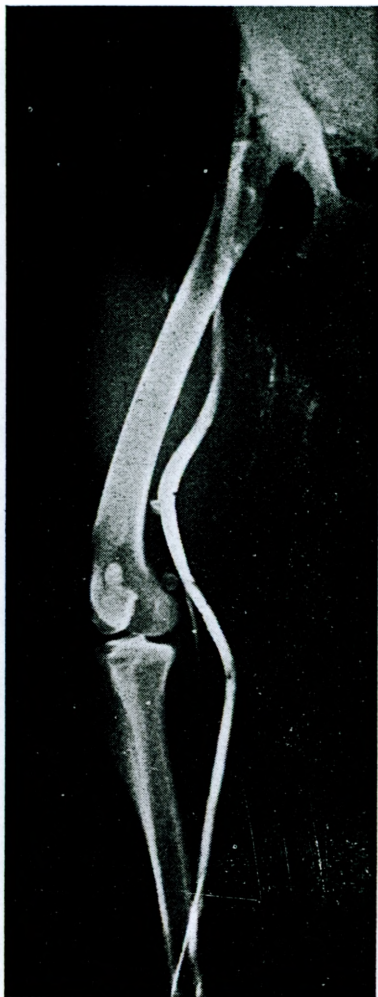

Fig. 6.—Phlebography in the same case as in Fig. 5. Patent popliteal and femoral veins.

### RESULTS

Of the 23 dogs which were followed up for a period of 12 months, 8 (35 per cent) developed permanent lymphedema. Postoperatively all animals developed transient inflammatory edema which subsided in all cases within 6-8 weeks. In 8 of 23 dogs the edema reappeared seven to ten months later in form of permanent lymphedema of the elephantiac type (Fig. 2). This edema did not disappear subsequently and the duration of follow-up from its onset until to-day has been 14, 13, 10, 9, 9, 7, 1 months and in the oldest case 16 months (Fig. 3).

Lymphographic studies carried out during the period of transient edema, i.e. 6-8 weeks after the operation, evidenced usually dilated and tortuous lymphatics in the calf and thigh. The contrast medium injected into the lymphatics of the foot coursed through the dilated lymphatics but stopped at the level of the wound. If the injection was continued a small part of the contrast medium passed slowly through the lymph capillaries of the granulation tissue and then resumed a quick flow in the lymph vessels proximally to the wound.

After the transient inflammatory edema subsided the radiological signs of lymph stasis persisted. In some dogs they became even more prominent although there was no swelling of the limb (Fig. 4 A, B).

Lymphography performed at the stage of permanent lymphedema demonstrated a dense system of dilated and tortuous lymphatics of a diameter of up to 5 mm., complete valve incompetency and retrograde filling of cutaneous lymphatics. Two to three small anastomosing channels could be seen passing through the scar in the thigh. X-rays taken 24 hours later evidenced almost complete stasis of the contrast medium in the lymphatics of the foot and calf (Fig. 5).

Phlebography showed patent femoral veins with competent valves in all animals (Fig. 6).

The specimens taken from lymphedematous limbs and stained with Paris Blue showed dilated lymphatics with destroyed valves in the skin, subcutaneous tissue, fascia, periosteum, in the perivascular spaces along the main blood vessels and even along the arteries and veins supplying the muscles.

Histologic studies showed marked fibrosis of the thickened skin and subcutaneous tissue, the individual fibers being separated by edema fluid. Numerous di-



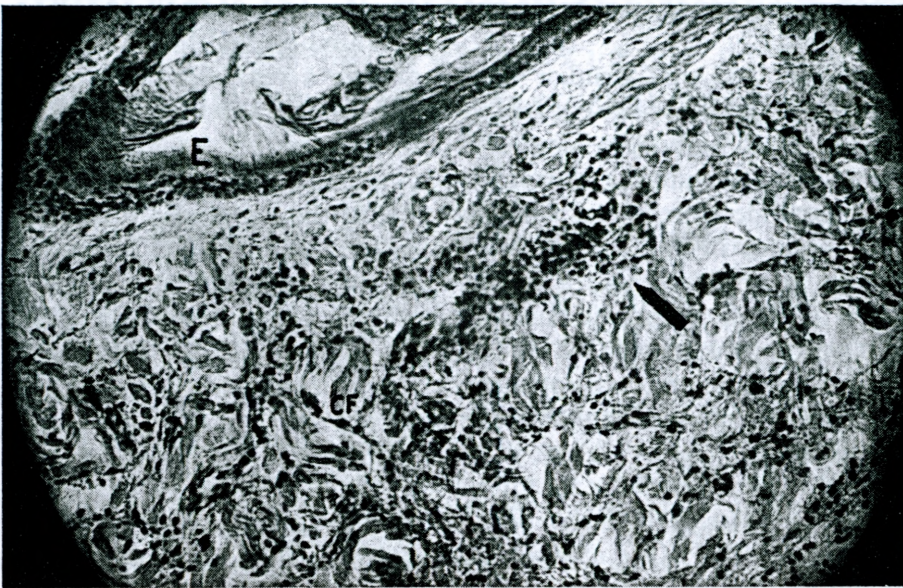

Fig. 7.—Microscopic specimen of skin from lymphedematous limb. Hyperkeratosis of epithelium and marked fibrosis of skin, the fibers are separated by fluid. E = epithelium, CF = collagen fibers, arrow shows collection of lymphocytes.

lated lymphatics, particularly in the skin, were lined with a single layer of endothelium and surrounded by collections of lymphocytes (Fig. 7).

As edema developed lymph could be readily obtained for analysis by puncture of cutaneous lymphatics. The protein content of the lymph of the edematous limb amounted to 1.55 g./per cent as compared to 1.46 per cent in the control limb and 6.91 per cent in the serum. The albumin level amounted respectively to 0.62, 0.54 and 2.69 g./per cent. The oncotic pressure of the lymph drawn from

the edematous limbs was 3.9 cm. of water, as predicted from the Wells formula,<sup>3</sup> and 3.6 cm. in the control limbs. Table 1 illustrates the chemical composition of lymph and serum in 8 dogs. The paper electrophoresis of lymph and serum did not show any specific differences in protein contents of lymph obtained from edematous and control limbs and serum.

#### DISCUSSION

Efforts to produce permanent lymphedema of the limbs with elephantiac changes in animals have a long history of failure. In mammals it is difficult to produce a complete block of the lymphatic return to the bloodstream because of many accessory anastomotic channels and lympho-venous communications. Section of the lymphatics blocks the lymph return temporarily and causes transient edema. In the dogs in which all soft tissues were excised except the artery, vein and nerve, transient edema occurred but

TABLE 1.—Average protein content and oncotic pressure of lymph and serum.

	Lymph from lymphedematous limb	Lymph from control limb	Serum
Total protein	1.55 g.% (1.13-2.5)	1.46 g.% (0.7-2.61)	6.91 g.% (6.43-7.9)
Albumin	0.62 g.% (40%)	0.54 g.% (37%)	2.69 g.% (39%)
Oncotic pressure (Wells'/formula)	3.9 cm. of water	3.6 cm. of water	25.7 cm. of water



subsided when the lymphatics regenerated in the wound.<sup>2</sup>

It was only in 1934 that Drinker<sup>1</sup> produced for the first time permanent lymphedema in the hind limb of a dog with repeated injections of quinine hydrochloride and crystalline silicon suspensions into the lymphatics of the leg. The condition eventually produced was a typical lymphedema with elephantiac changes in the skin and subcutaneous tissue.

Working for some years on the problem of lymph stasis we have learned that the main femoral lymph vessels do not regenerate beyond a gap of 3-5 cm. and that the lymphatic capillaries undergo occlusion in the granulation tissue at the time of wound contraction and scar formation. These two facts suggested that wide excision of the femoral lymph vessels and simultaneous production of a circular strip of granulation tissue that undergoes fibrosis, will cause a definite block of the lymph flow.

This idea was tested experimentally. As a result permanent lymphedema was

produced in 8 of the 23 dogs that were operated on and followed up for a period of over a year. Permanent edema appeared usually 7-10 months after operation. In these cases typical radiological signs of lymph stasis with dilatation and tortuosity of the lymphatic vessels, valve incompetence and dermal backflow were seen on lymphography. Histologic examination of the skin and subcutaneous tissue evidenced typical elephantiac changes.

This research is still in progress and we are investigating the pathogenesis of lymphedema, the mechanism of filtration of various substances from the blood into the interstitial fluid and lymph, the biochemical changes of stagnant lymph and the histology of lymphedematous tissue.

#### REFERENCES

1. Drinker C. K., Field M. E., Thomas J.: « The experimental production of edema and elephantiasis as a result of lymphatic obstruction ». *Amer. J. Physiol.*, 108, 509, 1934.
2. Reichert F. L.: « The regeneration of lymphatics ». *Arch. Surg.*, 13, 871, 1926.
3. Wells H. S., Youmans J. B., Miller D. G.: *J. Clin. Invest.*, 12, 1103, 1933.