

## 1. DONAU-SYMPOSIUM FÜR NEUROPATHOLOGIE

abgehalten unter den Auspizien  
der World Federation of Neurology

veranstaltet von der Österreichischen Arbeitsgemeinschaft für Neuropathologie  
unter Mitwirkung der Wiener Medizinischen Akademie

Wien, am 7. Mai 1969

# SEPARATUM



Verlag der Wiener Medizinischen Akademie

THE BLOOD-BRAIN BARRIER ABNORMALITY  
IN EXPERIMENTAL HEPATIC ENCEPHALOPATHY <sup>1)</sup>

M. J. MOSSAKOWSKI, M. ŚMIAZEK, A. PRONASZKO

Experimental and Clinical Medical Research  
Centre of Polish Academy of Sciences, Warsaw, Poland

In our previous study on hepatogenic encephalopathy (MOSSAKOWSKI, 1966 a, 1966 b) we suggested the possibility that the blood-brain barrier abnormality connected with diffuse and severe glial changes, might play an important role in the formation of cerebral tissue lesions in this condition.

The purpose of the present study was to prove experimentally our previous suggestions.

Materials and Methods

The experiments were carried out with 30 albino rats of both sexes, aged 2 months at the beginning of the experiment, in which liver cirrhosis was being induced by subcutaneous injections of carbon tetrachloride in liquid paraffin in the amount of 0,1 ml per 100 g of body weight. Twenty one control animals were subcutaneously injected with liquid paraffin in the above mentioned amount. Both groups of animals received a 1,5 per cent solution of silver nitrate to drink for 7 months according to the technique described by WISLOCKI and LEDUC (1952).

The animals were sacrificed in groups 2, 4 and 6 months after beginning the carbon tetrachloride injections. Each group consisted of 10 experimental and 7 control animals. In addition 3 experimental and 2 control animals of each group received intravenous injections of 2 per cent Evans blue solution in 7 per cent bovine albumin 2 hours prior to sacrifice.

Brain tissue from various regions and liver were studied under dark-field microscopy for permeability changes indicated by the presence of silver deposits in the brain parenchyma. Formalin-fixed, frozen sections of brain, from animals which received Evans blue solution intravitally, were studied under a fluorescence microscope.

Results

No abnormality, except grayish discoloration of body organs and dura matter was found in the control animals. Also at the microscopic level both brain and liver showed no pathological changes. Silver deposits in the brain were limited to the blood vessel walls, stroma of choroid plexus and leptomeninges. The only parenchymal deposits were present in the area postrema, infundibulum and pineal body.

In animals sacrificed after 2 months of experiment only severe fatty degeneration of hepatocytes, without connective tissue proliferation was found. The brain tissue in animals of this group showed slight glial proliferation with single Alzheimer type II cells. No abnormalities were revealed under dark field

<sup>1)</sup> The work was supported by NIH Grant PL 480. Agreement 227704

microscopy.

In the two remaining groups of experimental animals, the liver of those sacrificed after 4 and 6 months of experiment showed typical cirrhotic changes (Fig. 1). Cerebral changes in these animals were typical for hepatogenic encephalopathy. The fundamental pattern of changes was identical in both groups despite slight quantitative differences concerning the intensity of changes. The most striking feature was generalized proliferation and hypertrophy of astrocytes, concomitant with their severe degeneration and leading to breakdown of their processes (Clasmatodendrosis).

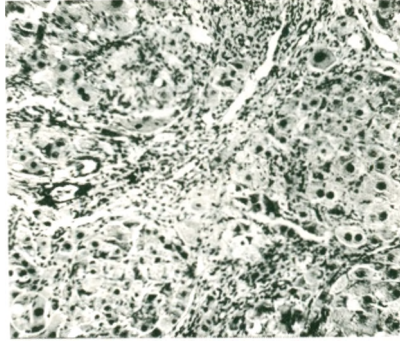


Fig. 1  
Typical picture of experimental liver  
cirrhosis, H-E, x 200

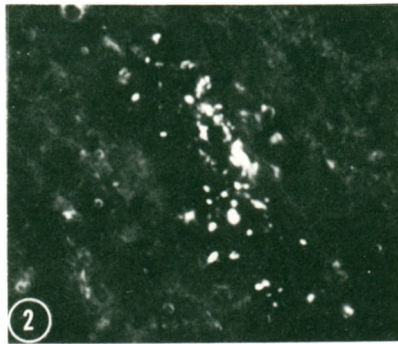


Fig. 2  
Neuropil silver deposits around cortical  
blood vessel. Dark field microscopy, x 200

In all gray structures Alzheimer type II cells, and so-called transitory cells were present. In two animals small foci of spongy degeneration were noted. Numerous neurons in all gray formations showed nonspecific degeneration. Blood vessels were normal.

Under dark field microscopy silver deposits in typical regions of the brain were more abundant than in control animals. Fine granular silver deposits were seen in cortical neuropil and in other gray formations. The strongest aggregations occurred in the vicinity of blood vessels (Fig. 2). Numerous glial cells, mostly astrocytes were filled with silver granules (Fig. 3). The greatest number of silver-bearing astrocytes was typical for paraventricular and subpial areas of the brain and brain stem, as well as for corpus callosum and fornix.

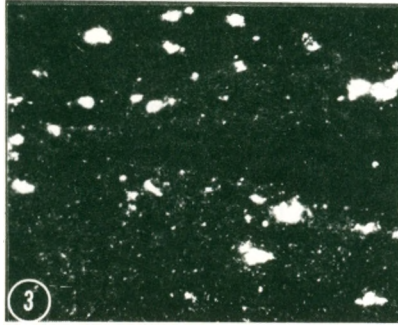


Fig. 3  
Silver-bearing astrocytes in subependymal region of the III ventricle. Dark field microscopy. x 300

Neurons of basal ganglia, nuclei pontis (Fig. 4) Ammon's horn and to a lesser degree Purkinje cells contained intracytoplasmic silver granules.

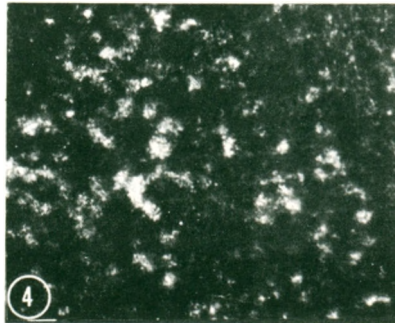


Fig. 4  
Most neurons and glial cells of nuclei pontis filled with silver granules. Dark field microscopy. x 200

Extravascular penetration of Evans blue-albumin was found in no group of experimental animals.

## Discussion

Experimentally induced with carbon tetrachloride liver cirrhosis leads to the development of a typical picture of hepatogenic encephalopathy. Slight in their intensity morphological changes of brain tissue were already present in animals sacrificed after 2 months of experiment. The liver abnormalities then consisted only of fatty degeneration.

Gliopathic changes are accompanied by increased permeability of the blood-brain barrier for silver salt, which appear in the parenchymal elements of the brain, such as neuropil, astrocytes and some neurons, while in cases with no abnormalities in the blood-brain barrier system, silver deposits are limited strictly to those areas of brain which lack any barrier systems, this being true both for experimental conditions (WISLOCKI and LEDUC, 1952) and human pathology (HILL and PITTSBURY, 1939).

It seems, however, that we are dealing with a selective blood-brain barrier injury, as the same animals did not show permeability changes for albumin labelled with Evans blue. This type of permeability changes can possibly play an important role in human pathology, as they can expose brain tissue to the noxious influence of some barrier substances circulating in the blood, for instance to the activity of copper, the level of which increases in the blood serum in cases of liver cirrhosis (HOLMBERG and LAURELL, 1954; MOSSAKOWSKI et al, 1970).

In our experiments glial pathology proceeded the occurrence of blood-brain barrier disturbances. The former was present already in animals sacrificed 2 months after experimental treatment, while blood-brain barrier abnormalities appeared only when fully developed liver cirrhosis and hepatogenic encephalopathy were encountered. This might indicate the role of glial injury in blood-brain barrier disturbances in the case of hepatogenic encephalopathy.

## Literature

- HOLMBERG, C. G. and C. B. LAURELL: *Scand. J. Clin. Lab. Invest.* 3, 103 (1951)  
 HILL, W. R. and D. M. PITTSBURY: *Argyria the pharmacology of silver.* Williams and Wilkins, Baltimore 172 (1939)  
 MOSSAKOWSKI, M. J. : *Proc. of V. Internat. Congress of Neuropath.* Zurich 1965, Exc. Med. Found. Amsterdam ( 1966 a)  
 MOSSAKOWSKI, M. J. : *Neuropat. Polska.* 4, 231 (1966 b)  
 MOSSAKOWSKI, M. J. , K. RENKAWEK, Z. KRAŚNICKA, M. ŚMIALEK and A. PRONASZKO: *Acta Neuropath.* Berlin, 16, 1 (1970)  
 WISLOCKI, G. B. and E. H. LEDUC: *J. Comp. Neurol.* 96, 371 (1952)

All rights reserved  
by Verlag der Wiener Medizinischen Akademie, 1971

Alser Straße 4 A-1090 Wien IX

Printed by H. Egermann, Wien 17