

INTRAVASCULAR IMAGING

N. BOM^{a, b, *}, W. LI^{a, b}, A.F.W. VAN DER STEEN^{a, b}, C.T. LANCÉE^a,
E.I. CÉSPEDES^{a, c}, C.J.SLAGER^a, C.L. DE KORTE^a, N. DE JONG^a

^a Thoraxcentre, Erasmus University Rotterdam and University Hospital Rotterdam-Dijkzigt,
P.O. Box 1738, 3000 DR Rotterdam, The Netherlands

^b Interuniversity Cardiology Institute of the Netherlands, 3000 DR Rotterdam,
The Netherlands

^c EndoSonics, 3000 DR Rotterdam, The Netherlands

Abstract – Based on three-dimensional (3D) information, quantitative data such as plaque volume can be calculated. The procedure includes automatic contour detection based on image segmentation methods and greatly speeds up clinical evaluation. With the use of additional X-ray information, the true tortuous vessel geometry can be reconstructed in 3D. This allows, by numerical modelling techniques, to calculate endothelial shear stress values which in turn may indicate sites prone to stenosis. With a decorrelation technique for radio frequency (RF) echo information from sequential data in the same beam direction and integration method over the entire cross section, blood velocity can be shown colour-coded during the cardiac cycle, while even blood flow quantification seems to be possible. In vitro as well as animal experiments have shown the feasibility of the method.

Intravascular imaging can be used to study the biomechanical properties of atheroma components. Local radial strain as a measure of local tissue hardness can be estimated in principle. Hard or soft plaques can be identified from the strain images independently of the echogenic contrast between plaque and vessel wall.

Keywords: Intravascular 3D imaging; True 3D reconstruction; Shear stress; Blood velocity; Blood flow quantification; Elastography; Tissue identification

1. Introduction

Intravascular ultrasound (IVUS) is a technique to electronically survey arteries from within the lumen. Cross-sectional imaging of a vessel is generated by sweeping the ultrasound beam sequentially in a 360° scan angle. Early approaches have been described for the mechanical rotation by Wells in 1966 [1] and for the electronic beam rotation by Born in 1972 [2]. Although the latter system was developed for intracardiac use, application in arteries was suggested as well. These principles are still used in current systems and are illustrated in Fig. 1. In mechanical systems the imaging is created by rotating a single transducer element (or mirror) with a flexible shaft. A study on mechanical drive shafts has been documented by ten Hoff in 1993 [3]. The electronic method is based on mounting a large number of small acoustic elements cylindrically at the circumference of a catheter tip. Due to improvements in

resolution, data processing and transducer technology, image quality has improved dramatically over the years. An excellent survey of practical use of IVUS imaging is documented by Tobis and Yock [4]. Two new directions of development are the further miniaturisation towards imaging guide wires and the forward looking catheters.

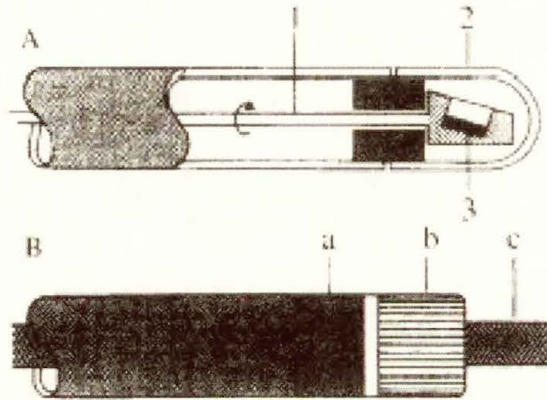


Fig. 1. (A) Mechanical rotating single-element catheter tip consisting of rotating shaft (1); transparent dome (2); transducer element (3). (B) Electronically switched phased array catheter tip consisting of integrated circuitry for reduction of the number of wires (a); multi-element transducer (b); guide wire (c).

A practical use for the imaging guide wires is the combination with balloon catheters. It would thus become visible what the result of a balloon dilatation is during the procedure. These systems are to be used inside the protective (balloon) catheter. The proposed systems so far range from an imaging core with large connector to a true imaging guide wire [5]. A large connector prevents the easy exchange between balloon catheters with different diameter as is often required during an intervention procedure. The true ultrasound imaging guide wire can be described as a stationary housing with an imaging core inside and a very small connector. Early results confirm the feasibility of the use of an ultrasonic guide wire for monitoring balloon expansion for instance during stent implantation.

All commercial intravascular catheters are side looking devices designed to look at the layered structures of the arterial walls. A forward looking catheter would be required in the situation of total or near total occlusion. Mechanical [6] as well as phased array forward looking catheters have already been described. However, most of the recent research is aimed at new ways to look at the present ultrasound data, from construction of 3D images based on ultrasonic slices to quantitative measurement and derivation of volume flow and elastographic parameters from the radio frequency signals. These will be briefly described in the following sections.

2. Three-dimensional imaging

IVUS is a real-time tomographic imaging technique that displays the cross-sectional arterial lumen and wall components at different vessel positions in a sequential fashion by moving the scanning catheter tip. Although the experienced mind is capable of 3D conceptualization of complex structural morphology and pathology from the sequential display, a thorough understanding of the spatial relations of this information requires repeated review of the images. Computerised 3D reconstruction is based on acquisition of serial cross-sectional slice information. Computerised 3D reconstruction allows visualisation of these tomographic data in their longitudinal relation to the proximal and distal segments and provides a more objective spatial picture [7]. It is the potential gateway to quantification of, for instance, plaque volume. In recent years several methods have been developed to acquire tomographic IVUS data sets for 3D reconstruction:

- (1) Manual pull-back of the catheter.
- (2) Manual pull-back with displacement sensor.
- (3) Uniform velocity motorised pull-back.
- (4) Uniform velocity motorised pull-back with ECG-labelling.
- (5) ECG-gated motorised pull-back with steppingmotor.

The ECG labelling or ECG-gated acquisition is used to remove the artefacts that occur due to motion of the arterial walls. An example of a displacement sensor and the principle of echo catheter pull-back is illustrated in Fig. 2 [8].

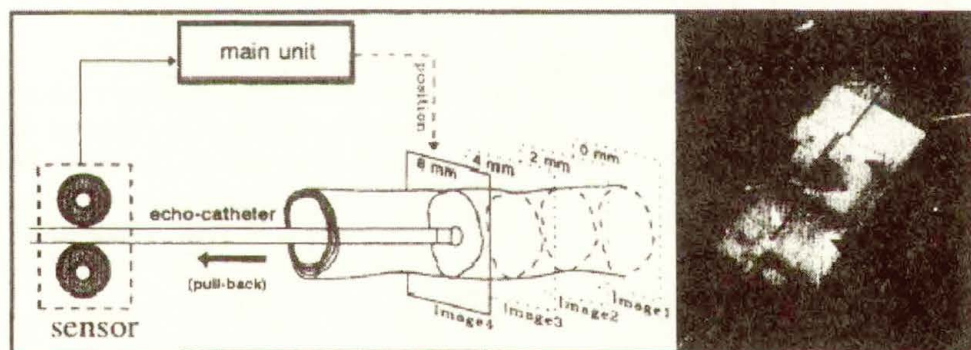


Fig. 2. Left: diagram illustrating a pull-back acquisition to obtain a set of IVUS cross-sectional images using the displacement sensing device. The motion of the catheter is detected by the sensor and superimposed on the video display. Right: Photograph of the displacement sensing device: 1, disposable sensor; 2, main unit; 3, catheter.

During the post-processing the digitized images are formatted in the correct sequence to their ECG phase in volumetric data sets. A grey level range can be used to separate background and blood pool echoes from wall structures in each cross-section. Volume rendering techniques are then applied for 3D reconstruction. Dynamic display can for instance be carried out in a time-loop format.

For quantification the image segmentation to define specific regions can be carried out with semi-automatic contour analyses based on minimum-cost algorithms. In an example of quantification based on 3D information, first two longitudinal perpendicular planes are interactively selected. In a second step, the contours in these longitudinal planes, which are based on many slices, are calculated. This in turn serves as a start point for the same procedure in each cross-sectional plane. As a result the volumetric information on plaque and open lumen over the entire narrowed arterial segment becomes available.

In the procedures described so far the reconstructed artery is displayed 'as a straight tube'. This is obviously an oversimplification of the true tortuous anatomy. With the use of additional X-ray biplane image information, the true spatially curved course of the vessel in 3D space can be derived. Fusion of the 3D path and the lumen contours is a necessary step. Correct spatial reconstruction includes:

- (1) The vessel wall itself must be reconstructed rather than the lumen.
- (2) The curved path of the vessel in 3D must be taken into account.
- (3) The angular orientation of the data needs to be determined.

This 3D reconstruction technique is developed in the ANGUS project as described by Slager [9]. Only with a correct geometrical shape of the artery does it become possible to calculate, based on finite element model studies, the fluid dynamic parameters by finite element techniques. This application of 3D display is aimed at a fundamental study of endothelial shear stress due to local blood velocity as an underlying parameter for progression or regression of wall disease.

3. Blood flow quantification

In arteries, so far the blood velocity has been measured with Doppler methods. With the so-called flow wire a velocity component in the length direction of the artery is derived based on frequency shift of the echo signal. This does not necessarily correspond with information on the volume flow through the artery. Only under a number of assumptions on flow profile, direction of measurement, sample volume and positioning of the echo element within the artery, can the volume flow be approximated.

With an alternative method it is possible to derive volume flow directly from sequential cross-sectional information [8]. When randomly distributed blood particles travel through the ultrasonic imaging plane, the received echo signals decorrelate as a function of time. The speed of such a decorrelation is proportional to the flow velocity [10]. This phenomenon provides a potential to estimate the local velocity component at each point of the cross-sectional image. The method is based on multiple decorrelation assessments applied to a sequence of radio frequency (RF) signals. In practice each radial echo line of a cross-sectional image is acquired several times in order to make the comparison possible. Each RF echo results in a specific position on the echo line and is compared with the RF echo result in the same position on the previous line. The velocity component is obtained by comparing the decorrelation value with prior knowledge of the beam characteristics

of the intravascular ultrasonic transducer. Volume flow is obtained by integrating the velocities over the entire cross-section. The geometry is illustrated in Fig. 3.

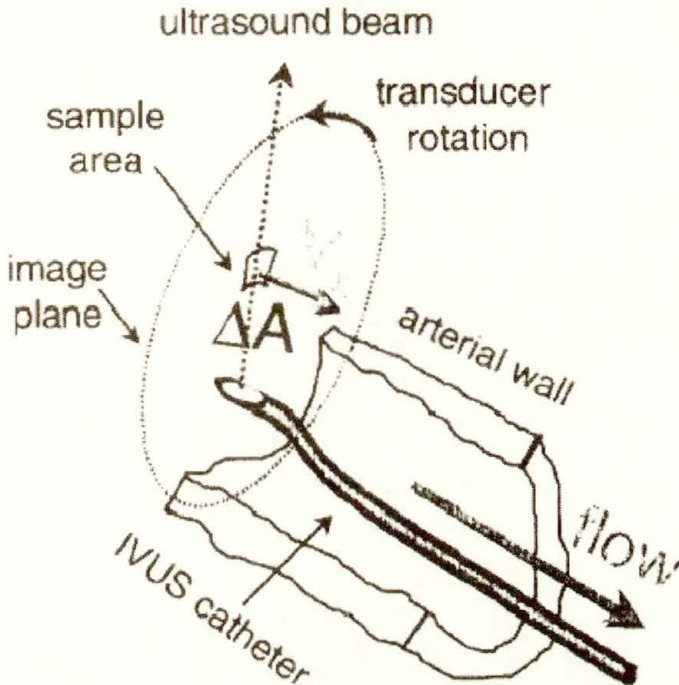


Fig. 3. Geometry of volume flow calculation. Velocity is in the X-direction and in sample areas along the sound beam, repetitive measurements are made.

Preliminary results have shown an excellent correlation with electromagnetic volume flow data measured *in vivo* in animal experiments. This method allows for colour coding of the velocity over the cross-section. The resulting image enables a direct qualitative assessment of the dynamic flow characteristics.

4. Elastography

Intravascular elastography is a new experimental technique to image the local mechanical properties of the vessel wall and atherosclerotic plaque using IVUS [11]. Knowledge of these mechanical properties can be useful for guiding interventional procedures (balloon dilatation, stenting).

Elastography is based on the principle that hard, non compliant material will deform less than soft, compliant tissue. Compression can be applied using the arterial pressure or a compliant balloon. Elastographic information is obtained using two or more IVUS images acquired at different levels of intravascular pressure. The rate of compression is obtained by local correlation of the gated RF-signals.

Phantom studies revealed the potentials of intravascular elastography, to identify differences in hardness independently of the echogenicity of the material [12].

In vitro studies of human femoral arteries revealed that regions with various pathological properties can be identified, using the strain information. Although intravascular elastography is yet in its infancy, the principle is working and practical applications seem feasible. Further developments in connection with improvements in spatial resolution and further understanding of 'elastographic artifacts' [13] will result in an additional imaging modality to the conventional IVUS image.

5. Conclusion

Intravascular imaging has significantly changed the view of interventional procedures and related measurement methods such as angiography. It has provided a new means for selection of interventional devices. Since IVUS catheters can only be used once, the related expenses have limited the use of this technique. It has however shown to be of decisive importance in selected cases. Improvements in design, extended parameter extraction, and reduction of production costs will further stimulate IVUS to become one of the major tools in interventional cardiology.

References

- [1] P.N.T. Wells, *World Med. Electron.* 66 (1966) 272.
- [2] N. Born, *Ultrasonics IO* (1972) 72.
- [3] H. ten Hoff, *Scanning mechanisms for intravascular ultrasound imaging*, Thesis, Erasmus University Rotterdam, June 1993.
- [4] J.M. Tobis, P.G. Yock, *Intravascular Ultrasound Imaging*, Churchill Livingstone, New York, 1992.
- [5] H. ten Hoff, *Semin. Intervent. Cardiol.* 2 (1997) 63.
- [6] H. Liang, B. Hu, *Semin. Intervent. Cardiol.* 2 (1997) 75.
- [7] W. Li, *J. Vast. Invest.* 1 (1995) 57.
- [8] W. Li, *Image and signal processing in intravascular ultrasound*, Thesis, Erasmus University Rotterdam, June 1997.
- [9] C.J. Slager, *Semin. Intervent. Cardiol.* 2 (1997) 43.
- [10] W. Li, *IEEE Ultrasonics Symposium* (1996) 1485.
- [11] E.I. Cespedes, *Semin. Intervent. Cardiol.* 2 (1997) 55.
- [12] C.L. de Korte, *Ultrasound Med. Biol.* 23 (1997) 735.
- [13] C.L. de Korte, *IEEE EMBS Conf. Proc. Amsterdam, 1996. Paper No. 487.*