

# Cartilage and Bone Tissue Engineering in the Head and Neck Surgery—Clinical Expectations

WOJCIECH KUKWA<sup>1)</sup>, MAŁGORZATA LEWANDOWSKA-SZUMIEL<sup>2)</sup>,  
ANDRZEJ KUKWA<sup>1)</sup>, PIOTR WÓJTOWICZ<sup>1)</sup>

<sup>1)</sup> *Department of Otolaryngology, Division of Stomatology  
Warsaw Medical University  
Stępińska 19/25, Warsaw  
wkukwa@poczta.vir.pl*

<sup>2)</sup> *Department of Biophysics and Human Physiology  
Warsaw Medical University  
Chałubińskiego 5, 02-004 Warsaw  
mszumiel@ib.amwaw.edu.pl*

Reconstructive surgery in the head and neck region helps to restore the continuity and function of the tissues. There are many different techniques available to use. Unfortunately very often we fail to achieve good functional and cosmetic effect because of lack of the tissues. In this chapter the most common tissue defects in the otolaryngology, neurosurgery and maxillofacial surgery are presented together with the possible methods of treatment. These include the possible use of cartilage and bone tissue engineering.

Key words: *Cartilage tissue engineering, bone tissue engineering, nasal septum, tympanic membrane, auricle, larynx trachea, cranium*

## 1. Introduction

Otolaryngology is a specialty for the nose, ear, pharynx and larynx disorders. Therefore it is a complex surgical discipline that refers to very diverse organs.

Large group of surgically treated patients have fragments of their tissues removed. Especially in the cases of neoplastic disease, very often massive

tissue loss occurs as a result of surgery. The defects have to be reconstructed somehow, and the function of the dissected organ should be replaced.

Another group of patients who need reconstructive surgery are the victims of injuries, in most cases of car accidents. The next group are children with born deformities.

Surgical techniques of reconstruction of missing parts used nowadays are very imperfect. This is because they are connected with an extended time of the operation and additional traumatization of the patient. The last thing is due to the necessity of transferring tissues, usually from the proximal areas, and in other cases also from the distant areas (mandible reconstruction with the fibule transferred from the lower leg). The other method of replacing the tissue loss is the application of an artificial, manufactured implant. The first written description of the repair of a calvarial defect with a gold plate dates from the turn of the XV and the XVI century [1]. Unfortunately such applications are limited with serious complications, including infection, immunologic overreaction and others. In addition to that, synthetic materials that do not assimilate with tissues cannot be used in pediatric surgery, as they do not allow for the appropriate growth.

Taking all this into the consideration, the ideal method in reconstructive surgery, in the head and neck region would be the application of biological, biocompatible materials that can fully assimilate with the patient's surrounding tissues, would not induce the overreaction of the immune system, and in case of pediatric patient would enlarge as child grows.

Fundamental biomaterials which could be used in otolaryngology are the ones replacing the cartilage and bone, (Table 1). Cartilage tissue engineering

TABLE 1. Possible applications for cartilage and bone tissue engineering in head and neck reconstructive surgery

engineered tissue	place of reconstruction	reconstructed tissue
cartilage	nose	nasal septum cartilage
	ear	eardrum fibrous tissue*
		auricular cartilage
	larynx	laryngeal cartilages
trachea	tracheal cartilages	
bone	cranium	calvarial bone defects
		craniofacial bone defects

\* eardrum is not built of cartilaginous tissue. Some surgeons use cartilage to reconstruct tympanic membrane perforation though.

might be useful in the nose, ear and larynx/trachea treatment. Bone tissue engineering on the other hand could be applied in the procedures that combine the fields of otolaryngology and neurosurgery (where as a result of surgery, loss in skull bone occurs), and otolaryngology and maxillofacial surgery (to replace the missing parts of craniofacial bones that mostly occur as an aftermath of the neoplastic diseases).

## 2. Cartilage Tissue Engineering

### 2.1. Nose

**2.1.1. Perforation of the nasal septum.** The most frequent problem requiring the application of the autologous graft or a biomaterial in the rhinosurgery is nasal septum perforation (Fig. 1). The perforation is a defect located usually in the anterior, cartilaginous part of the septum. Predated rhinosurgical procedure is the main cause of perforation. The removal of the septal cartilage combined with slight but bilateral damage to the continuity of the septal mucosa leads to frequent appearance of the perforation. Other common causes are mechanical injuries or intranasal application of substances inducing local ischaemia (especially cocaine). Although usually such perforation does not lead to a significant discomfort, it might cause periodical, massive bleedings, and crustation which gives the sensation of congestion. In extreme cases such perforation could lead to the nasal framework damage, nasal collapse and deformity [2].

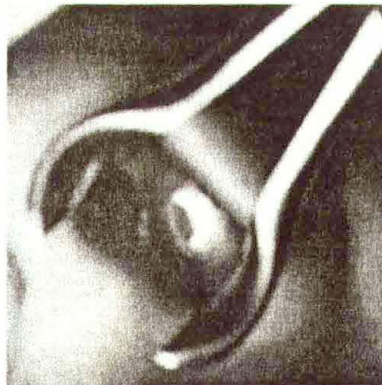


FIGURE 1. Perforation of the nasal septum. The source of light is inserted into the right nasal cavity and the perforation can be observed.

Research focused on the application of tissue engineering procedures in the treatment of nasal septum perforation are still in the experimental phase. Despite this, its results both in animal models and human cartilage culture in the athymic animals seem to be promising [3–8].

Considering typical extension of the perforation, required diameter of the implant should be approximately 1.5 to 2 cm, and its thickness should not exceed 2 mm. The most appropriate biomaterial should be malleable, easily tailored during the operation (to be cut out of the larger plate of biomaterial).

It seems that the biomaterial should be covered with chondrocytes especially when it is a part of a nasal framework, and not only the filling of a perforation. In these cases it is recommended that the biomaterial used as a framework would have been nearly completely nonresorbable, so that during after-surgery phase would not change its original dimensions.

When biomaterial is applied for the perforation obliteration, the basic aim should be the ability of the implant to make the mucosa grow onto it. If this assimilation fails, mucous layer would become necrotic and again the perforation of even larger dimensions is likely to appear. Additionally, the developing cartilage doesn't have to be a pure cartilage in the histological sense (as it is required in the case of joint cartilage). It may be partially a fibrous tissue. The essential property is its capacity to heal the mucosa.

In case of application of the biomaterial for the nose shape surgical corrections or reaching two aims: to repair the septal perforation and to use the biomaterial as a nose framework at the same time, implant should resorb slowly or not resorb at all. As a consequence, during the postoperative period, implant would maintain its original dimensions. This would provide the preservation of the nasal shape formed during the operation. Also in the reconstructive surgery, especially after extended oncological operations, it would be possible to apply biomaterials for the nasal forming purposes. Currently obtaining skin flaps to reconstruct nose missing parts is not a problem. The use of forehead flap is well known since the ancient times, and slightly modified since then [9]. The real problem in such operations is the deficit of the framework elements, which also are resected during the oncological procedure (Fig. 2).

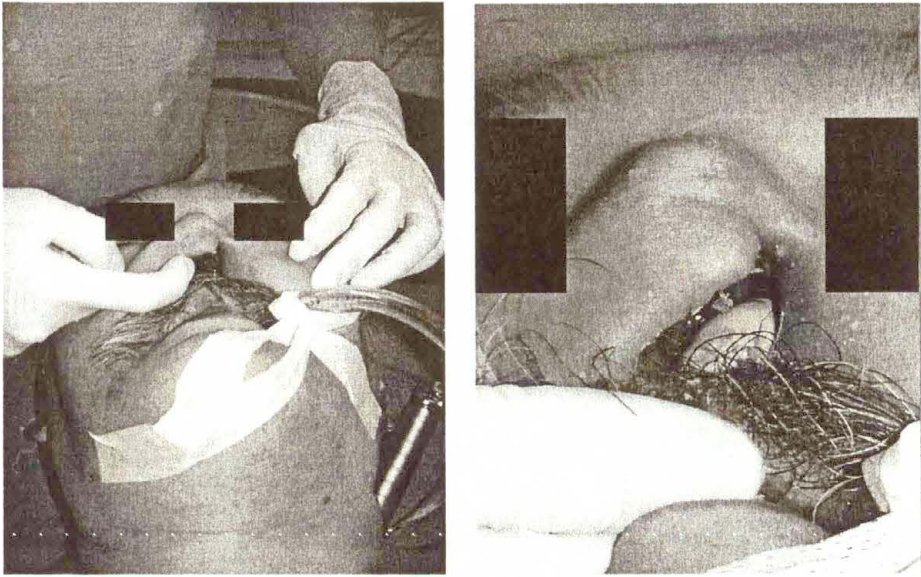


FIGURE 2. Patient following partial nasal resection. There is a certain problem with obtaining a framework for the nasal reconstruction.

## 2.2. Ear

**2.2.1. Perforation of the tympanic membrane.** The tympanic membrane perforation is a very common problem in otolaryngology. The most often it is caused by a trauma and acute or chronic middle ear infection (Fig. 3). The tympanic membrane injury leads to unilateral hearing loss. Additionally the middle ear is not separated from the external environment then, and therefore is much more susceptible to the recurrent inflammation.

Typically, the tympanoplasty with the use of autologous tissues: perichondrium, periosteum, or fascia is performed. This type of procedure requires another incision, often in the other location. Nevertheless it seems that the application of some biomaterials would be advisable. A biomaterial that would heal much faster into the place of tissue loss would be useful. Besides the material that would transmit soundwaves with a better characteristics is preferred. Physiologically, the tympanic membrane is a 3-layer structure. Externally it is covered with epithelium, internally with mucosa. The middle layer is composed of elastic fibers. Some of them are placed radially, the other in circles. Thanks to the elastic fibers, the tympanic membrane has two basic features: it is very susceptible to the pressure changes of the sound

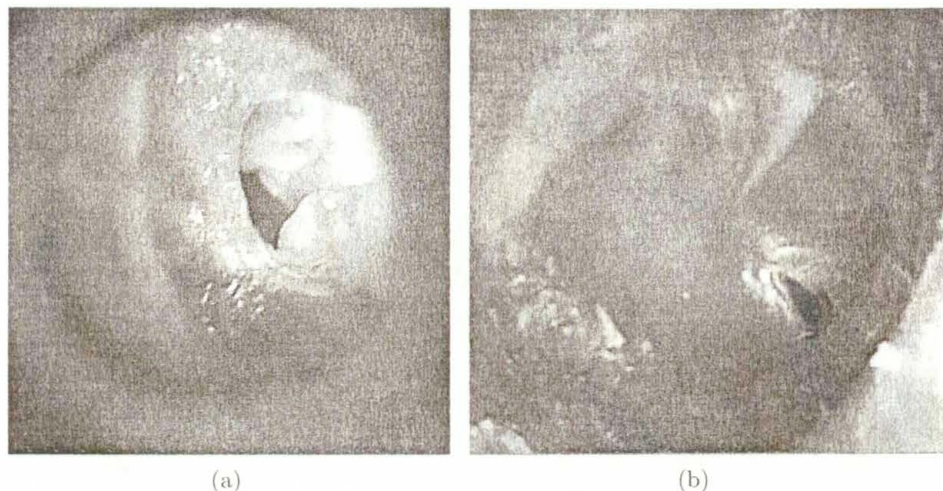


FIGURE 3. Tympanic membrane perforation; (a) chronic otitis media. The perforation is round, with well defined, healed margins, (b) perforation caused by an injury—sharp margins of perforation, whole tympanic membrane is hyperaemic.

wave, and it stops vibrating instantly after the sound stops. In our opinion a mesh of microfibers, that would only act as a scaffold for the epithelial and mucosal cells to migrate on the biomaterial and rebuild the tympanic membrane layers would be most suitable. Standard diameter of the implant would be 5–8 mm, and its thickness  $< 0.5$  mm.

Until now another approach to the tympanoplasty has been made. A tissue engineered, cultured *in vitro* patch, has been presented in the animal model [10].

**2.2.2. Auricular reconstruction.** Auricular defects or congenital deformities are quite rare comparing to tympanic membrane perforation. Unfortunately they are much more complicated in treatment, and up to date can not be treated with a significant success. Patients who require such a procedure are mainly children with congenital deformities. This can be a single deformity or a part of larger syndrome, like Treacher-Collins syndrome, Franceschetti's syndrome, Goldenhar's syndrome, Gregg's syndrome (Fig. 4). Adults who require a reconstructive surgery of the auricle are patients with neoplasms in the first place, rarely victims of the accidents and other traumas of this area (Fig. 5).

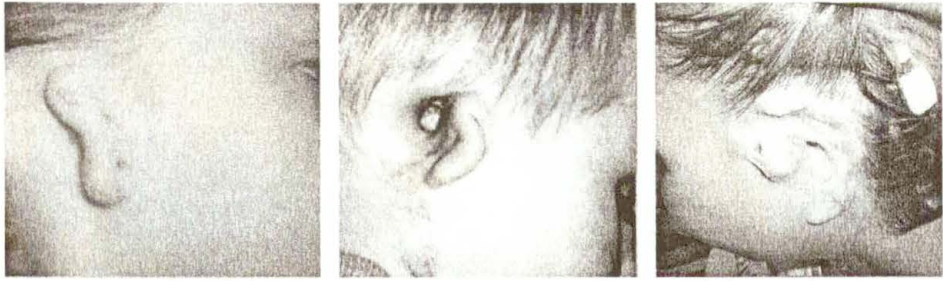

FIGURE 4. Young patients with microtia. This can be a single deformity or a part of a whole syndrome.

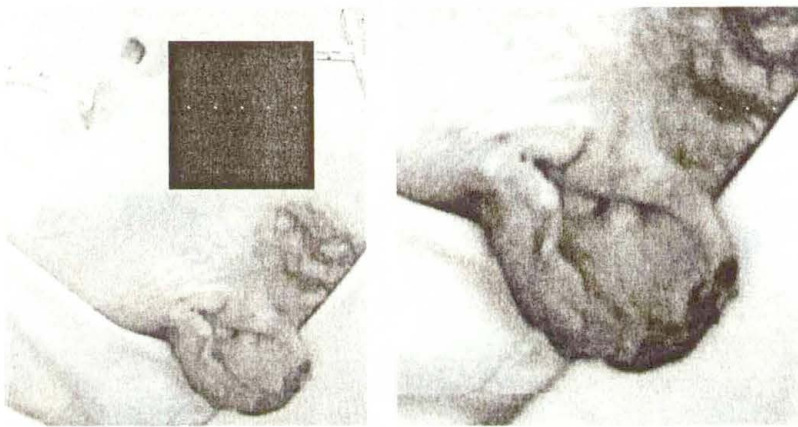


FIGURE 5. Neoplasm of the left auricle. Both photographs present the same case. Patient requires near-total auricectomy. The reconstruction might be possible with the tissue engineering procedures.

Nowadays, one of the following methods of treatment and materials can be used:

- autologous cartilage from the patient's rib,
- allogeneous cartilage from the patient mother's rib,
- reconstructions with the use of remaining elements of the auricle,
- tissue expanders,
- artificial auricle—a manufactured prosthesis.

Except the use of a prosthesis, in all of the above, cartilagenous material is placed in the subcutaneous tunnel. Therefore it becomes a framework to the covering skin of the reconstructed auricle (Fig. 6).

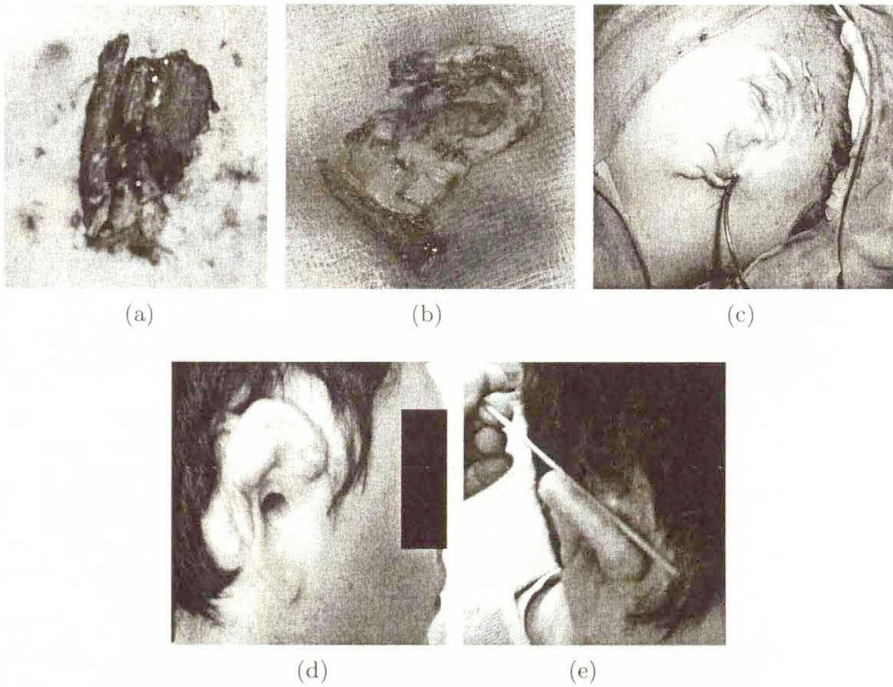


FIGURE 6. Step-by-step procedure in microtia surgery. (a) cartilage harvesting from the rib, (b) shaping the implant, (c) insertion of the cartilage in the subcutaneous tunnel, (d, e) postoperative effect. The cartilage acts as the framework for the covering skin.

It could be similar with the use of a biomaterial. The research conducted recently indicate that the ideal method is an application of a gel-like scaffold to suspend the chondrocytes [11–15]. The construct of chondrocytes and a gelly scaffold would be inserted into the prepared subcutaneous tunnel in the shape of an auricle, just as it is done right now. Such construct needs to be nearly nonresorbable to prevent the auricle from reducing its dimensions.

As in other cases, the use of a prosthesis increases the risk of infection on the foreign body. In addition to this, a prosthesis used in the pediatric surgery has to be replaced as the child grows.

### 2.3. Larynx and Trachea

Subglottic stenosis is a pathology of laryngeal or tracheal cartilages, or mucosa abnormalities. All of them lead in turn to narrowing of the lumen



of the upper respiratory tract. These as a consequence cause breathing impairment. While a stricture is mild, the inhaling disturbances arise. In severe cases, the disturbances become both, inhaling and exhaling.

There are two types of subglottic stenosis—congenital and acquired. Much more common are the acquired stenoses. They account for over 90% of all laryngeal and tracheal strictures. They are also more problematic in treatment. Among many causes of acquired subglottic stenosis, the prolonged intubation is certainly in the first place. It is responsible for over 90% of acquired strictures. The other factors include: trauma of the neck or the neck operation, massive inflammation of the respiratory tract, caustic and thermal injuries, etc. Wound healing in these instances occurs with development of granulation tissue and the deposition of fibrous tissue and scarring. All these may result in clinically apparent stenosis.

Many surgical procedures are used nowadays to treat subglottic stenosis. The method used in the treatment depends mainly on the grade of the stricture, the age of the patient, and also the method preferred in the department. A four grade scale is used to define the scale of the stenosis—Myer and Cotton staging system [16]. Grade I lesions have less than 50% obstruction, grade II lesions have 51% to 70% obstruction, grade III lesions have 71% to 99% obstruction, and grade IV lesions give no detectable lumen or complete stenosis.

The mild stenoses, which are grade I and II in the Myer-Cotton staging system, are usually treated with microsurgical, endoscopic methods. Among them is a mechanical augmentation of the lumen, endoscopic treatment with the use of CO<sub>2</sub> laser (Fig. 7). The use of a plasma coagulation (Erbe) is another fine method of treatment of grade I and II strictures. The overall success rates range from 66–80%.

The strictures in grade III and IV in Myer-Cotton staging system are usually treated with open surgical procedures. The most common operations performed in such cases are: anterior or posterior cricoid split, and one of many modifications of laryngotracheoplasty. Another method of treatment is an end-to-end anastomosis after partial resection of the trachea (Fig. 8). It is believed, that the last should be chosen especially in the case of cricoid cartilage disorders.

It seems very plausible to use constructs which would substitute the cartilage to build the elements of laryngeal and tracheal framework. Application of biomaterial rings imitating the tracheal cartilages would be a breakthrough.

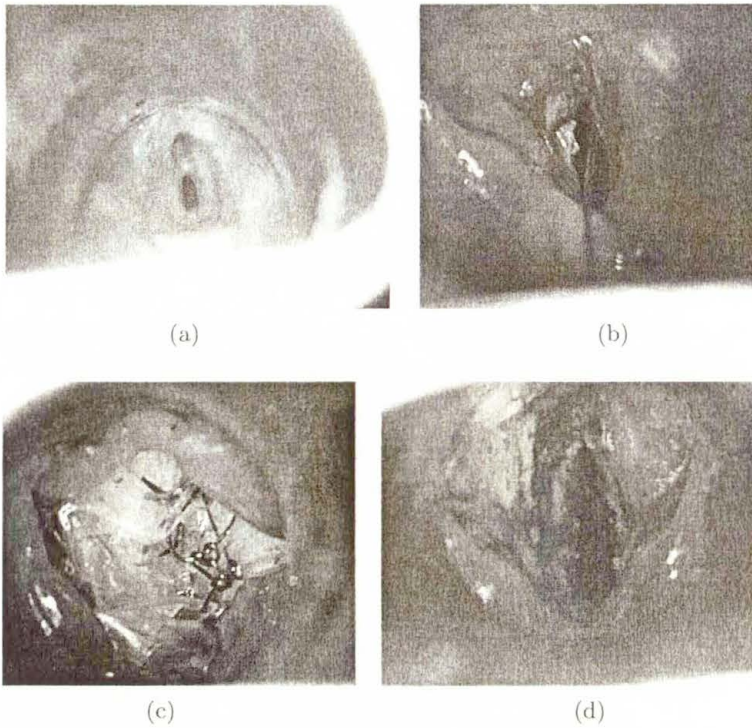


FIGURE 7. Step-by-step procedure in the treatment of subglottic stenosis; (a) picture of the subglottic stenosis, (b) widening of the stenosis with the use of a laser, (c) application of the teflon sheet to prevent from scarring and stenosis, (d) 3 weeks after removing the sheet; enlarged lumen of the subglottis when compared to photograph (a).

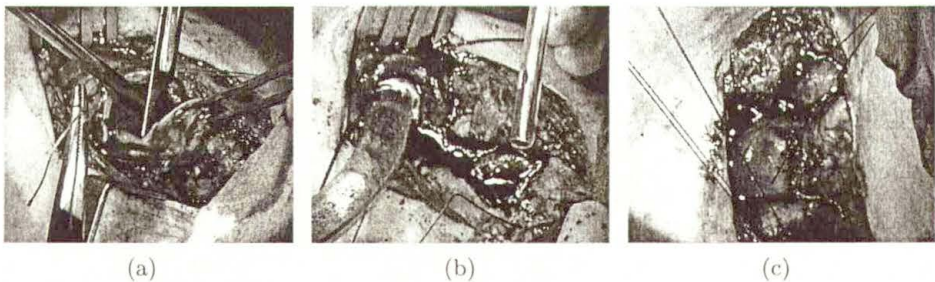


FIGURE 8. End-to-end anastomosis of the trachea in the treatment of tracheal stenosis. (a, b) dissection of the stenotic region, (c) an end-to-end anastomosis of the trachea.

Those rings would be inserted in the place of dissected tracheal cartilages. Two methods of treatment seem to be possible—either the application of the rings that would match exactly the tracheal cartilages to simply substitute one with the other, or the application of the biomaterial rings of larger diameter, that would surround the trachea, and tracheal cartilages would be mounted to it and expanded.

Different tissue engineering procedures of reconstruction of the lumen of the upper respiratory tract were studied in the recent years. Until today none of them were applied in the clinical treatment, and all of the research are in the experimental phase. Few teams working on this subject worldwide elaborated different techniques of proceeding in the case of subglottic stenosis. Schematically the methods can be divided into three groups:

1. the use of endotracheal stents, prepared from bioresorbable materials,
2. cartilage tissue engineering,
3. attempts to epithelium tissue engineering.

The easiest way to apply tissue engineering techniques in the subglottic stenosis treatment is the use of bioresorbable endotracheal stents. The PGLA stents were studied [17]. They were used after anterior tracheoplasty with the use of fascia lata in rabbits. A biodegradable tracheal stent was used internally to stabilize and support surgically reconstructed airways. By 14 weeks the stents were nearly 100% degraded.

Another method of treatment is to prepare tissue engineered cartilage as a functional tracheal replacement. After harvesting the cartilaginous tissue, the cells were isolated, cultured and then seeded onto different biomaterials. Tissue samples were obtained from many localizations, including: larynx and trachea, auricle, rib, and nasal septum [18–23]. Clinically, in the treatment of subglottic stenosis, the most important layer of larynx and trachea is the epithelium. Most surgical procedures with the use of a nonbiologic material (eg. titanium plates) require that the implant needs to be coated with a biological layer, preferably the epithelium, but also with the perichondrium or fascia. In other cases, granulation tissue and the deposition of fibrous tissue returns, and the stenosis recurs in the time of weeks or months. Most sophisticated tissue engineering procedures in tracheal and laryngeal stenosis treatment develop the cartilagineous framework covered with epithelium on the internal wall. Different tissues were used as a source of isolated epithelial

cells. The optimal place to harvest respiratory epithelial cells together with cartilage cells is the nasal cavity. As the procedure of harvesting is minimally invasive, and easy to perform, it might become the place of tissue harvest in the clinical trials [24–26].

### 3. Bone Tissue Engineering

Bone defects in the craniofacial and calvarial area vary in shape and size. The majority of cases of the bone defects that make the bone useless in the reconstructive surgery are the neoplastic transformations within the bone. Such a tissue has to be removed with a large fine margin and the missing part has to be replaced. In most of other cases, the bone might be replaced into its original place, after some preparations.

In bone surgery of both maxillofacial area and a skull, the biomaterial that could be used in reconstructive surgery must be tension-resistant, non-resorbable, and certainly not fragile.

What is the most important, due to the fact that in most cases the tissue engineering procedures in bone reconstruction in the head region would be applied to the oncological patients, the biomaterial must be neutral to the radiotherapy, as radiotherapy or chemoradiotherapy is a standard treatment that follows the operation.

#### 3.1. Calvarial Reconstruction

Presently, when we deal with the large bone defect in the calvarial area, one of the available artificial materials is used to close the wound. The surgeon might choose from the titanium and other material mesh or plates, or different bone cements (Fig. 9). In Poland, except for the titanium, there is a polypropylene- polyester knitted fabric (Codubix®) approved in clinical use [27–29]. None of the above scaffolds (except for the titanium) is settled with the patient's blast cells *in vivo*. In the many years follow-up, after implantation of the artificial material, it doesn't integrate with patient's tissues and is fixed only with the stitches and cicatrix that surrounds the foreign body. In some cases the prostheses become movable [27]. Another problem is the infection around the implant.

The most commonly used bone cement is the polymethylmethacrylate [30]. The use of a bone cement is much easier as it can be easily formed in any shape during the surgery. Unfortunately, apart from the complications

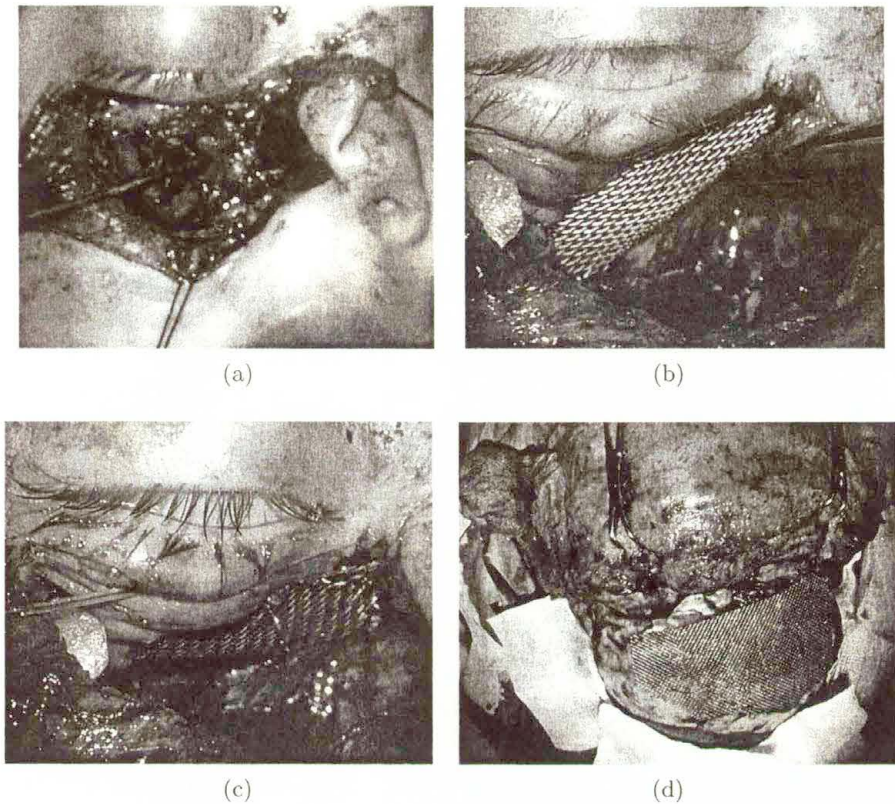


FIGURE 9. The use of titanium mesh in the skull surgery. (a–c) subsequent steps of orbital floor reconstruction, (d) frontal bone reconstruction.

mentioned above, the use of methylmethacrylate is combined with one more. The exothermic reaction produced during the polymerization of the cement yields temperatures over  $80^{\circ}\text{C}$ , [31]. At that temperature the necrosis of the surrounding tissues occurs. This is not a case when the biomaterial, hydroxyapatite cement is used [32, 33]. What is also important, hydroxyapatite cement promotes osseointegration and vascularization [33].

A biomaterial that could integrate with the surrounding tissues would be preferred, as the biomechanical properties would imitate the biological bone.

In case of using the elements of biomaterial rather than a cement, the basic shape of the construct, its thickness and a curvature of the skull, might be prepared preoperatively. The final shape of the biomaterial would be prepared either during the operation, or also preoperatively with the application of the computer tomography 3D scans [34].

### 3.2. Craniofacial Reconstructions

In the maxillo-facial area the most common are the defects of maxilla and mandible. Both the neoplastic diseases and injuries include mainly these two bone regions.

Most of the maxilla is built of a thin plate of bony tissue. It surrounds a maxillary sinus. Fractures of maxilla are treated quite efficiently with the use of titanium plates or meshes (Fig. 9), and PLA or PGLA [35, 36]. The biomaterials used are applied without any seeded cells, and they are only set as a resorbable fixation system. Defects of maxillary bone can be restored with titanium plates or materials that are used in the calvarial region. Tissue engineering procedures were also used in the treatment of the haemangioma of the maxillary sinus, [37].

In the reconstructive surgery of mandible, the situation is different. The bone is much thicker, and the mechanical forces are much stronger. At present, after partial mandibular resection, one of the following procedures is possible: end-to-end fixation, the use of titanium plate, or autologous material (eg. a part of fibule, transplanted together with vasculature from the lower leg).

As in other head and neck defects, it seems obvious that the optimal material would act as an autologous tissue and would be obtained without additional scarring of the patient. These requirements are fulfilled only by engineered tissues.

### 4. Conclusions

Different defects in the head and neck region are quite often. Most of them can be reconstructed surgically. Unfortunately some of the procedures in the bone and cartilage defect treatment are very imperfect, and the effects of operations are unsatisfactory.

Some of the biomaterials, like PLA or PGLA, are already allowed in the clinical use. The majority of tissue engineering procedures are still in the pre-clinical trials and wait for the approval, [38–40]. It is certain that with new tissue engineering procedures the reconstructive surgery will be more effective and much more aesthetic in the coming years.

### Acknowledgement

The present study has been supported by the State Committee for Scientific Research, Poland (grant No. 05/PBZ-KBN-082/T08/2002).

## References

1. G. FALLOPIUS [in:] *Opera omnia*, Francofurti, Wecheli, A., Ed. 1, 1600.
2. K.J. LEE, *Essential Otolaryngology. Head and Neck Surgery* Appelton&Lange
3. S.H. CHIA, B.L. SCHUMACHER, T.J. KLEIN, E.J. THONAR, K. MASUDA, R.L. SAH, and D. WATSON, *Tissue-engineered human nasal septal cartilage using the alginate-recovered-chondrocyte method*, *Laryngoscope*, **114**(1): 38-45, 2004.
4. A. HAISCH, G.N. DUDA, D. SCHROEDER, A. GROGER, C. GEBERT, K. LEDER, and M. SITTINGER, *The morphology and biomechanical characteristics of subcutaneously implanted tissue-engineered human septal cartilage*, *Eur. Arch. Otorhinolaryngol.*, 2005.
5. N. ROTTER, L.J. BONASSAR, G. TOBIAS, M. LEBL, A.K. ROY, and C.A. VACANTI, *Age dependence of biochemical and biomechanical properties of tissue-engineered human septal cartilage*, *Biomaterials*, **23**(15): 3087-3094, 2002.
6. N. ROTTER, J. AIGNER, A. NAUMANN, H. PLANCK, C. HAMMER, G. BURMESTER, and M. SITTINGER, *Cartilage reconstruction in head and neck surgery: comparison of resorbable polymer scaffolds for tissue engineering of human septal cartilage*, *J. Biomed. Mater. Res.*, **42**(3): 347-56, 1998.
7. M.R. HOMICZ, B.L. SCHUMACHER, R.L. SAH, and D. WATSON, *Effects of serial expansion of septal chondrocytes on tissue-engineered neocartilage composition*, *Otolaryngol. Head Neck Surg.*, **127**(5): 398-408, 2002.
8. B.J. WONG, K.K. CHAO, H.K. KIM, E.A. CHU, X. DAO, M. GAON, C.H. SUN, and J.S. NELSON, *The porcine and lagomorph septal cartilages: models for tissue engineering and morphologic cartilage research*, *Am. J. Rhinol.*, **15**(2): 109-16, 2001.
9. J.G. MCCARTHY, *Plastic Surgery*, p.132, W.B. Saunders, Philadelphia, 1990.
10. M.E. HOTT, C.A. MEGERIAN, R. BEANE, and L.J. BONASSAR, *Fabrication of tissue engineered tympanic membrane patches using computer-aided design and injection molding*, *Laryngoscope*, **114**(7): 1290-1295, 2004.
11. S.H. KAMIL, M.P. VACANTI, C.A. VACANTI, and R.D. EAVEY, *Microtia chondrocytes as a donor source for tissue-engineered cartilage*, *Laryngoscope*, **114**(12): 2187-2190, 2004.
12. Y. CAO, J.P. VACANTI, K.T. PAIGE, J. UPTON, and C.A. VACANTI, *Transplantation of chondrocytes utilizing a polymer-cell construct to produce tissue-engineered cartilage in the shape of a human ear*, *Plast. Reconstr. Surg.*, **100**(2): 297-302; discussion: 303-304, 1997.
13. R. ZHANG, C. LIANG, T. QIN, Z. YANG, J. LIU, X. LI, and W. LI, *Tissue-engineered auricled cartilage: an experimental study*, *Zhonghua Er Bi Yan Hou Ke Za Zhi*, **37**(5): 329-332, 2002.
14. S.H. KAMIL, K. KOJIMA, M.P. VACANTI, L.J. BONASSAR, C.A. VACANTI, and R.D. EAVEY, *In vitro tissue engineering to generate a human-sized auricle and nasal tip*, *Laryngoscope*, **113**(1): 90-94, 2003.

15. S.H. KAMIL, M.P. VACANTI, B.S. AMINUDDIN, M.J. JACKSON, C.A. VACANTI, and R.D. EAVEY, *Tissue engineering of a human sized and shaped auricle using a mold*, *Laryngoscope*, **114**(5): 867–870, 2004.
16. C.M. MYER, D.M. O'CONNOR, and R.T. COTTON, *Proposed grading system for subglottic stenosis based on endotracheal tube sizes*, *Ann. Otol. Rhinol. Laryngol.*, **103**: 319, 1994.
17. T.C. ROBEY, T. VALIMAA, H.S. MURPHY, P. TORMALA, D.J. MOONEY, and R.A. WEATHERLY, *Use of internal bioabsorbable PLGA "finger-type" stents in a rabbit tracheal reconstruction model*, *Arch. Otolaryngol. Head Neck Surg.*, **126**: 985–991, 2002.
18. T. WALLEES, B. GIERE, P. MACCHIARINI, and H. MERTSCHING, *Expansion of chondrocytes in a three-dimensional matrix for tracheal tissue engineering*, *Ann. Thorac. Surg.*, **78**: 444–448, 2004.
19. L. YANG, S. KOROM, M. WELTI, S.P. HOERSTRUP, G. ZUND, F.J. JUNG, P. NEUENTSCHWANDER, and W. WEDER, *Tissue engineered cartilage generated from human trachea using DegraPol scaffold*, *Eur. J. Cardiothorac. Surg.*, **24**: 201–207, 2003.
20. K. KOJIMA, L.J. BONASSAR, A.K. ROY, C.A. VACANTI, and J. CORTIELLA, *Autologous tissue-engineered trachea with sheep nasal chondrocytes*, *J. Thorac. Cardiovasc. Surg.*, **123**: 1177–1184, 2002.
21. K. KOJIMA, L.J. BONASSAR, R.A. IGNOTZ, K. SYED, J. CORTIELLA, and C.A. VACANTI, *Comparison of tracheal and nasal chondrocytes for tissue engineering of the trachea*, *Ann. Thorac. Surg.*, **76**: 1884–1888, 2003.
22. K. KOJIMA, R.A. IGNOTZ, T. KUSHIBIKI, K.W. TINSLEY, Y. TABATA, and C.A. VACANTI, *Tissue-engineered trachea from sheep marrow stromal cells with transforming growth factor beta2 released from biodegradable microspheres in a nude rat recipient*, *Thorac. Cardiovasc. Surg.*, **128**: 147–153, 2004.
23. S.H. KAMIL, R.D. EAVEY, M.P. VACANTI, C.A. VACANTI, and C.J. HARTNICK, *Tissue-engineered cartilage as a graft source for laryngotracheal reconstruction*, *Arch. Otolaryngol. Head Neck Surg.*, **130**: 1048–1051, 2004.
24. K. KOJIMA, L.J. BONASSAR, A.K. ROY, H. MIZUNO, J. CORTIELLA, and C.A. VACANTI, *A composite tissue-engineered trachea using sheep nasal chondrocyte and epithelial cells*, *The FASEB Journal*, **17**: 823–828, 2003.
25. C. RAINER, G. WECHSELBERGER, T. BAUER, M.W. NEUMEISTER, S. LILLE, A. MOWLAVI, H. PIZA, and T. SCHOELLER, *Transplantation of tracheal epithelial cells onto a prefabricated capsule pouch with fibrin glue as a delivery vehicle*, *Thorac. Cardiovasc. Surg.*, **121**: 1187–1193, 2001.
26. J. KIM, S.W. SUH, J.Y. SHIN, J.H. KIM, Y.S. CHOI, and H. KIM, *Replacement of a tracheal defect with a tissue-engineered prosthesis: early results from animal experiments*, *J. Thorac. Cardiovasc. Surg.*, **128**: 124–129, 2004.



27. W. MARC, Z. WICENTOWICZ, and A. SKLEPOWICZ, *Treatment of skull defects by using plastic material "Codubix"*, Neurol. Neurochir. Pol., Suppl 1: 316–320, 1992.
28. S. ANDRZEJCZAK, J. FORTUNIAK, G. WRÓBEL-WIŚNIEWSKA, and M. ZAWIRSKI, *Clinical evaluation of the polypropylene-polyester knit used as a cranioplasty material*, Acta Neurochir (Wien), 2005.
29. P. KOLASA and K. BOROŃSKI, *Personal modification of the Codubix prosthesis in craniofacial plastic surgery*, Neurol. Neurochir. Pol., **35**(1): 169–176, 2001.
30. J.P. POCHON, *The repair of congenital and acquired skull defects in childhood*, J. Pediatr. Surg., **17**(1): 31–36, 1982.
31. E.J. STELNICKI, and D.K. OUSTERHOUT, *Prevention of thermal tissue injury induced by the application of polymethylmethacrylate to the calvarium*, J. Craniofac. Surg., **7**(3) 192–195, 1996.
32. C.D. FRIEDMAN, P.D. COSTANTINO, S. TAKAGI, and L.C. CHOW, *BoneSource hydroxyapatite cement: a novel biomaterial for craniofacial skeletal tissue engineering and reconstruction*, J. Biomed. Mater. Res., **43**(4): 428–432, 1998.
33. C.D. FRIEDMAN, P.D. COSTANTINO, C.H. SNYDERMAN, L.C. CHOW, and S. TAKAGI, *Reconstruction of the frontal sinus and frontofacial skeleton with hydroxyapatite cement*, Arch. Facial. Plast. Surg., **2**: 124–129, 2000.
34. W. LINNS, J. BEINEMANN, P. SCHLEIER, E. BELEITES, R. NEUMANN, and W. FRIED, *Problems in the development of a comprehensive three-dimensional data-bank of the human skull for the preoperative preparation of an exact implant for the treatment of bone defects*, Ann. Anat., **185**(3): 2247–2251, 2003.
35. R. SCHIMMING and R. SCHMELZEISEN, *Tissue-engineered bone for maxillary sinus augmentation*, J. Oral. Maxillofac. Surg., **62**(6): 724–729, 2004.
36. R.E. HOLMES, S.R. COHEN, G.B. CORNWALL, K.A. THOMAS, K.K. KLEINHENZ, and M.Z. BECKETT, *MacroPore resorbable devices in craniofacial surgery*, Clin. Plast. Surg., **31**(3): 393–406, 2004.
37. L. WYSIENSKI, *Usefulness study of enriched with growth factors ceramics and polymeric scaffolds as reconstructive material in head and neck surgery*, Ph.D. thesis, 2005.
38. E. ALSBERG, E.E. HILL, and D.J. MOONEY, *Craniofacial tissue engineering*, Crit. Rev. Oral Biol. Med., **12**: 64–75, 2001.
39. S.M. WARREN, K.D. FONG, C.M. CHEN, E.G. LOBOA, C.M. COWAN, H.P. LORENZ, M.T. LONGAKER, *Tools and techniques for craniofacial tissue engineering*, Tissue Eng., **9**(2): 187–200, 2003.
40. M.B. HABAL, *Bone tissue engineering applications in craniofacial reconstructive surgery*, Clin. Plast. Surg., **31**(3): 387–392, 2004.

