Fig. 1

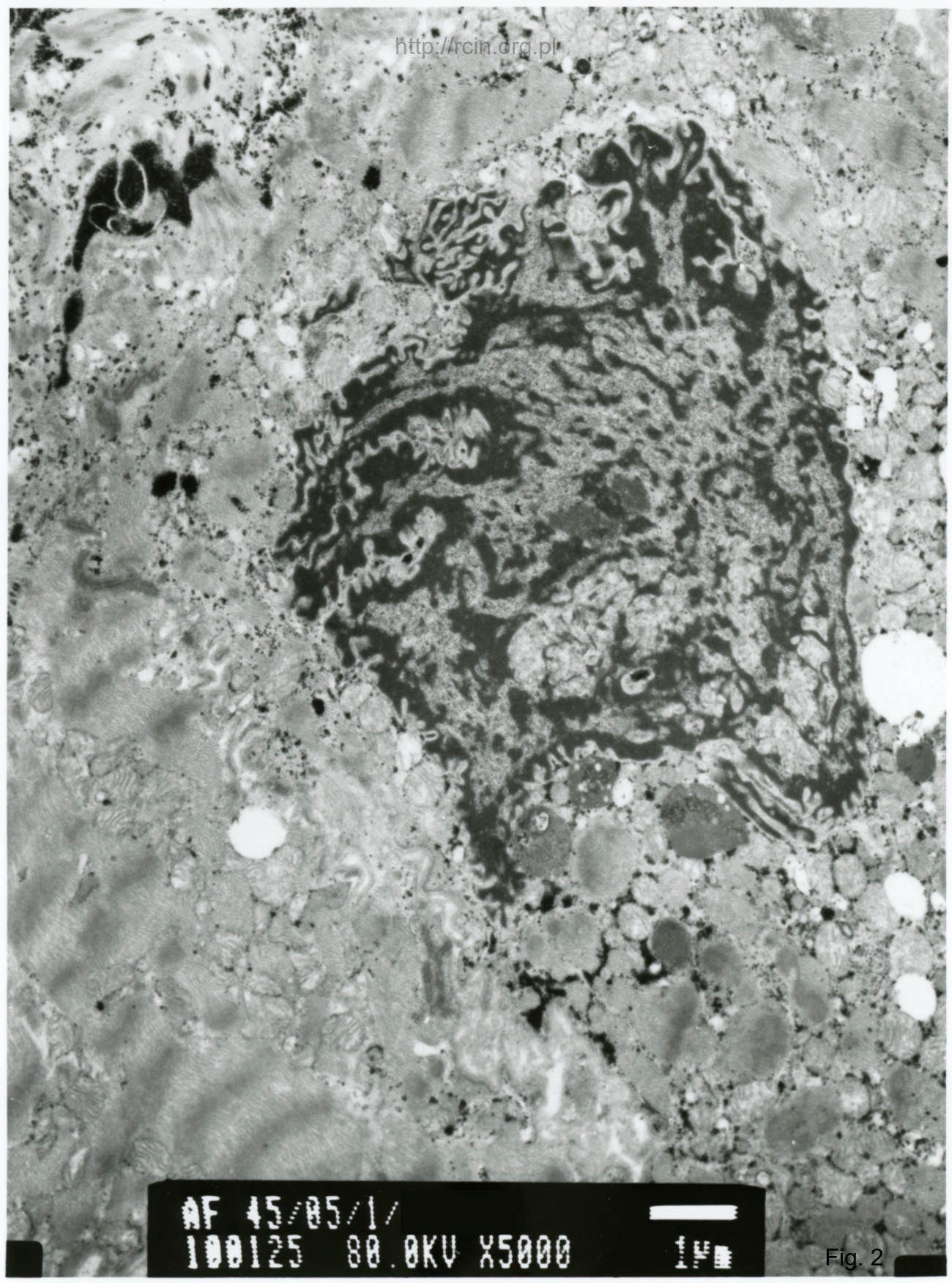

Fig. 2

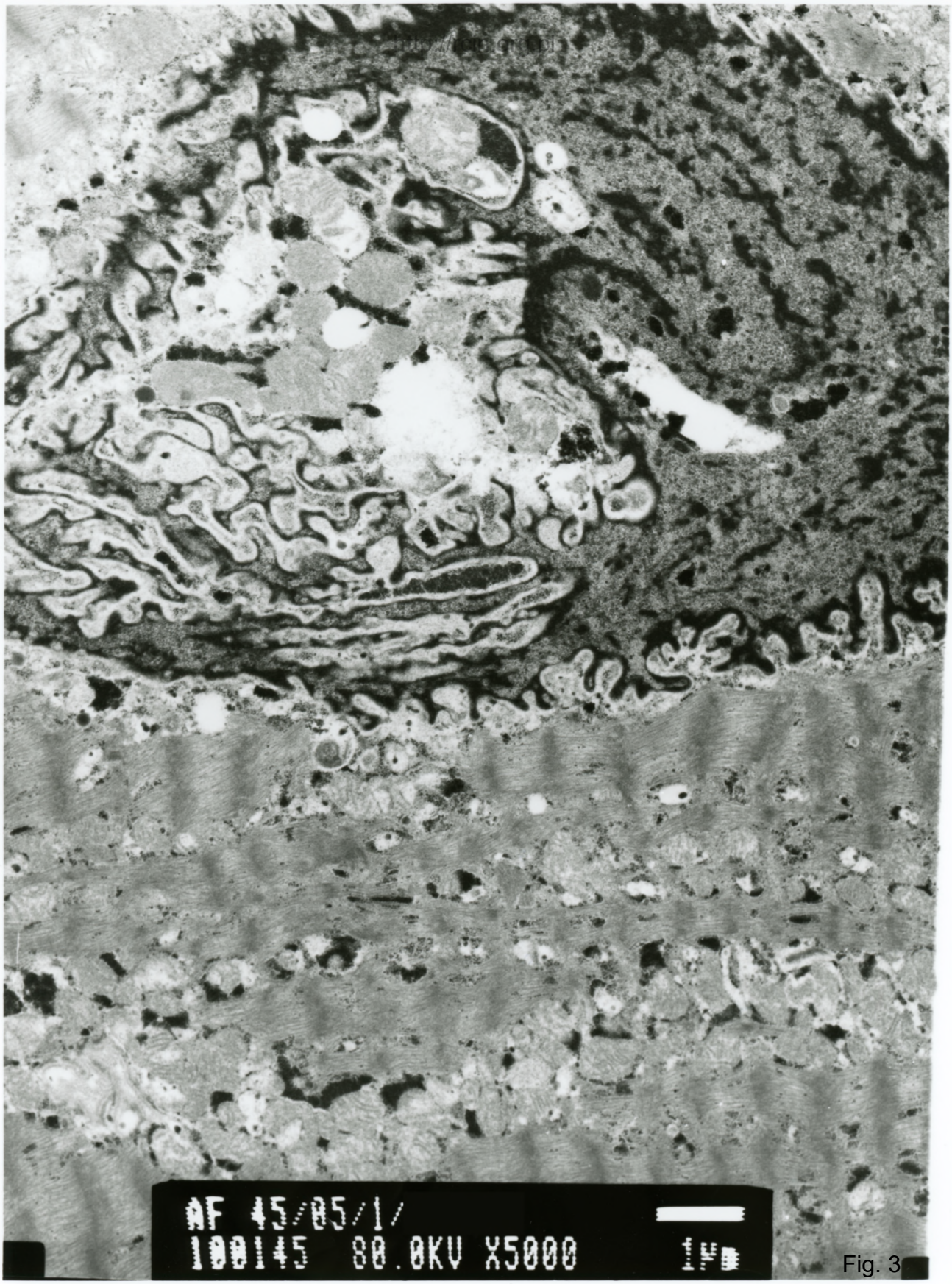

Fig. 3

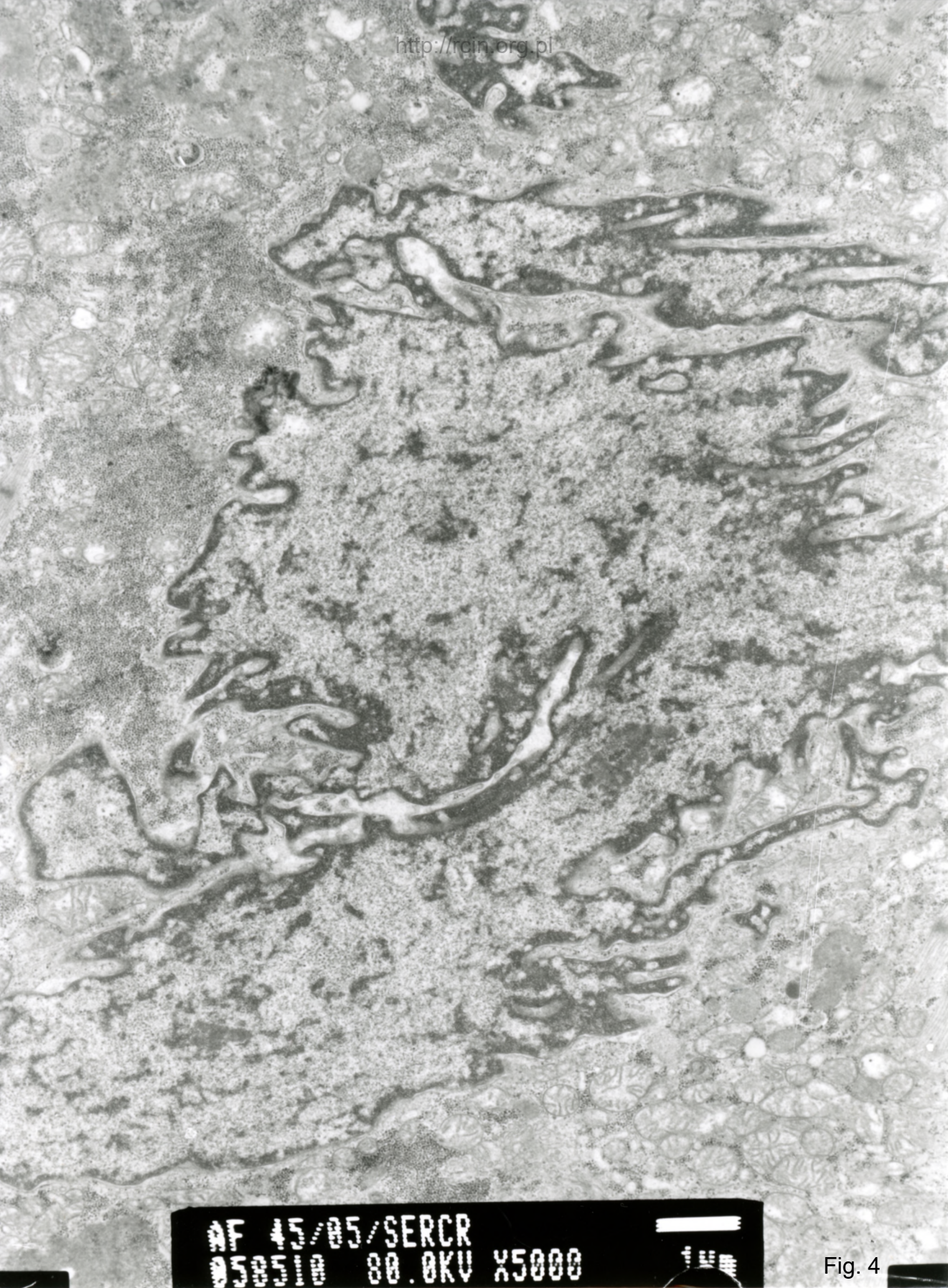

Fig. 4

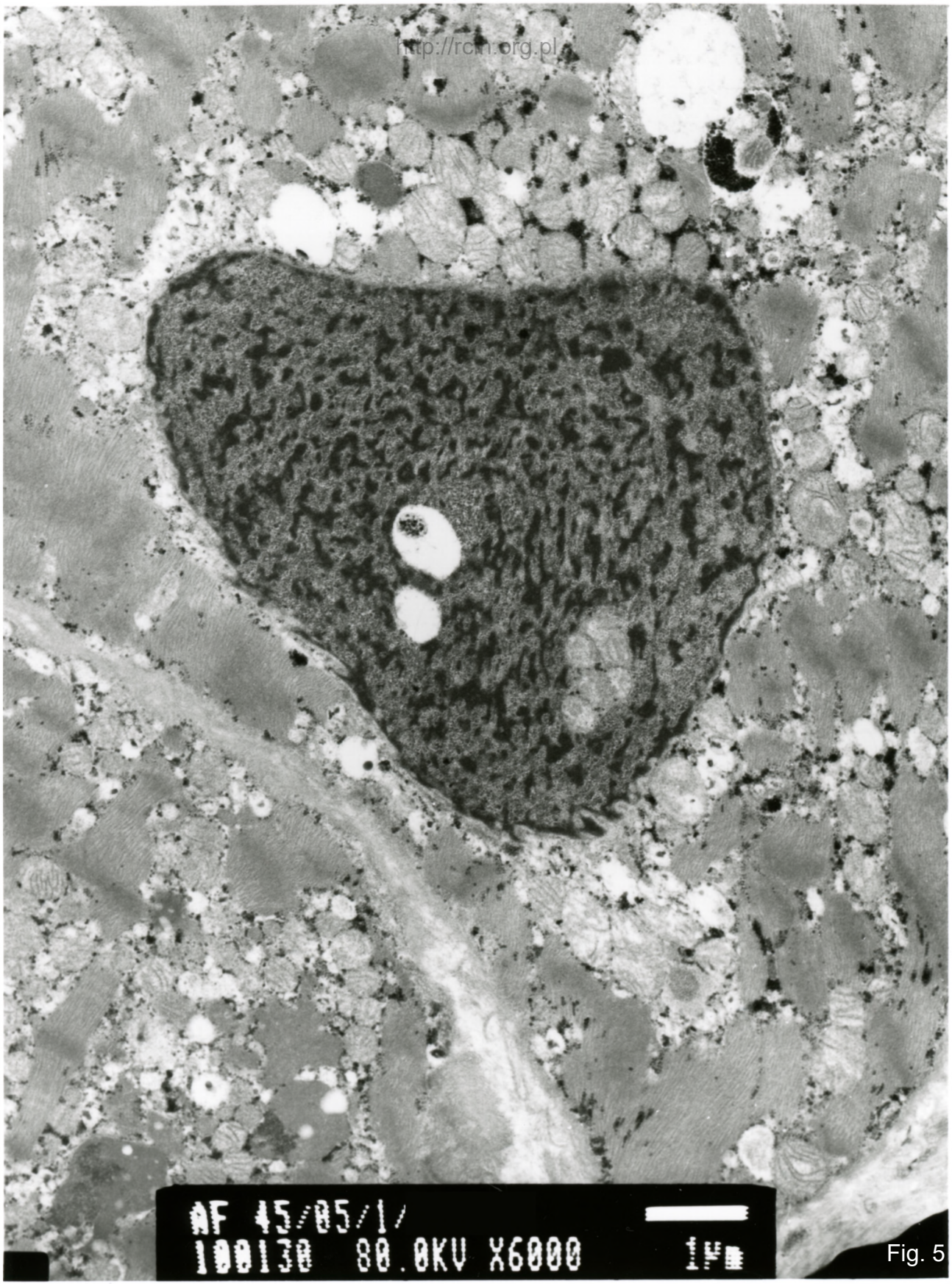

Fig. 5

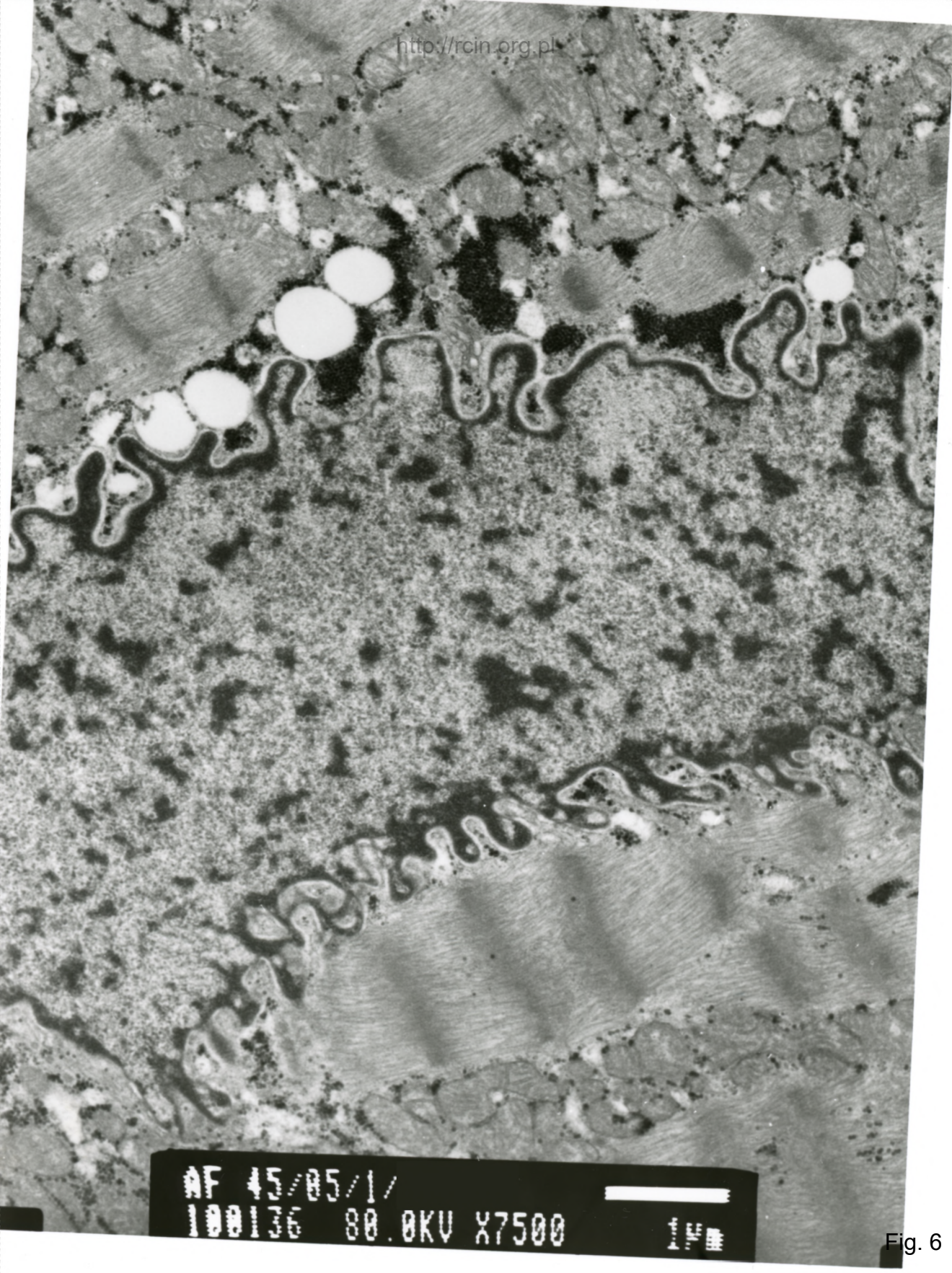

Fig. 6

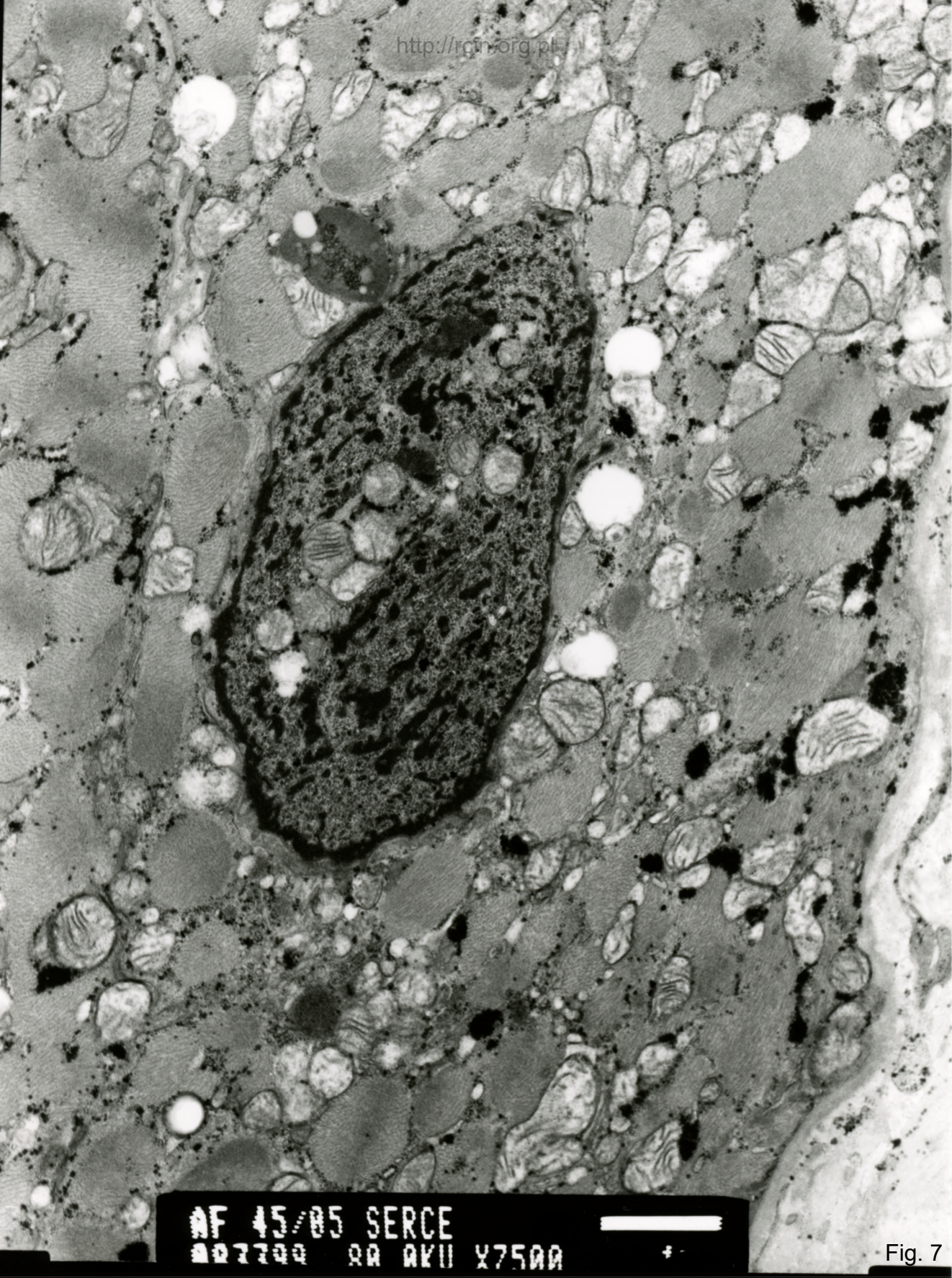

Fig. 7

Fig. 8

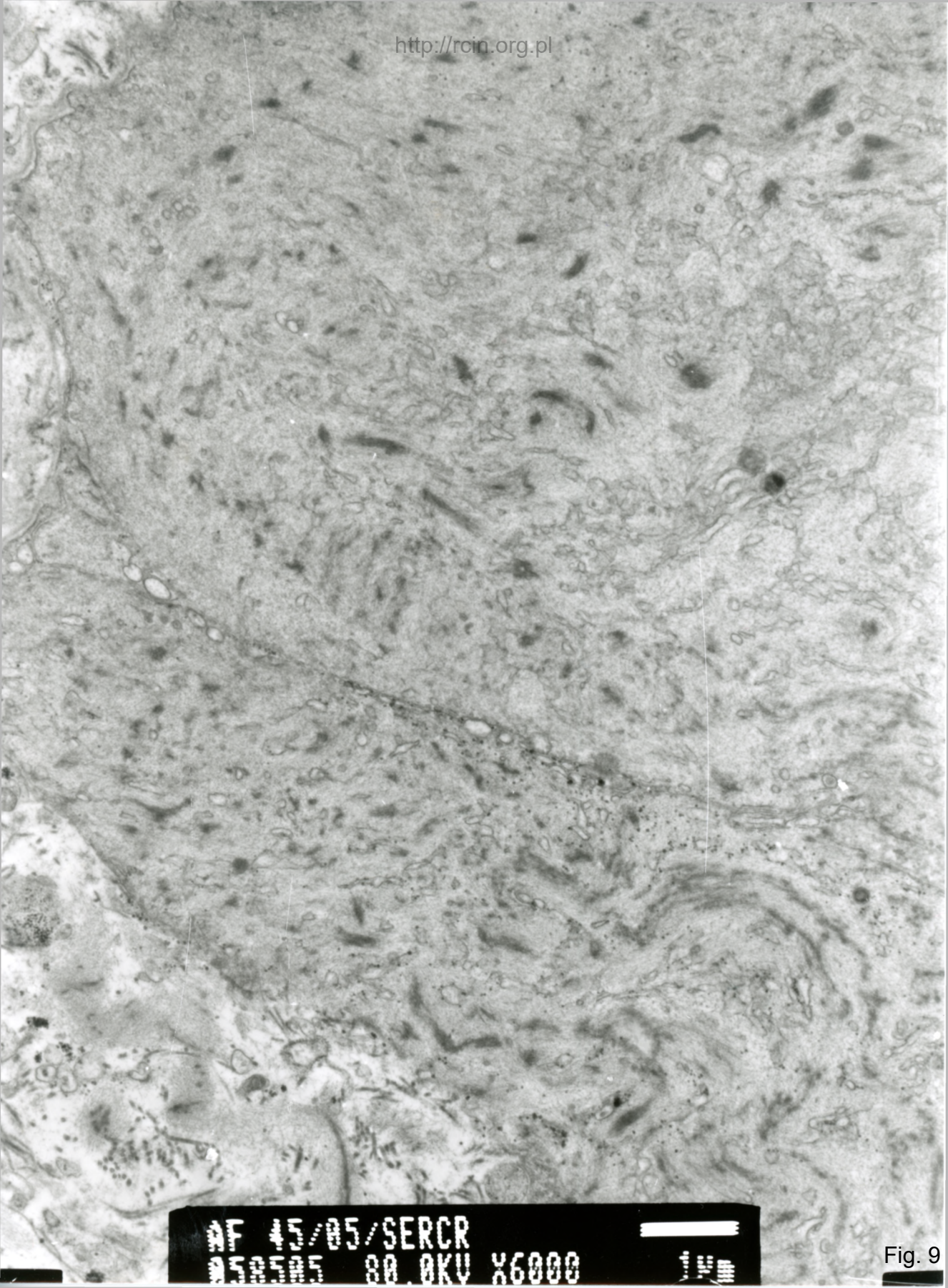

Fig. 9

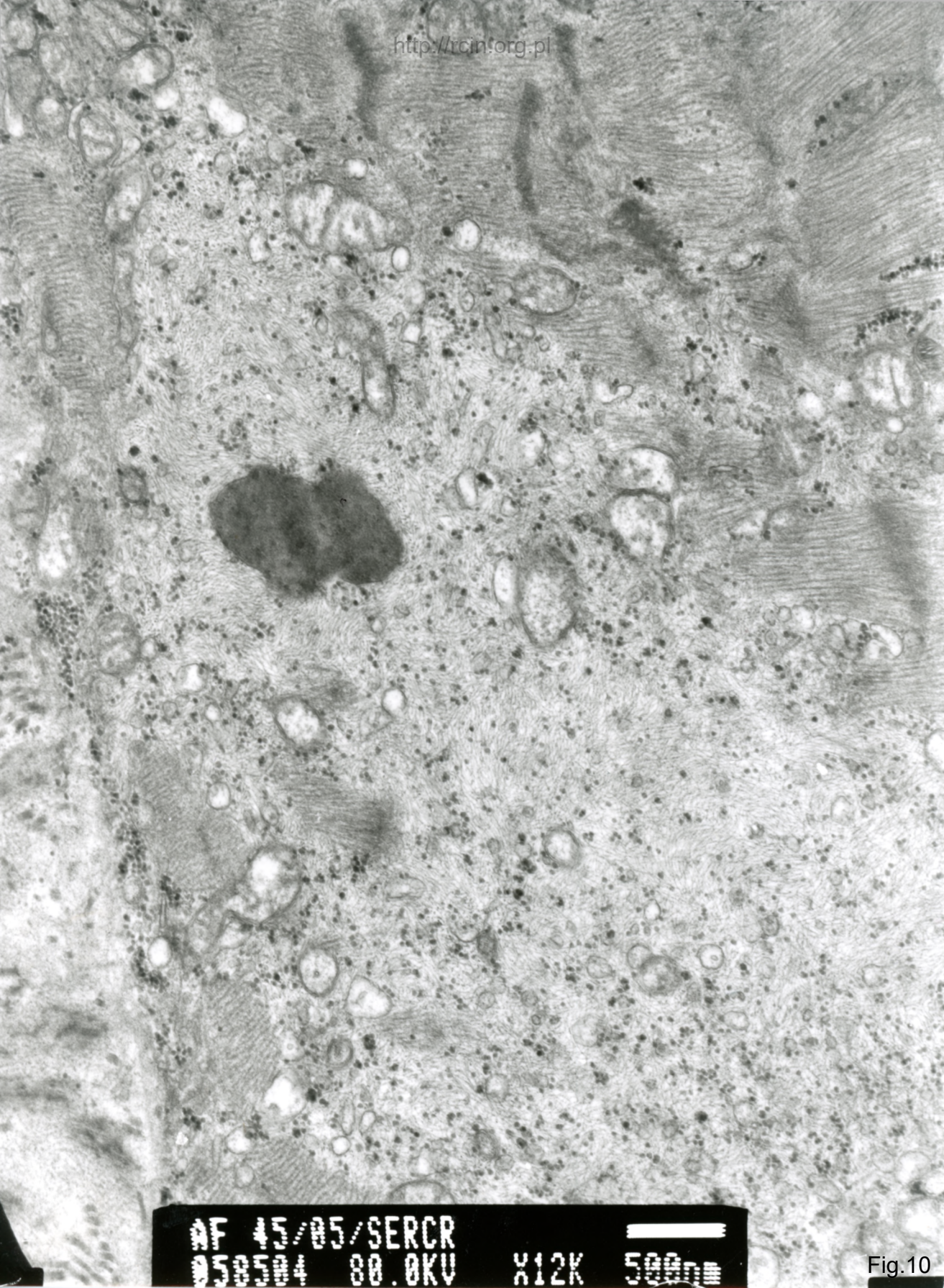

Fig.10

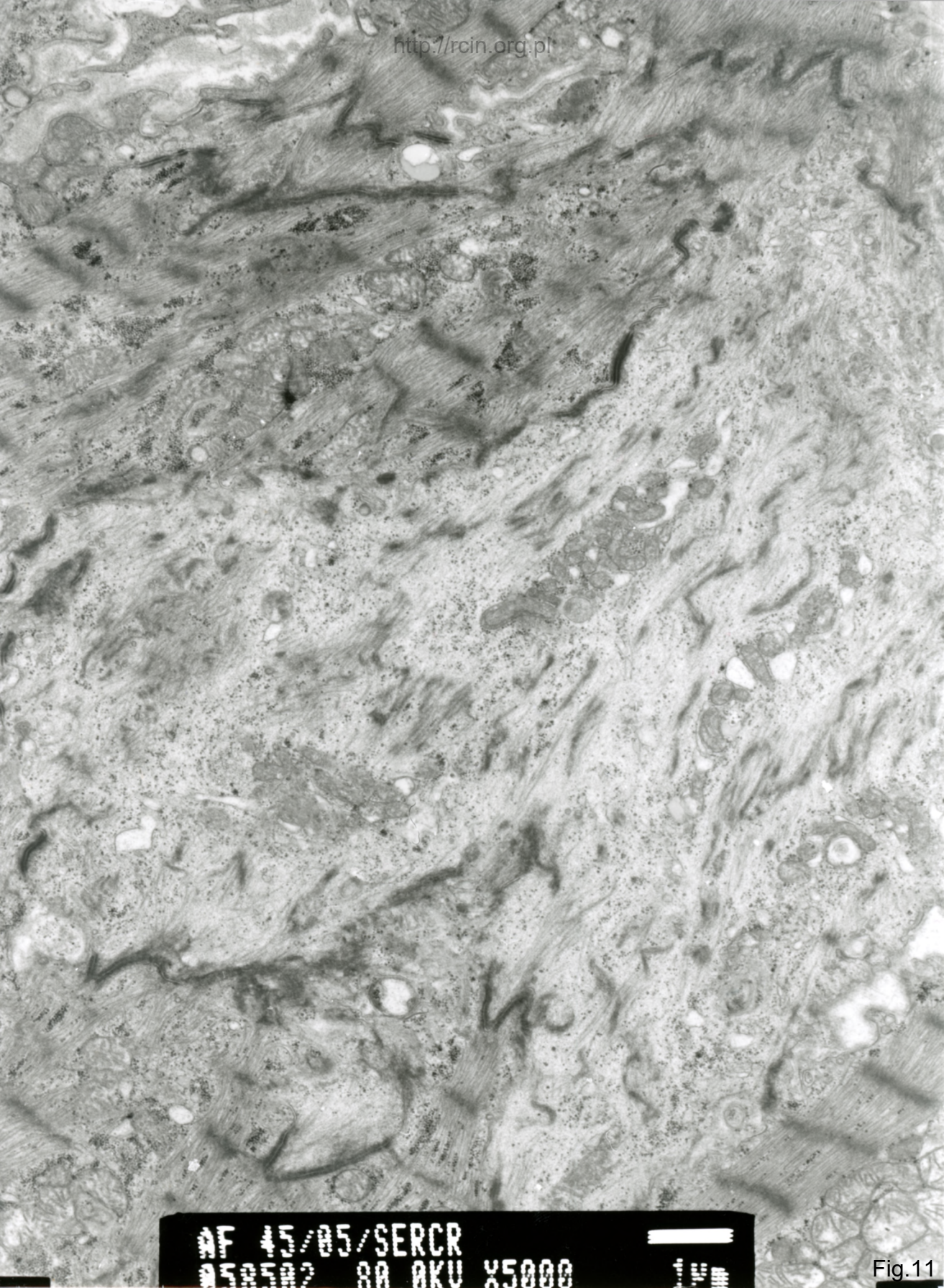

Fig.11

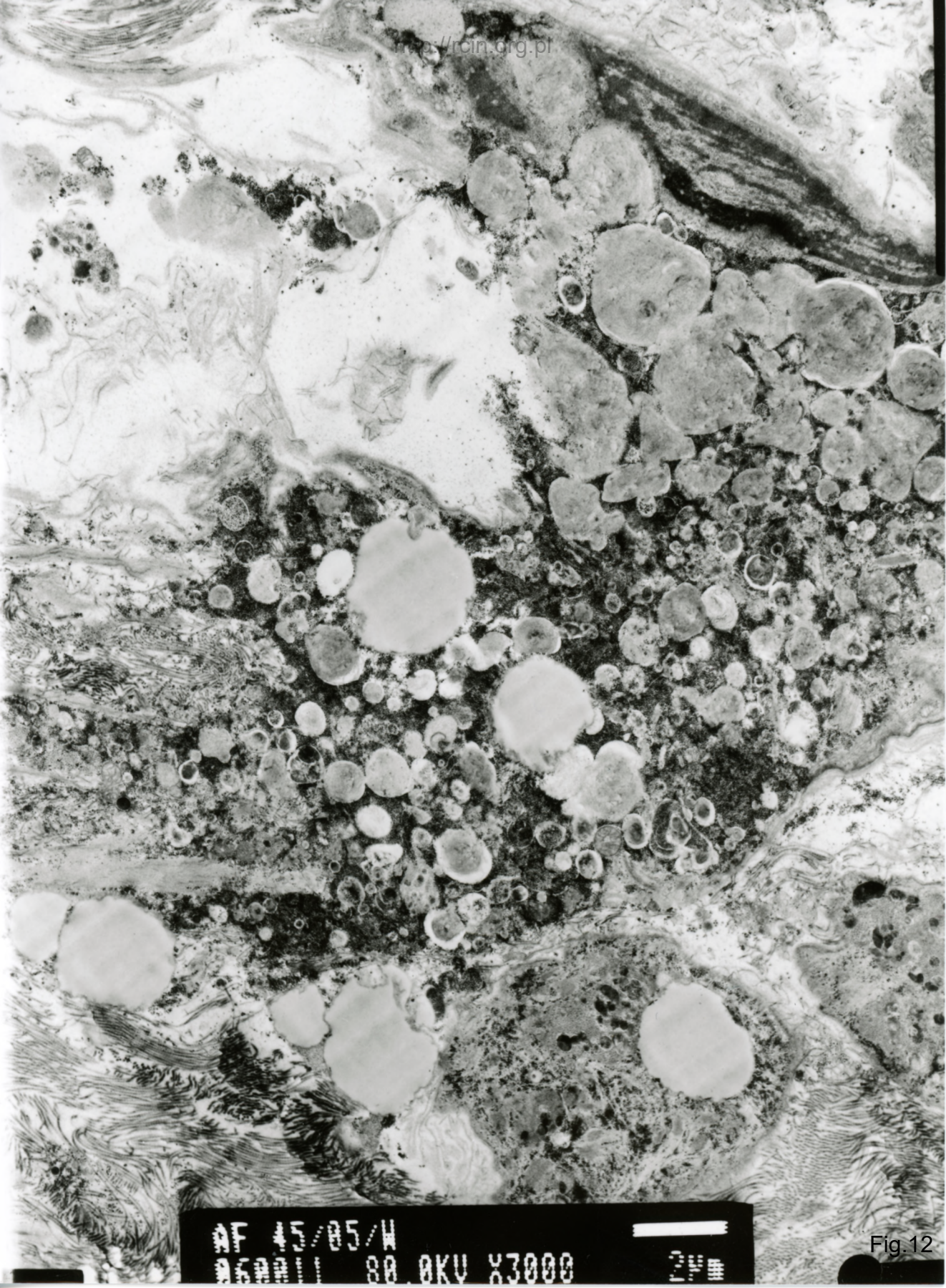

Fig.12

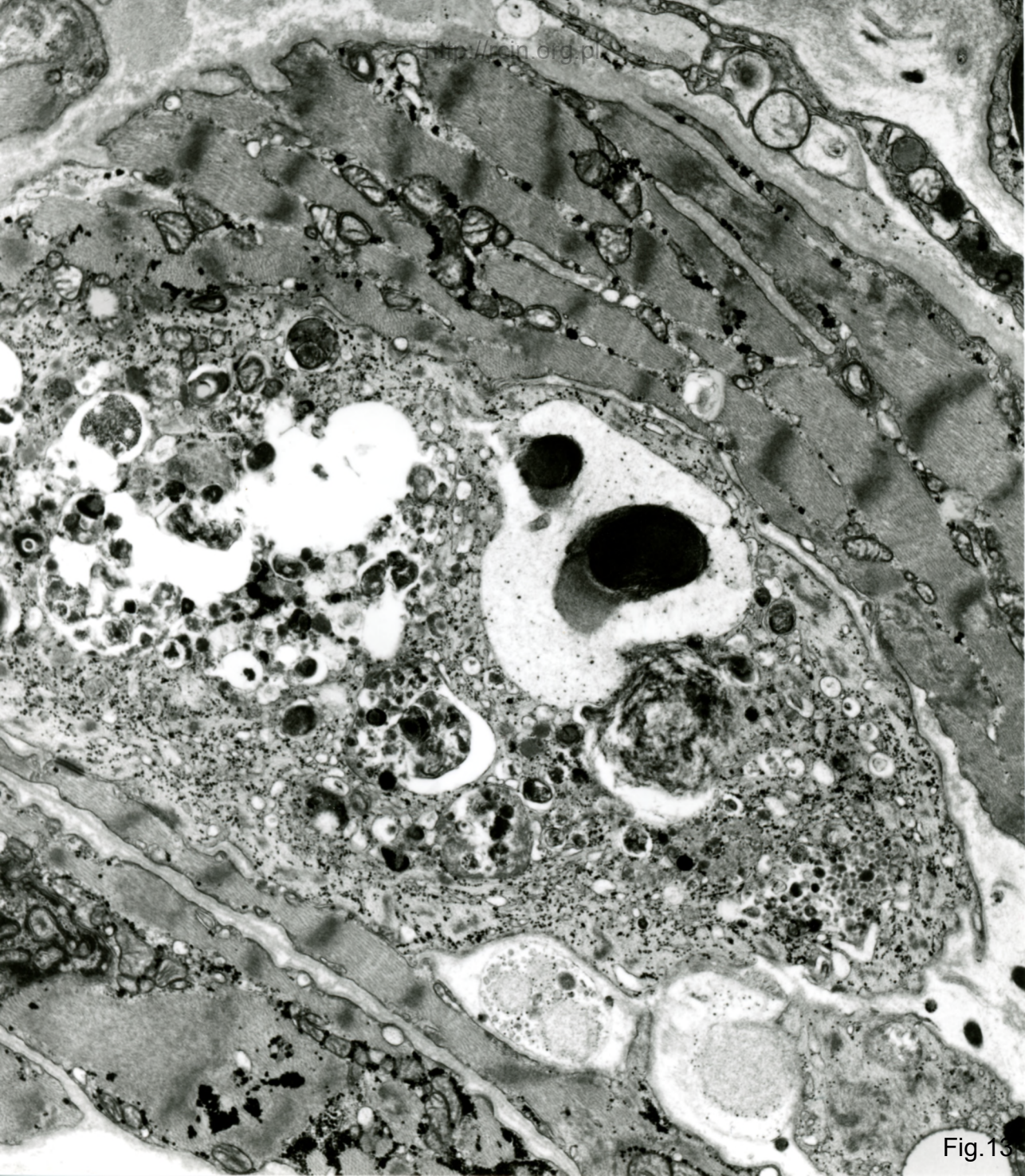

Fig.13

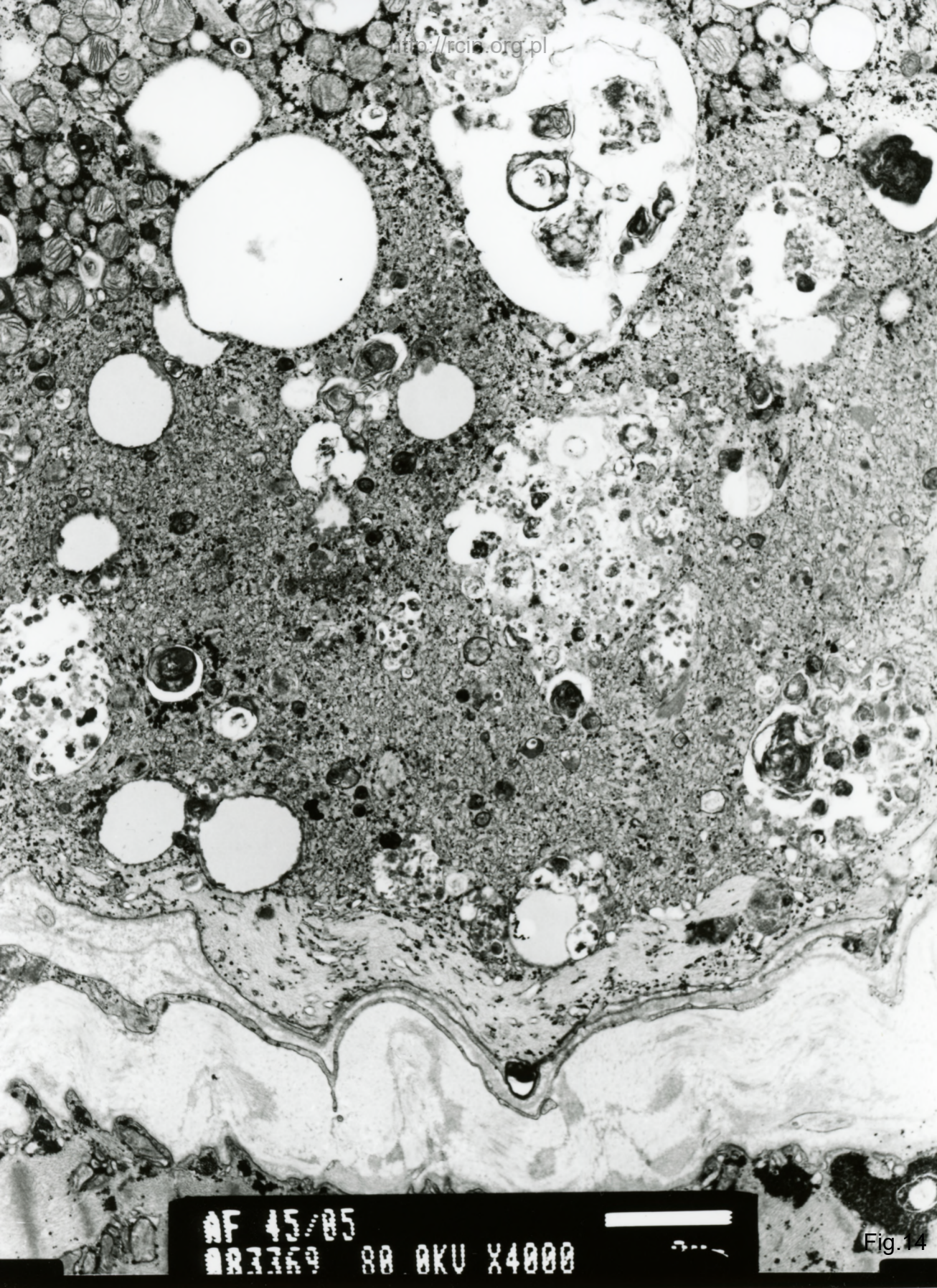

Fig.14

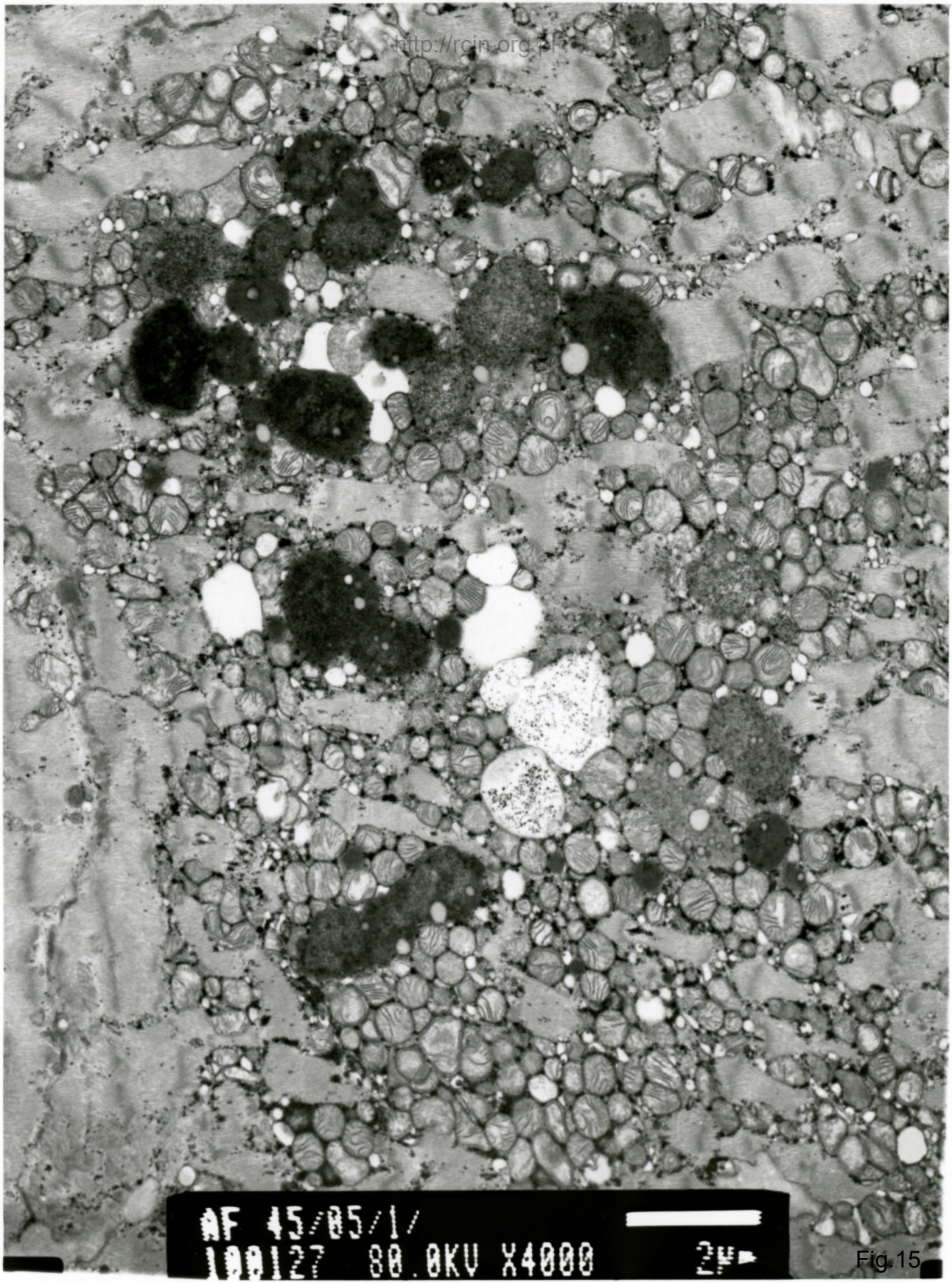

Fig.15

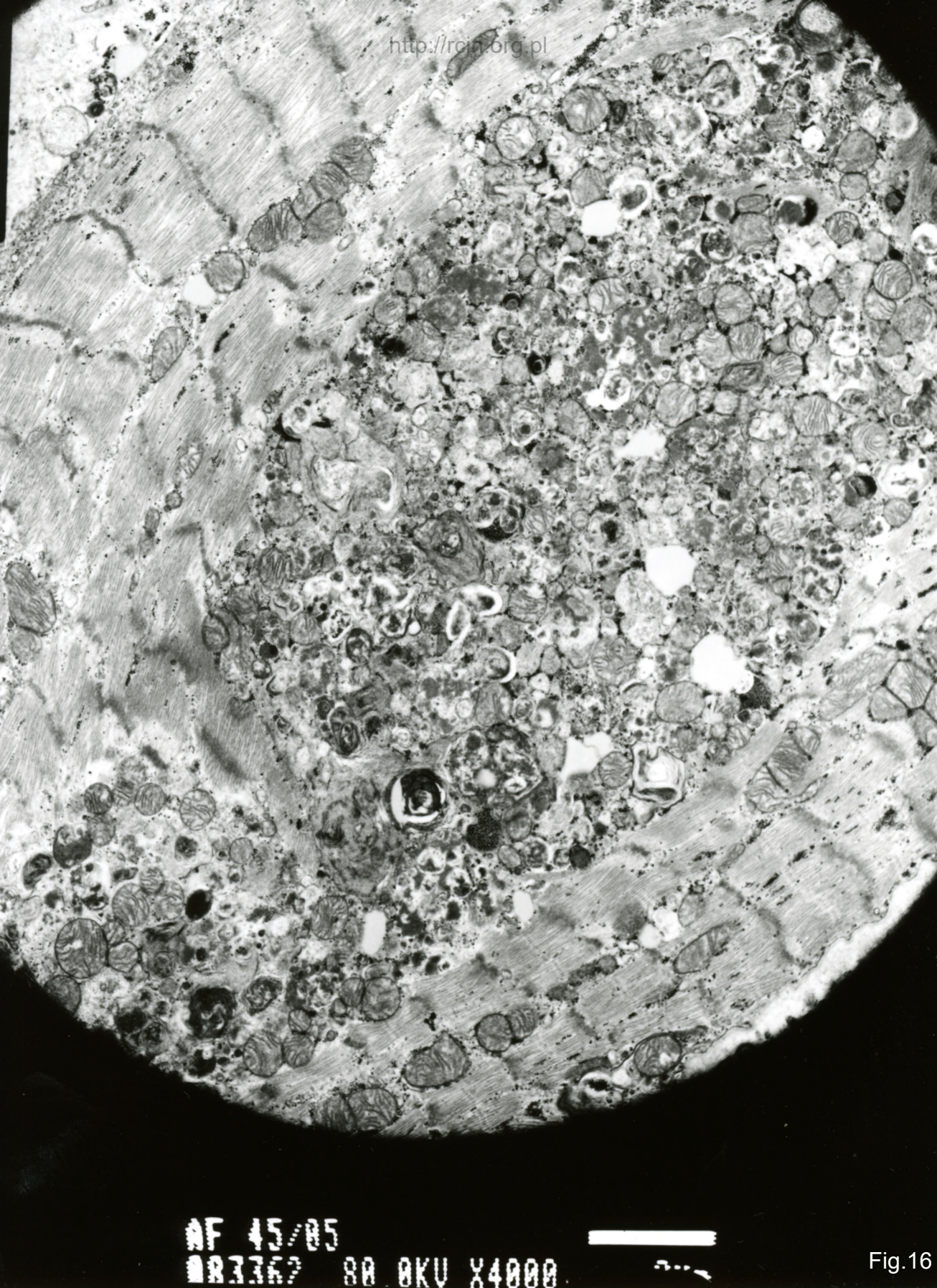

Fig.16

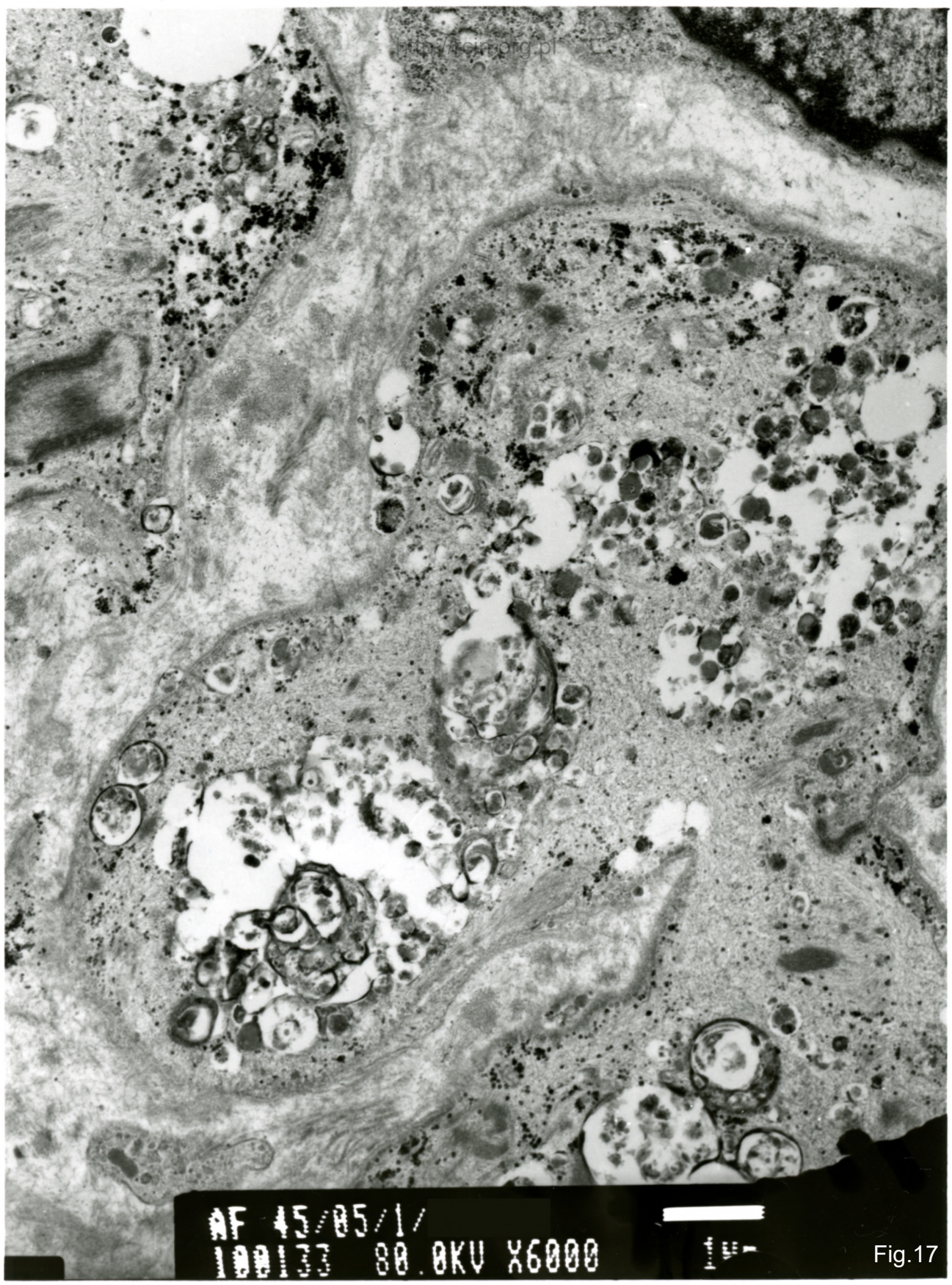

Fig.17

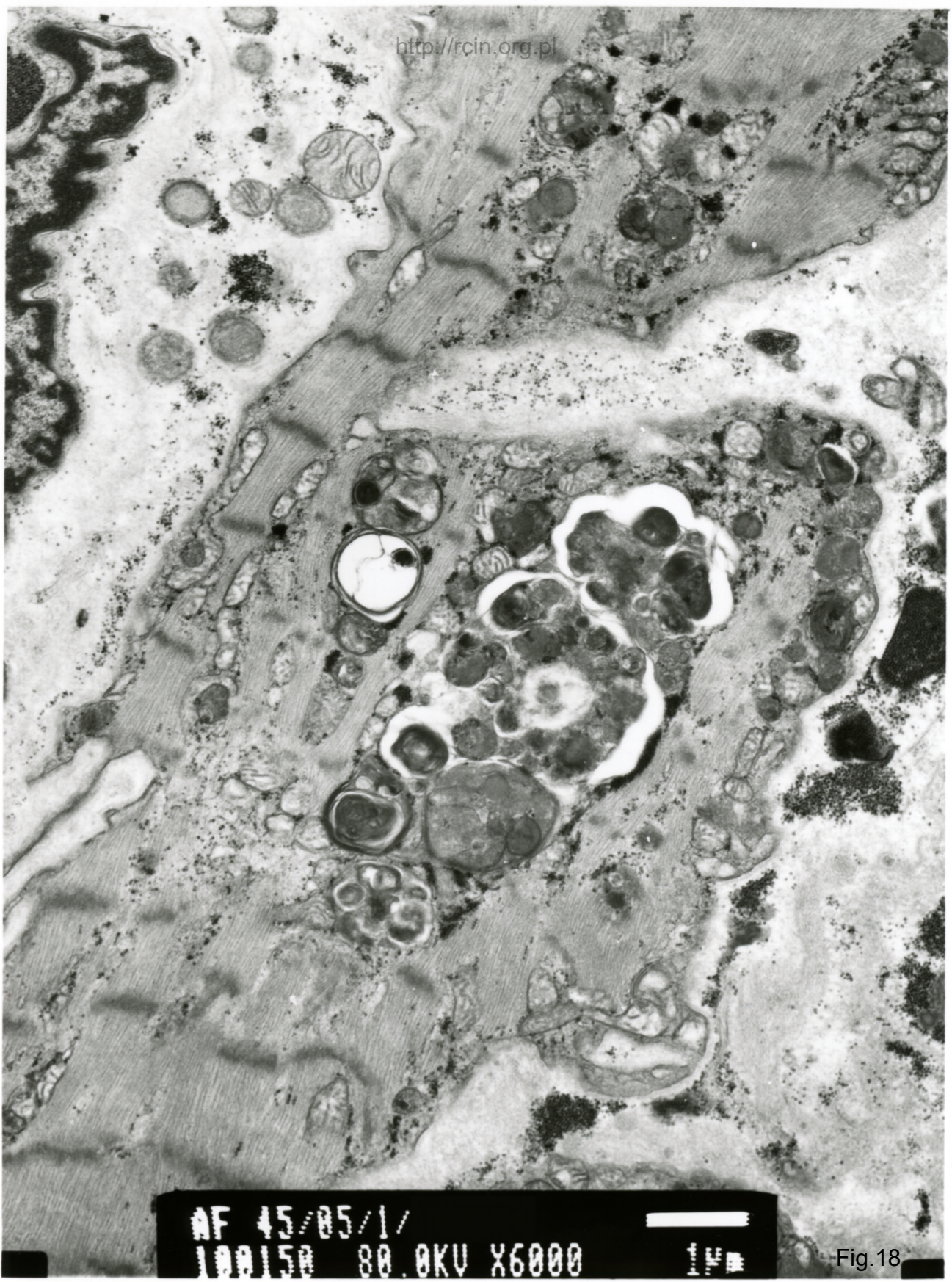

Fig.18

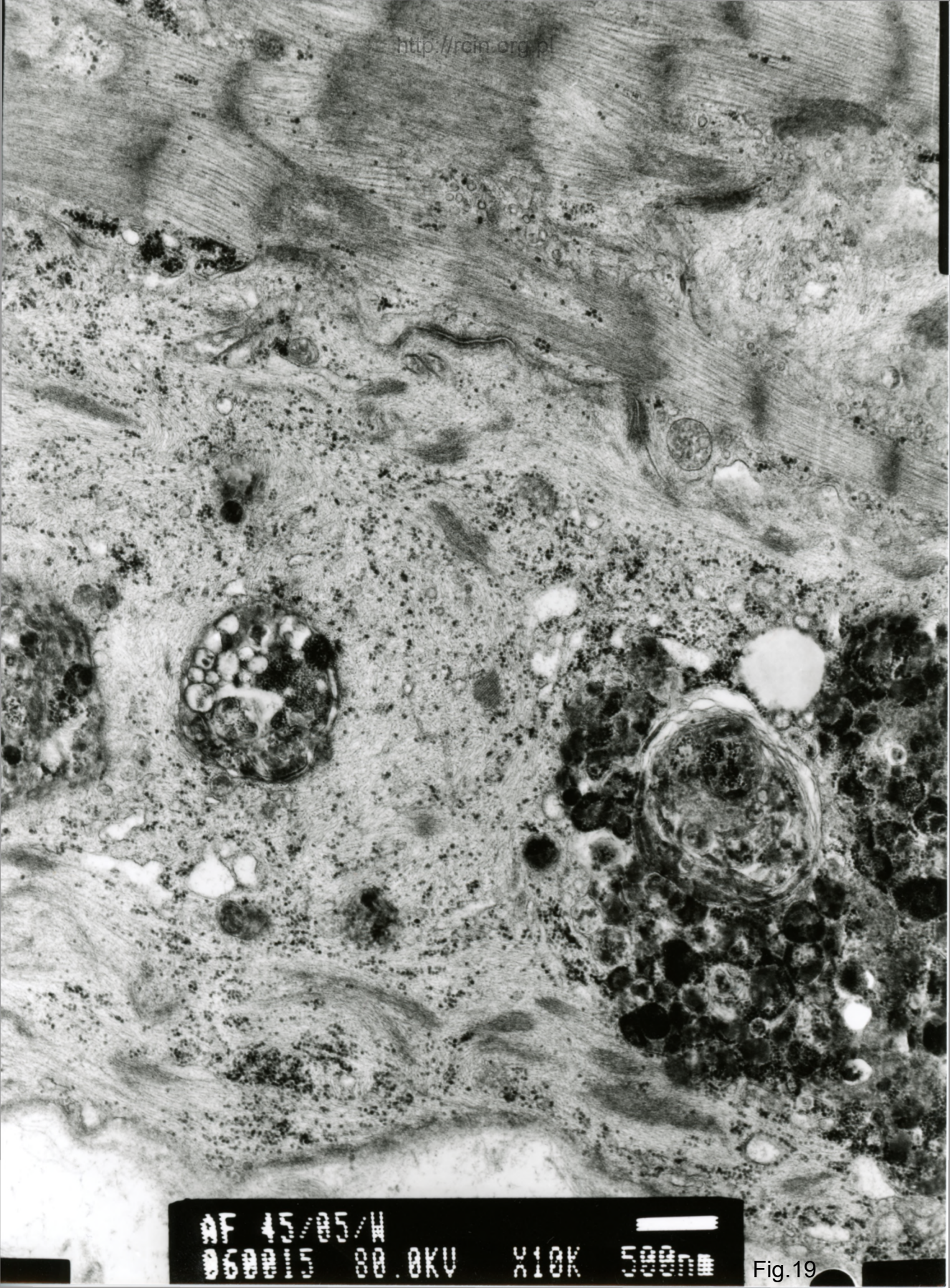

Fig.19

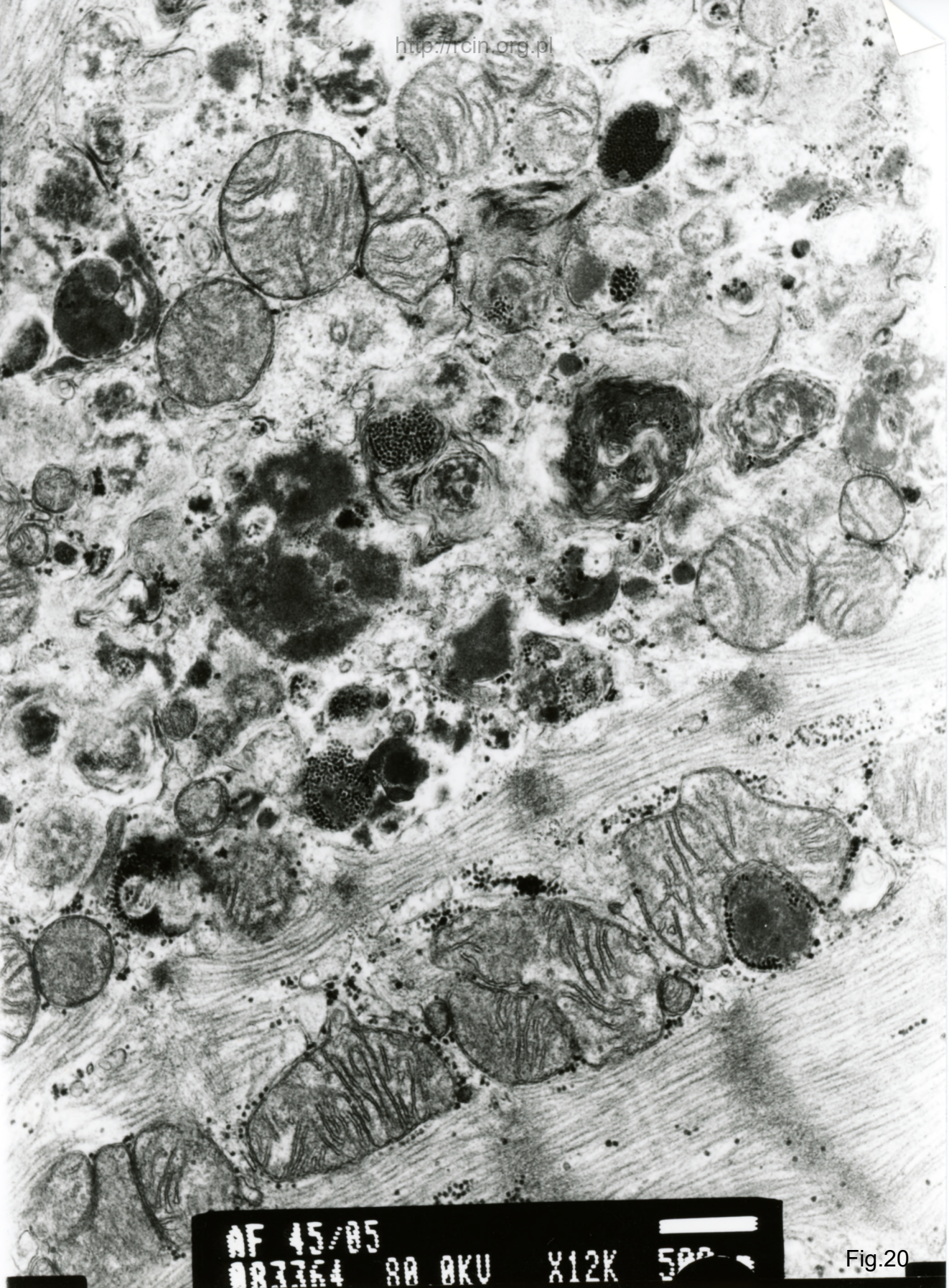

Fig.20

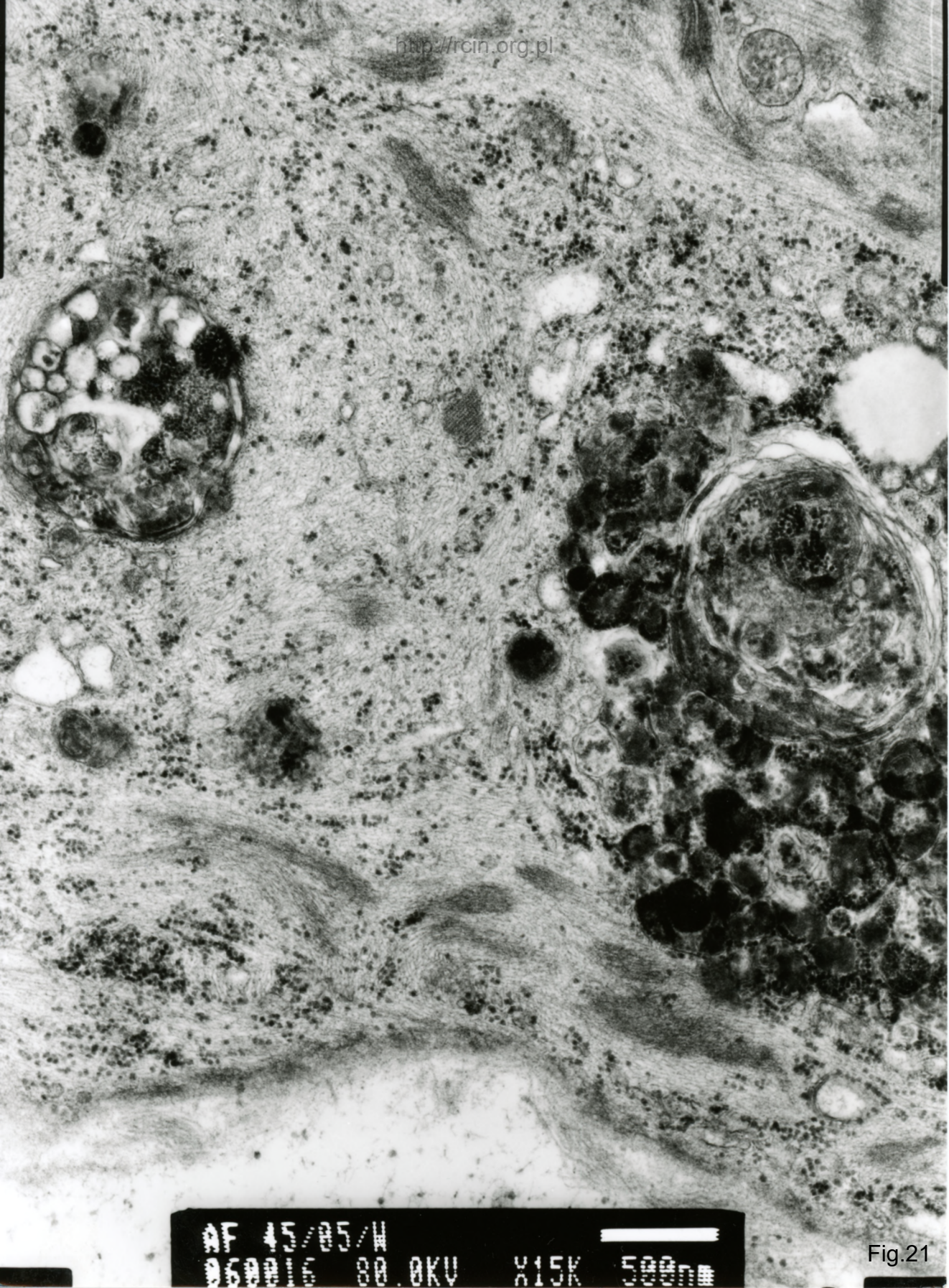

Fig.21

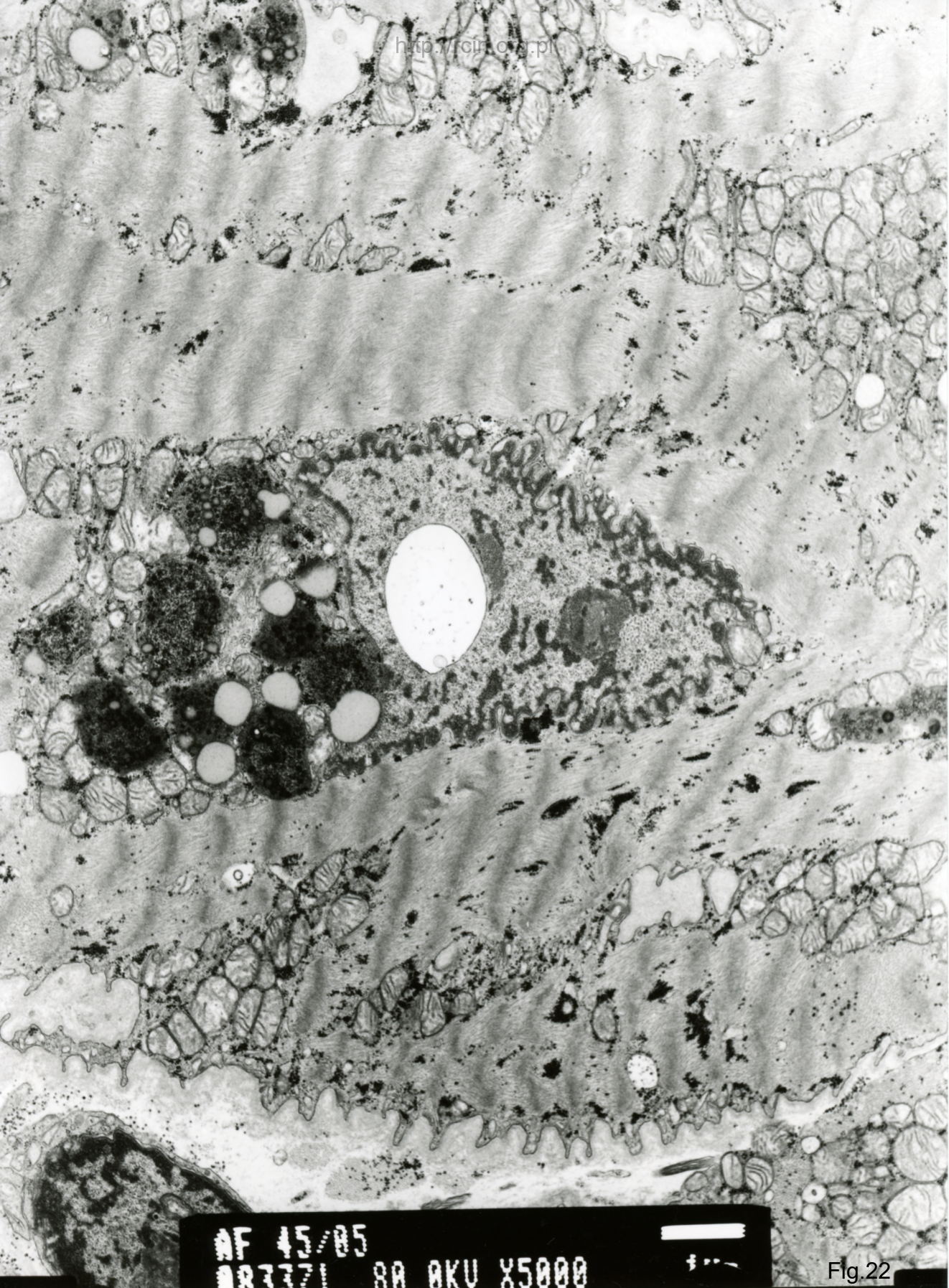

Fig.22

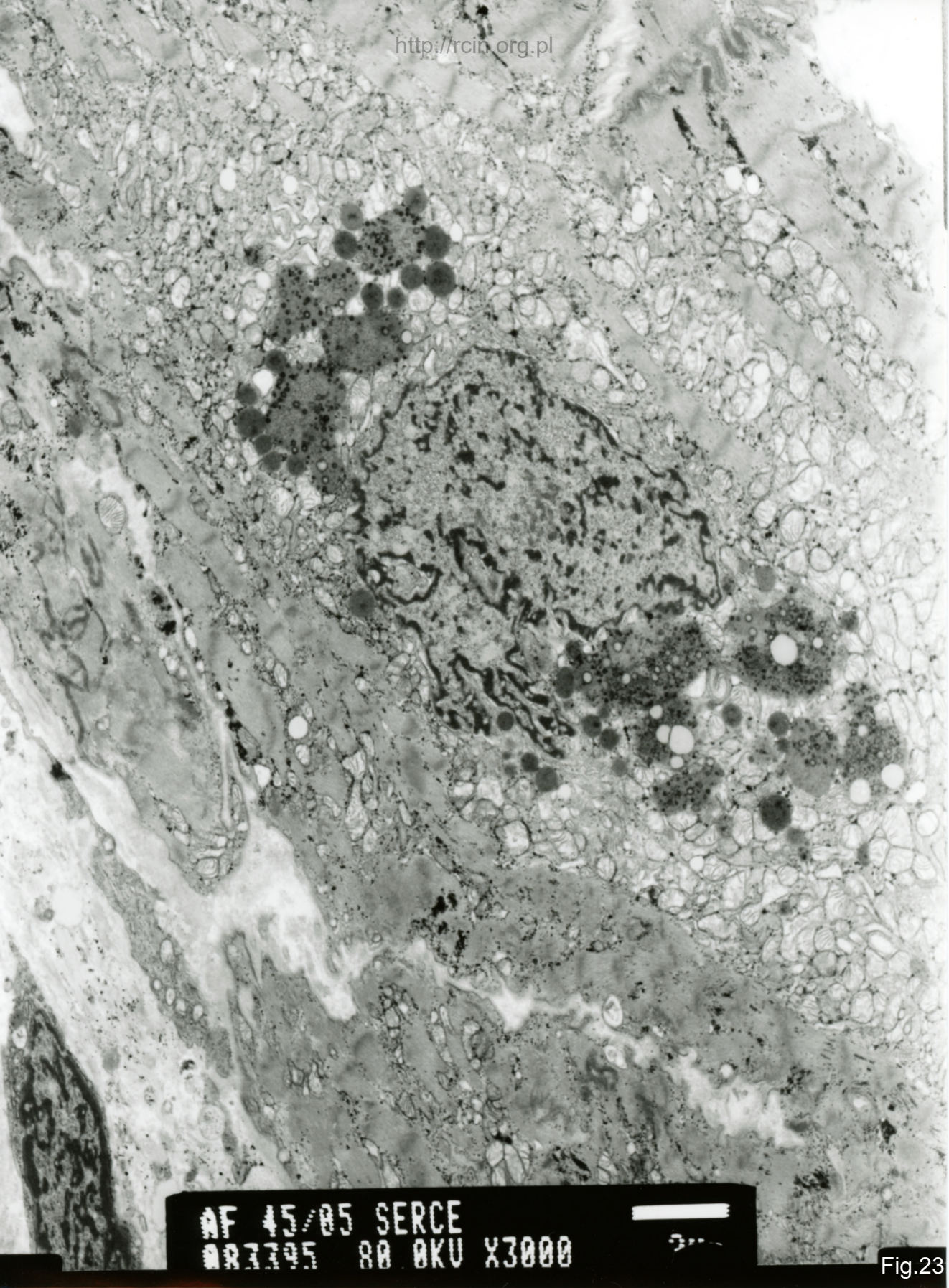

Fig.23

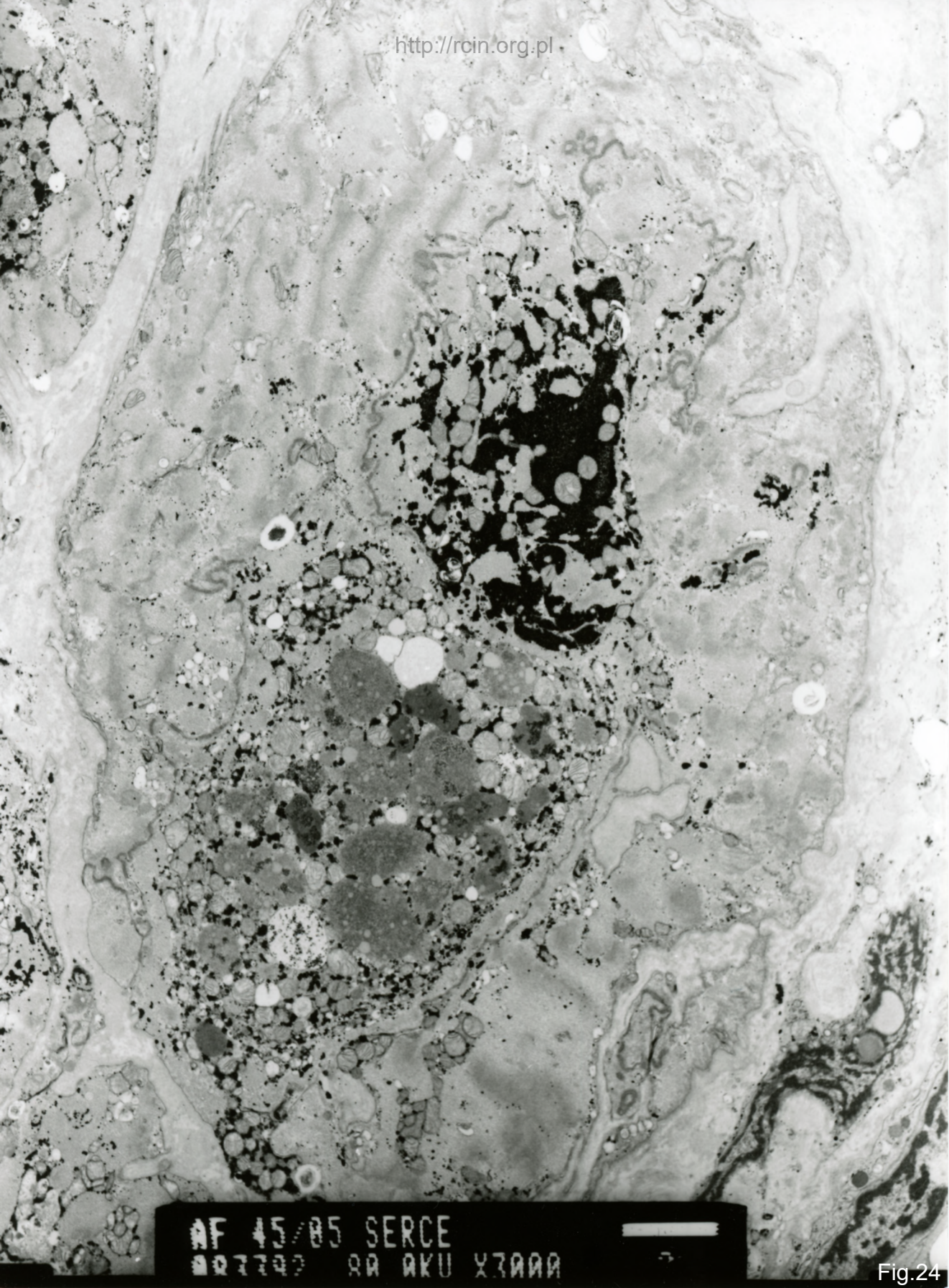

Fig.24

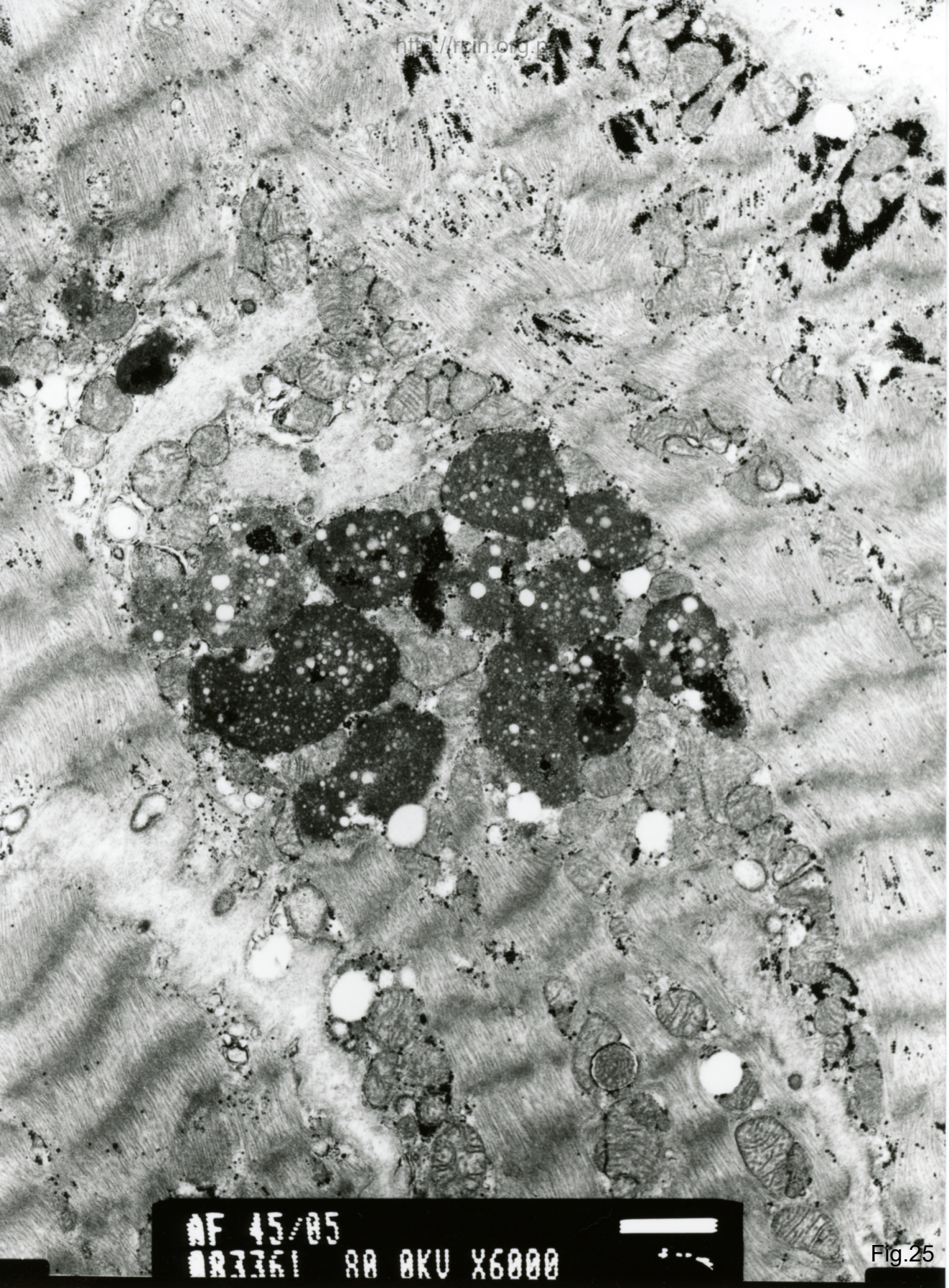

Fig.25

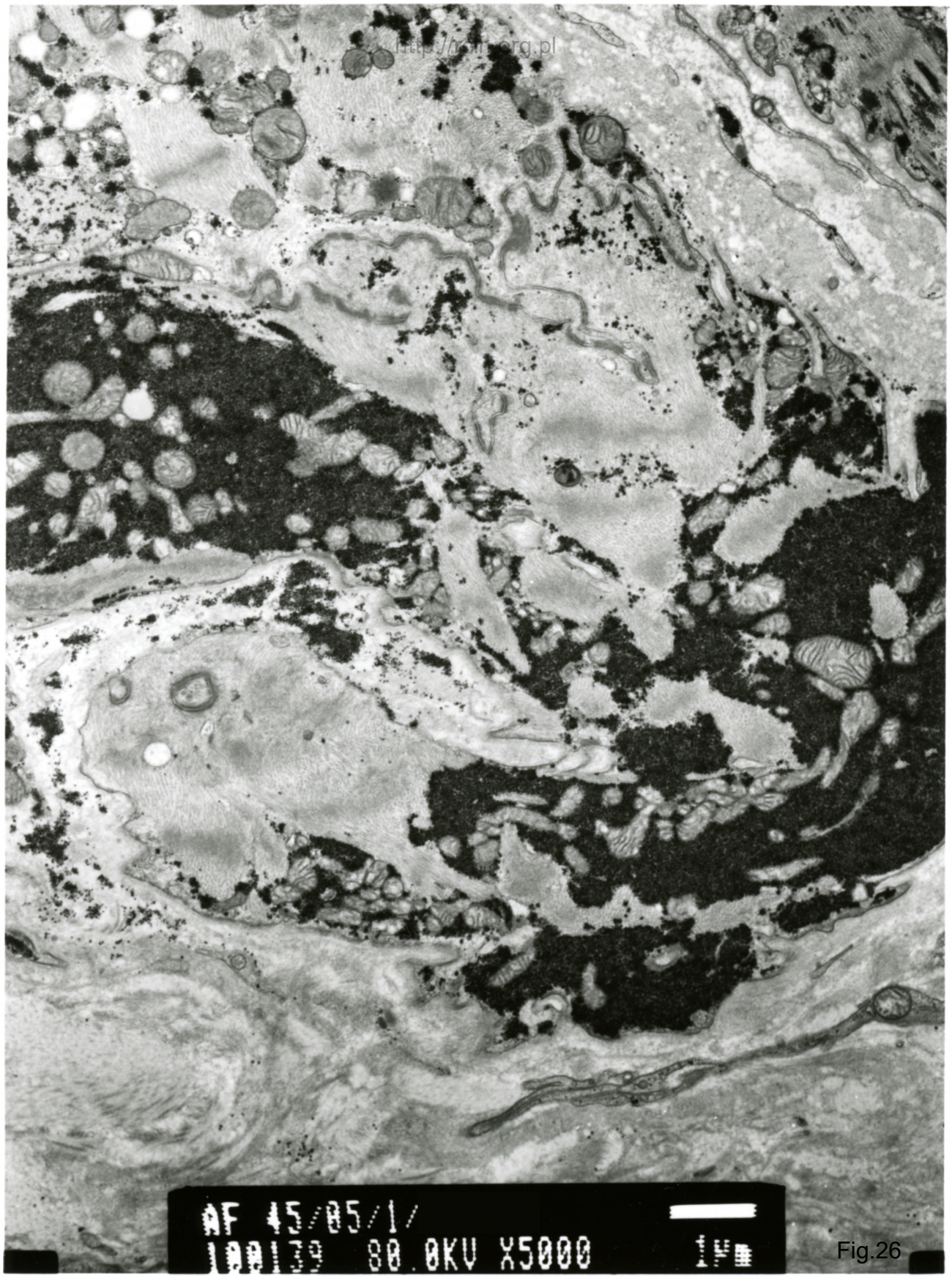

Fig.26

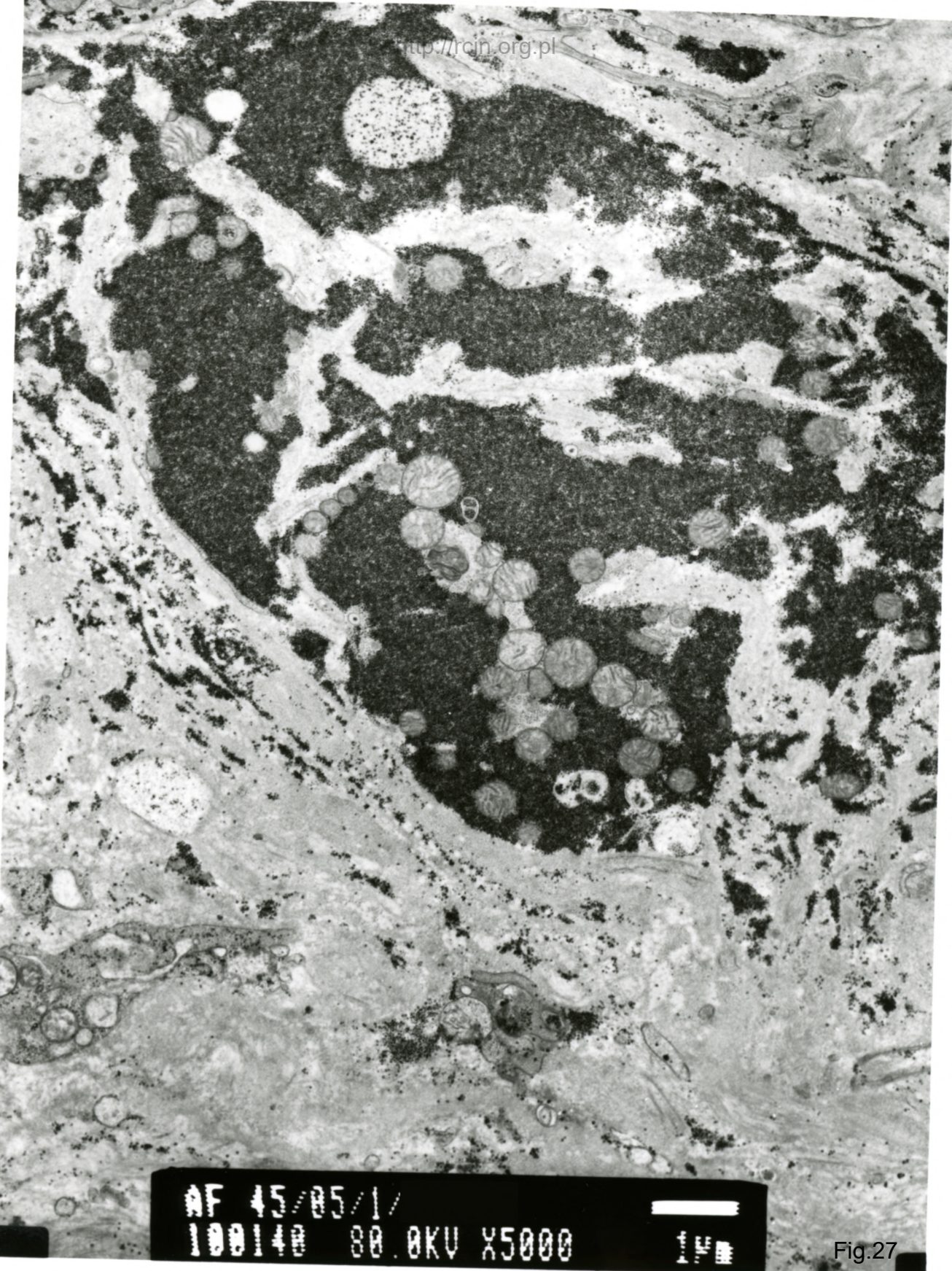

Fig.27

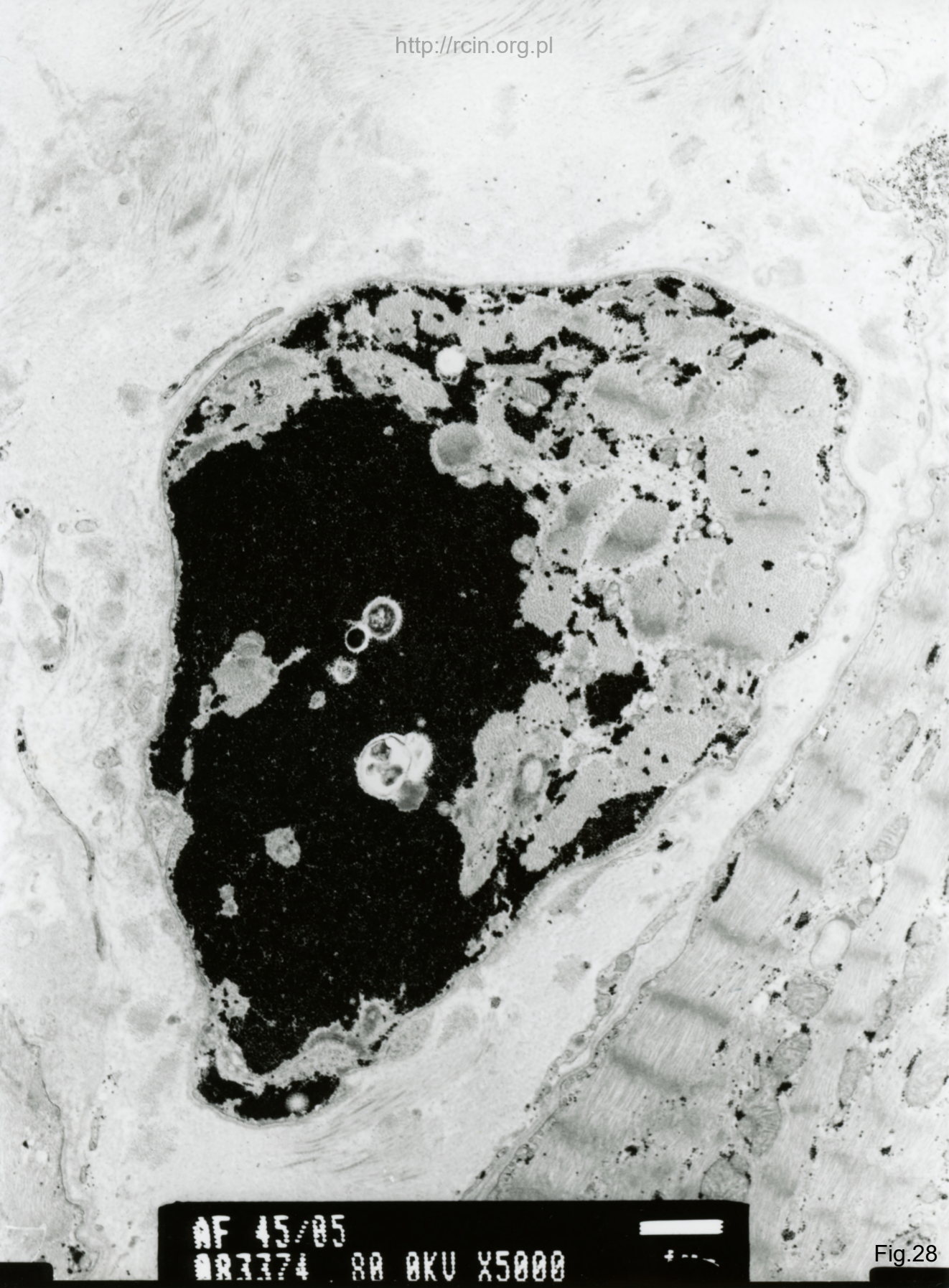

Fig.28

Fig.29

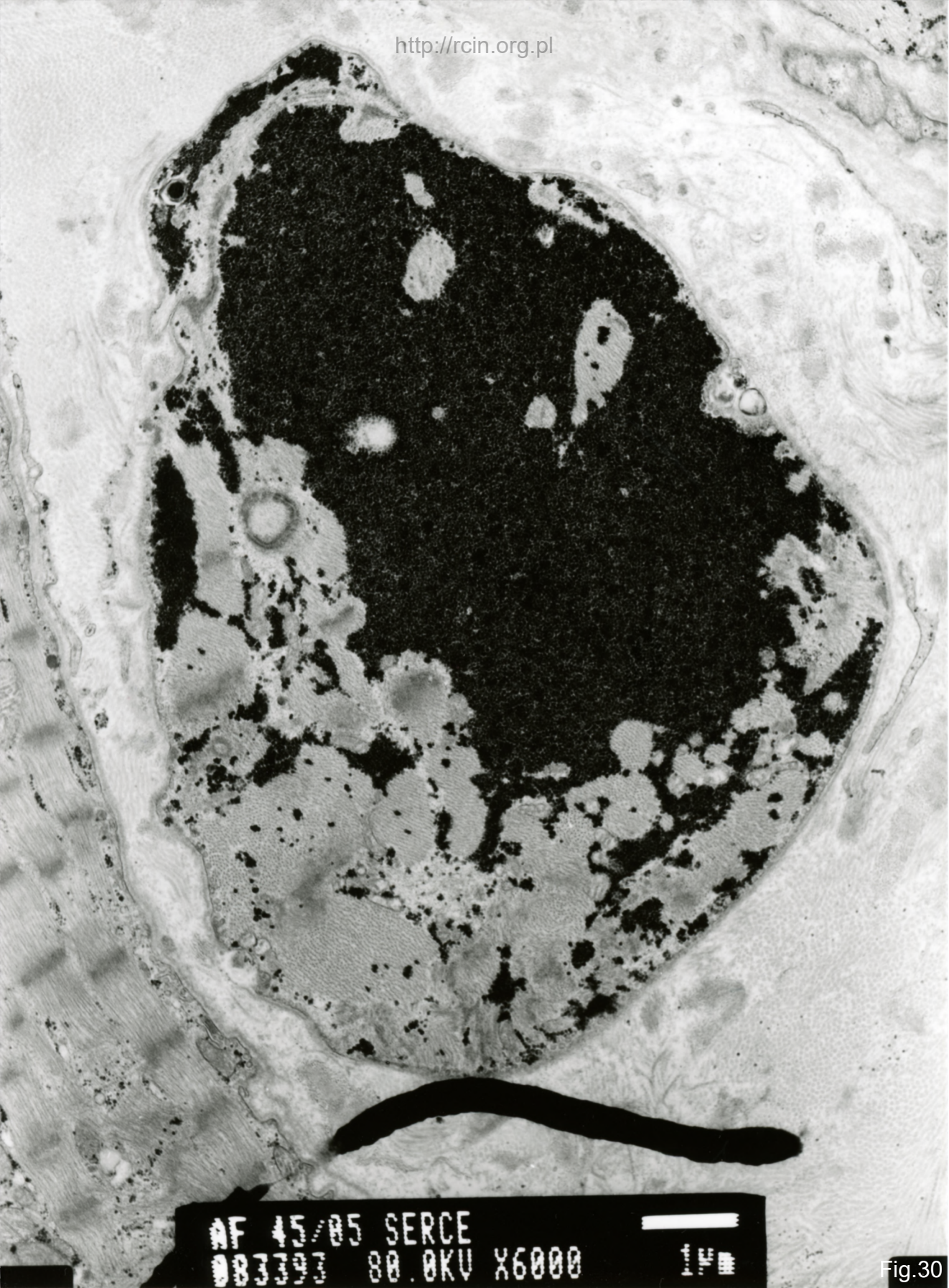

Fig.30

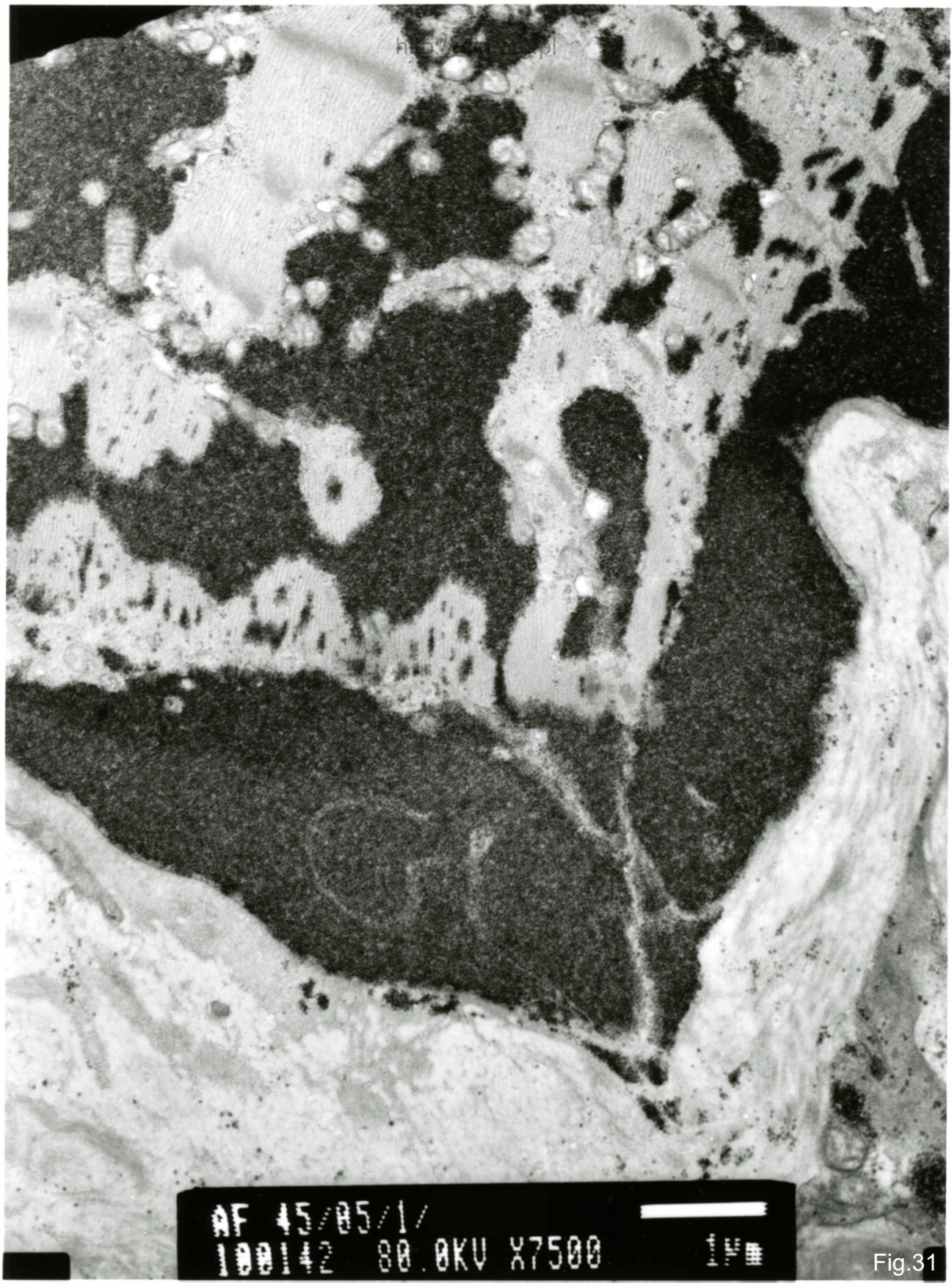

Fig.31

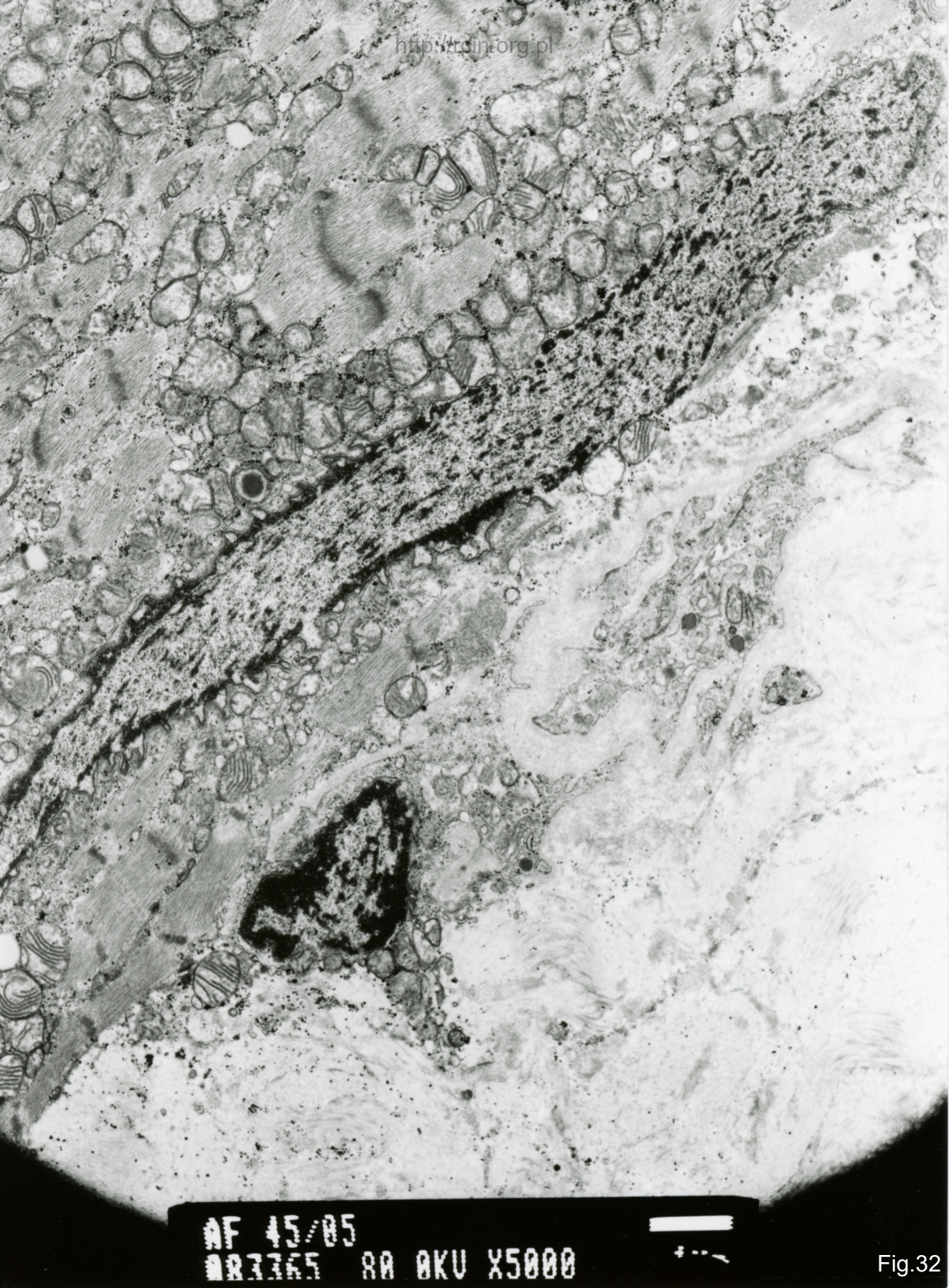

Fig.32

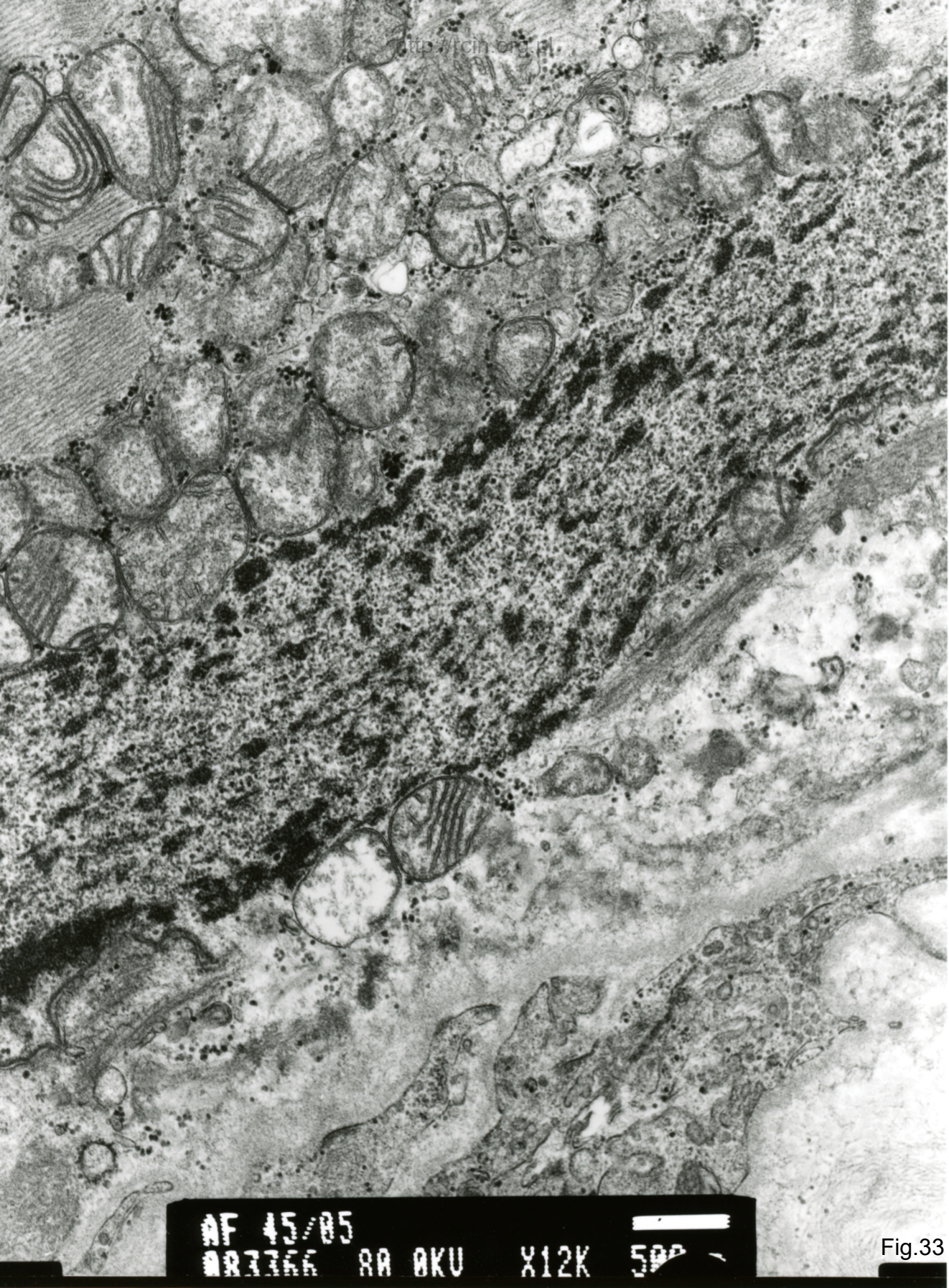

Fig.33



Fig.34

45/05

l. 32

Podejrzenie amyloidozy/kardiomiopatii mitochondrialnej/zapalenia mięśnia sercowego

We fragmentach bioptatu widoczne zachowane miofibrylle i niezmieniony układ sarkomerów obserwuje się jednak znaczną nukleopatię – jądra kardiomiocytów o nieprawidłowym kształcie, pofałdowanej otoczce a niektóre zawierające w swym wnętrzu organelle komórkowe (Fig. 1-8). Ocena ultrastrukturalna wykazała na pewnych obszarach zaburzenia w układzie sarkomerowym i w przebiegu miofilamentów oraz ich dezorganizację (Fig. 9,10,11). Obserwowano licznie występujące struktury autofagalne (Fig. 12-21) oraz złogi lipofuscyny, obecne zwłaszcza w pobliżu jąder kardiomiocytów (Fig. 22-25). W bioptacie widoczne były fragmenty tkanki o znacznym nagromadzeniu glikogenu (Fig. 26-31). Niektóre mitochondria charakteryzowały się jasną macierzą mitochondrialną i ubytkiem grzebieni bądź ich nieprawidłowym przebiegiem (Fig. 32,33,34).

Suspected amyloidosis / mitochondrial cardiomyopathy / myocarditis

Electronmicroscopy evaluation revealed in some parts of the biopsy the presence of preserved myofibrils and an unchanged sarcomeres pattern, however, a significant nucleopathy was observed. Cardiomyocyte nuclei were characterized by abnormal shape and some of them by discontinuity of the nuclear membrane and contained cellular organelles inside (Figs. 1-8). Focal changes in the course of myofilaments and their disorganization as well as changes in sarcomere pattern were observed (Figs. 9,10,11). Numerous autophagous structures were seen (Figs. 12-21) Also some lipofuscin deposits, especially in the vicinity of cardiomyocyte nuclei were noticed (Figs. 22-25). The biopsy analyses showed tissue fragments with significant glycogen accumulation (Figs. 26-31). Some mitochondria were characterized by a bright mitochondrial matrix and a loss or abnormal course of mitochondrial cristae (Figs. 32,33,34).