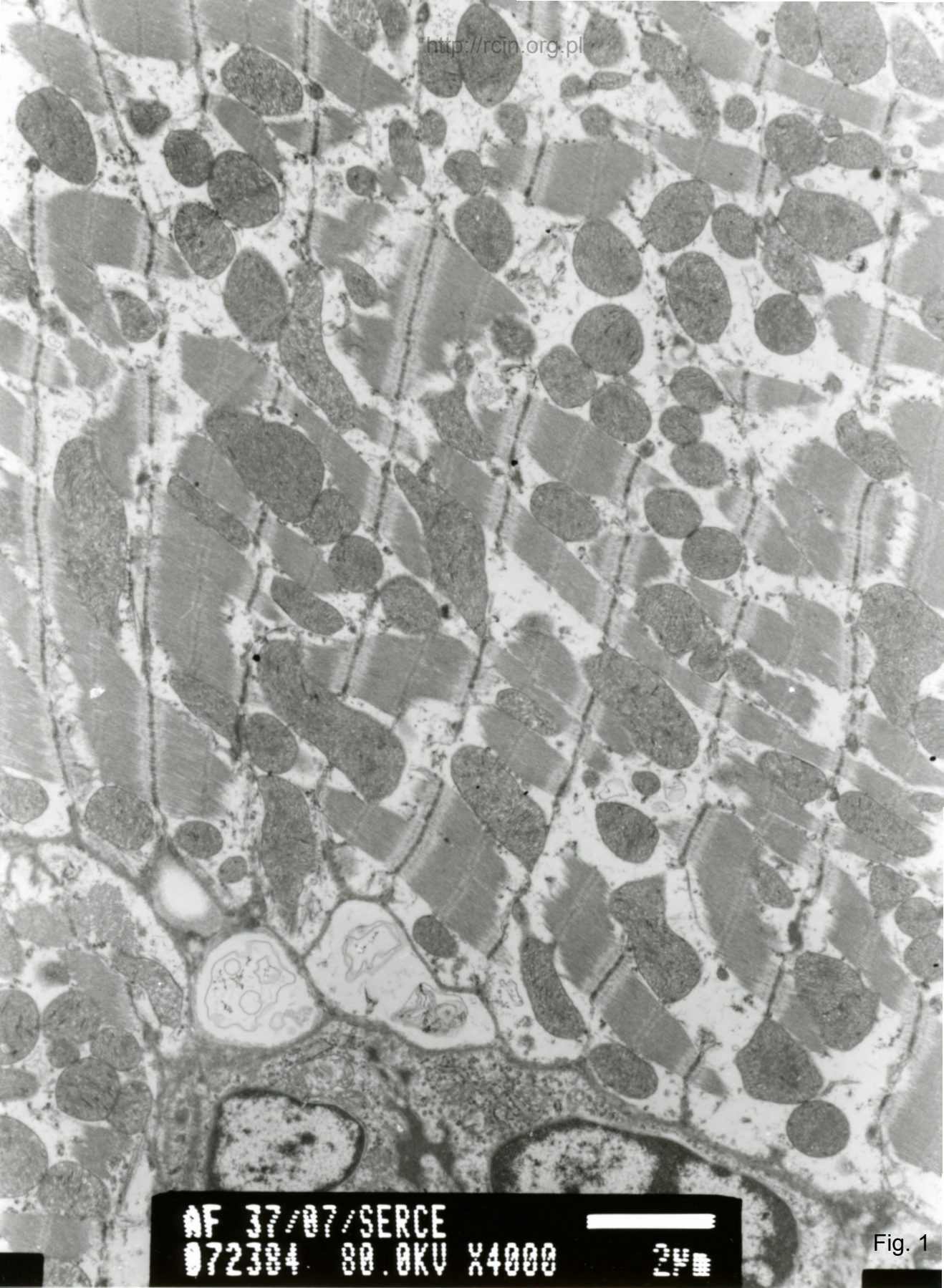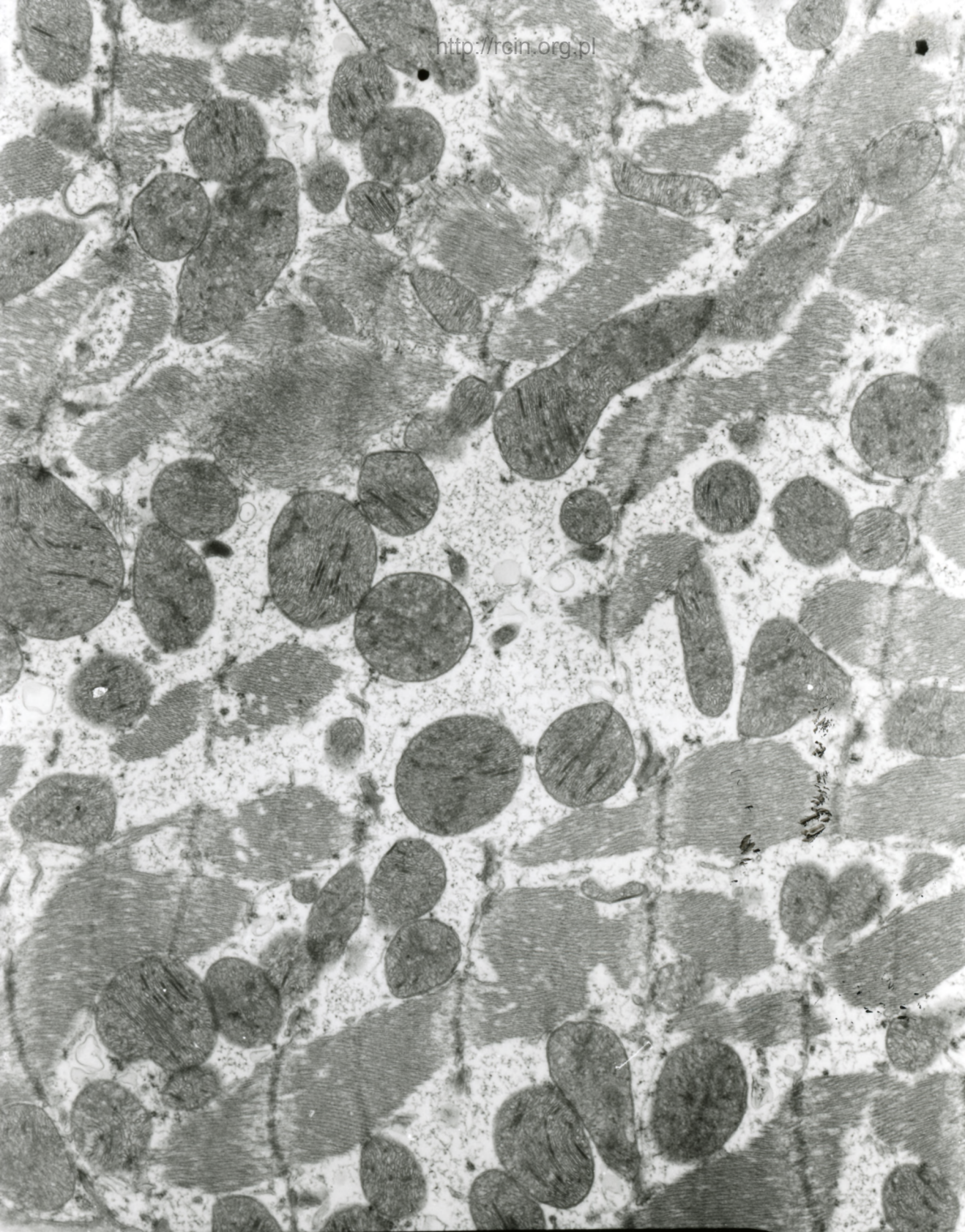


AF 37/07/SERCE
072304 80.0KV X4000



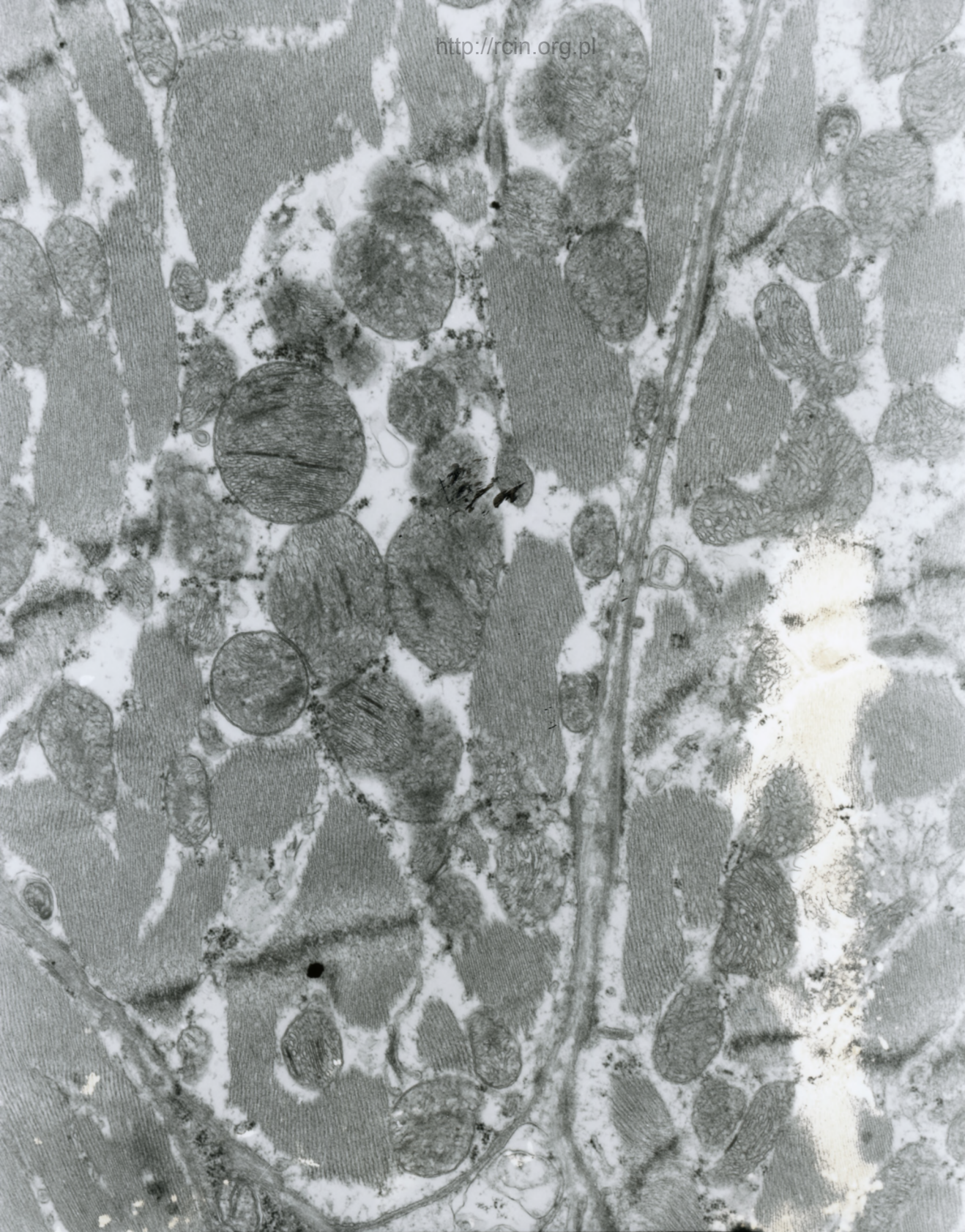
2µm

Fig. 1




AF 37/07/SERCE
072302 80.0KV X6000 1µm

Fig. 2

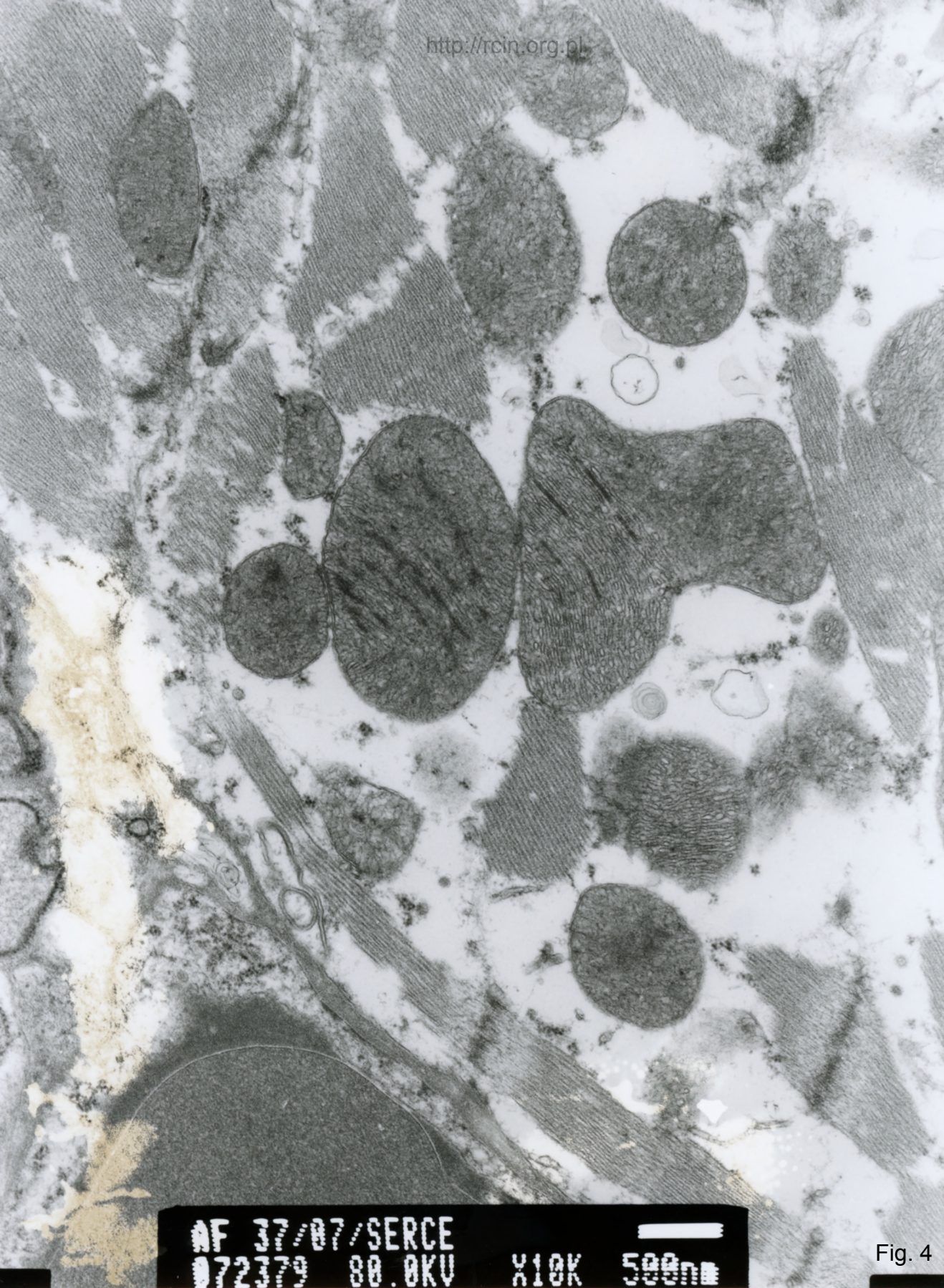


AF 37/07/SERCE
072300 80.0KV X7500



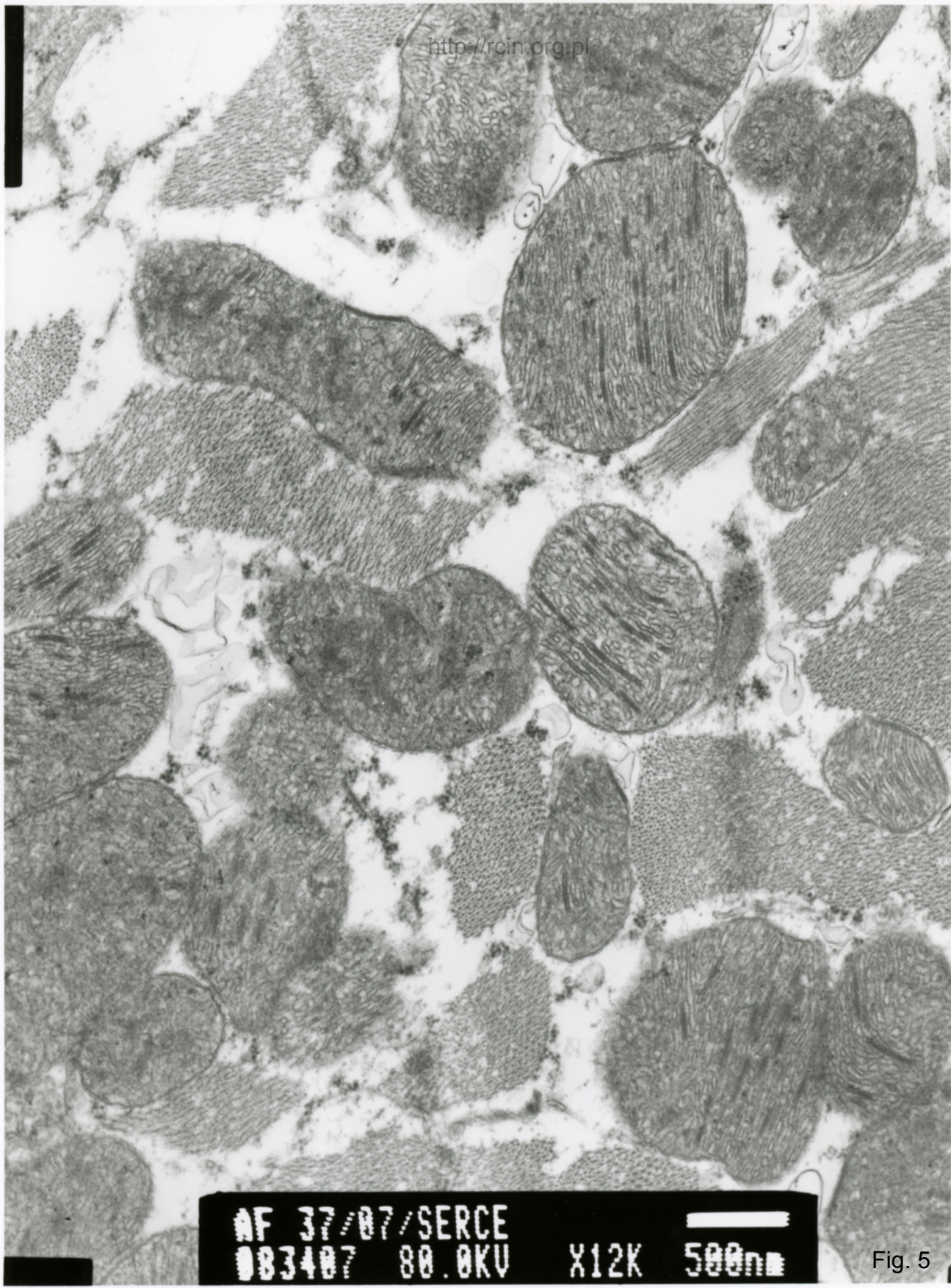
1 μm

Fig. 3



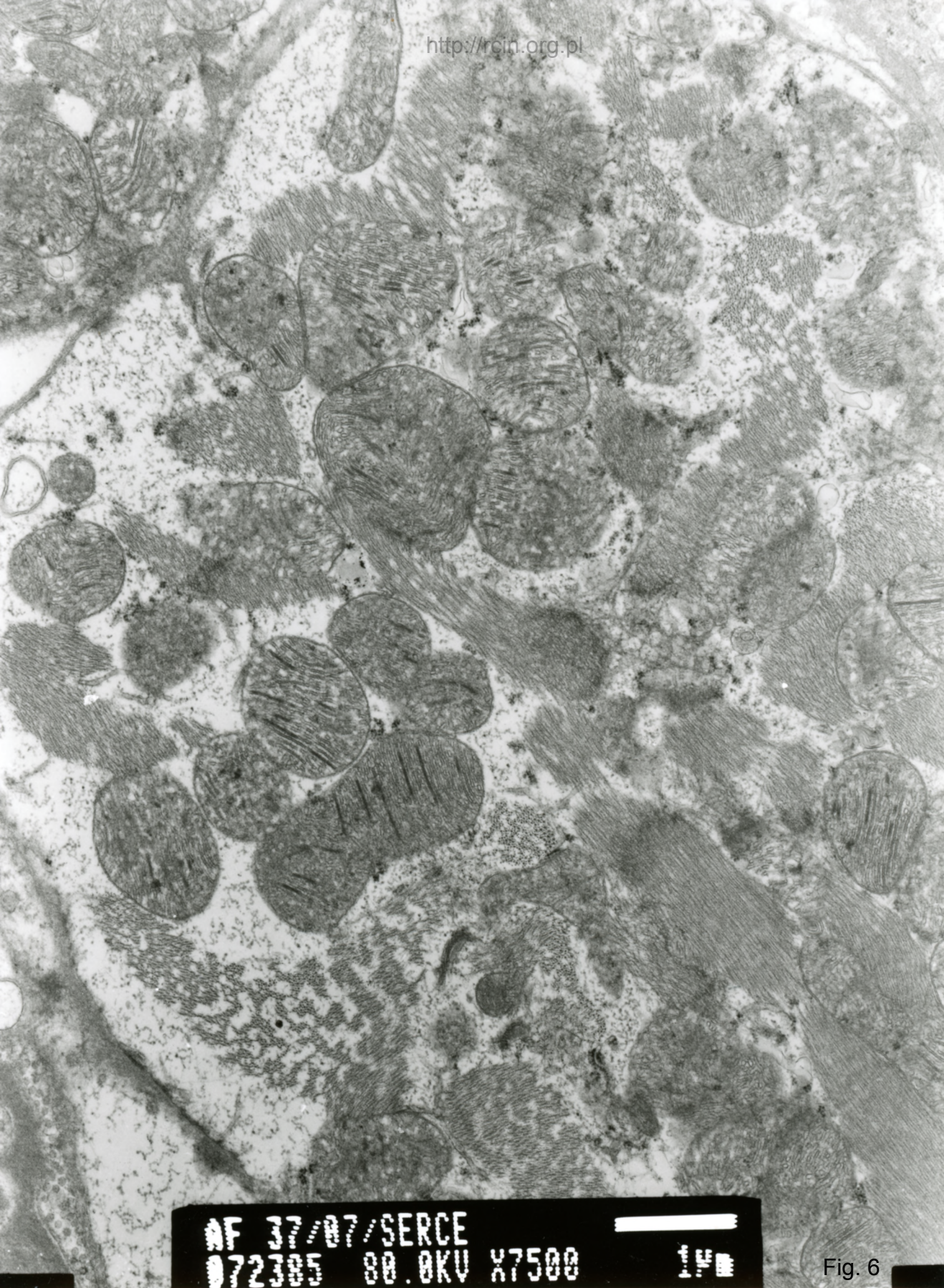
AF 37/07/SERCE
072379 80.0KV X10K 500nm

Fig. 4



AF 37/07/SERCE
083407 80.0KV X12K 500nm

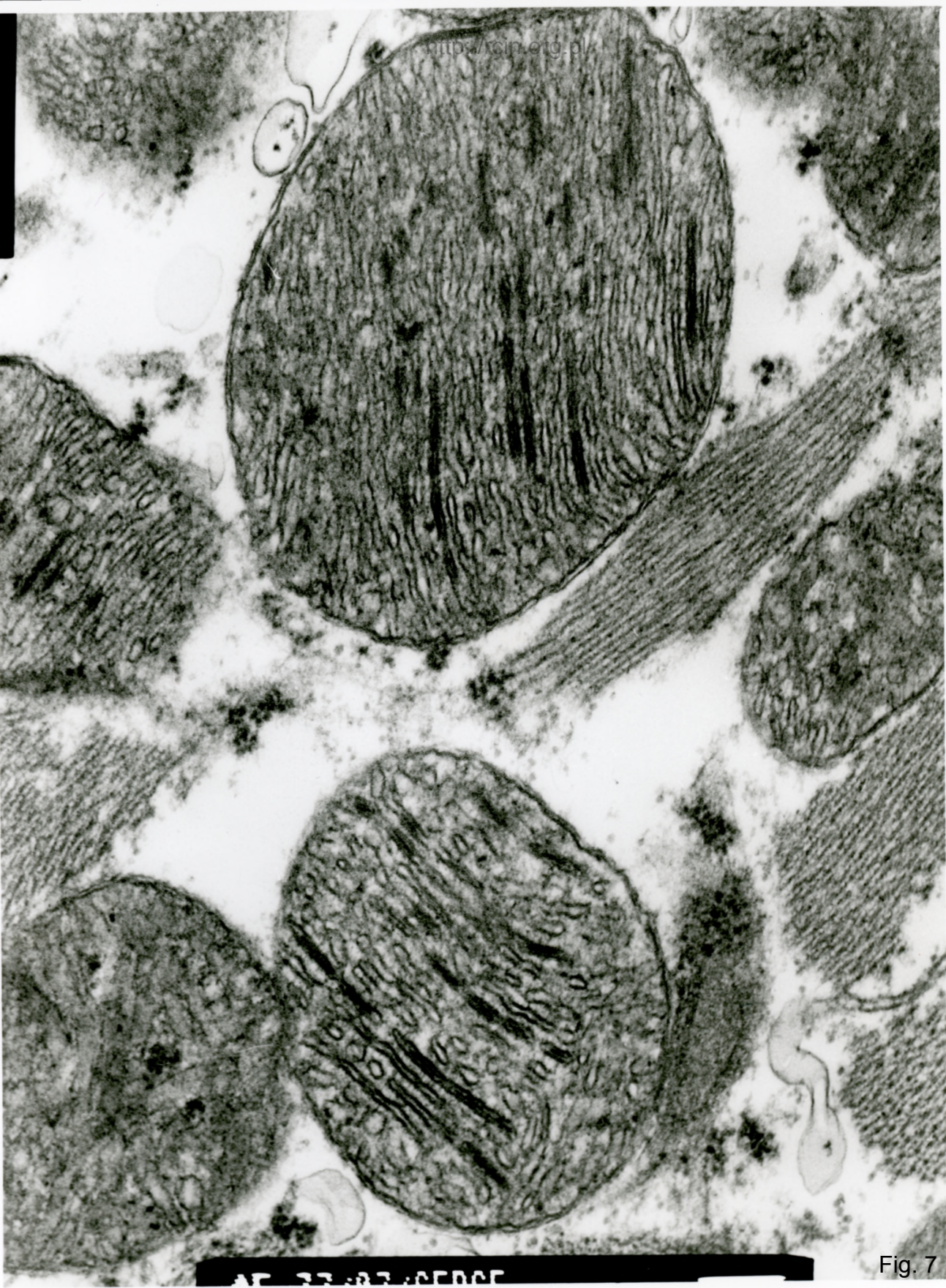Fig. 5



AF 37/07/SERCE
072385 80.0KV X7500




Fig. 6



AF 33 33 0000

Fig. 7

37/07

1. 43

Arytmogenna kardiomiopatia

W ocenie ultrastrukturalnej widoczne ogniskowo zaburzenia w przebiegu miofilamentów i ich dezorganizacja (Fig. 1,2,3). W kardiomiocytach widoczne są zmienione ultrastrukturalnie mitochondria (Fig. 4,5,6,7).

Arrhythmogenic cardiomyopathy

Electronmicroscopy evaluation revealed focal disruption and disorganization of myofilaments (Figs. 1,2,3). Ultrastructurally altered mitochondria were present in cardiomyocytes (Figs. 4,5,6,7).