

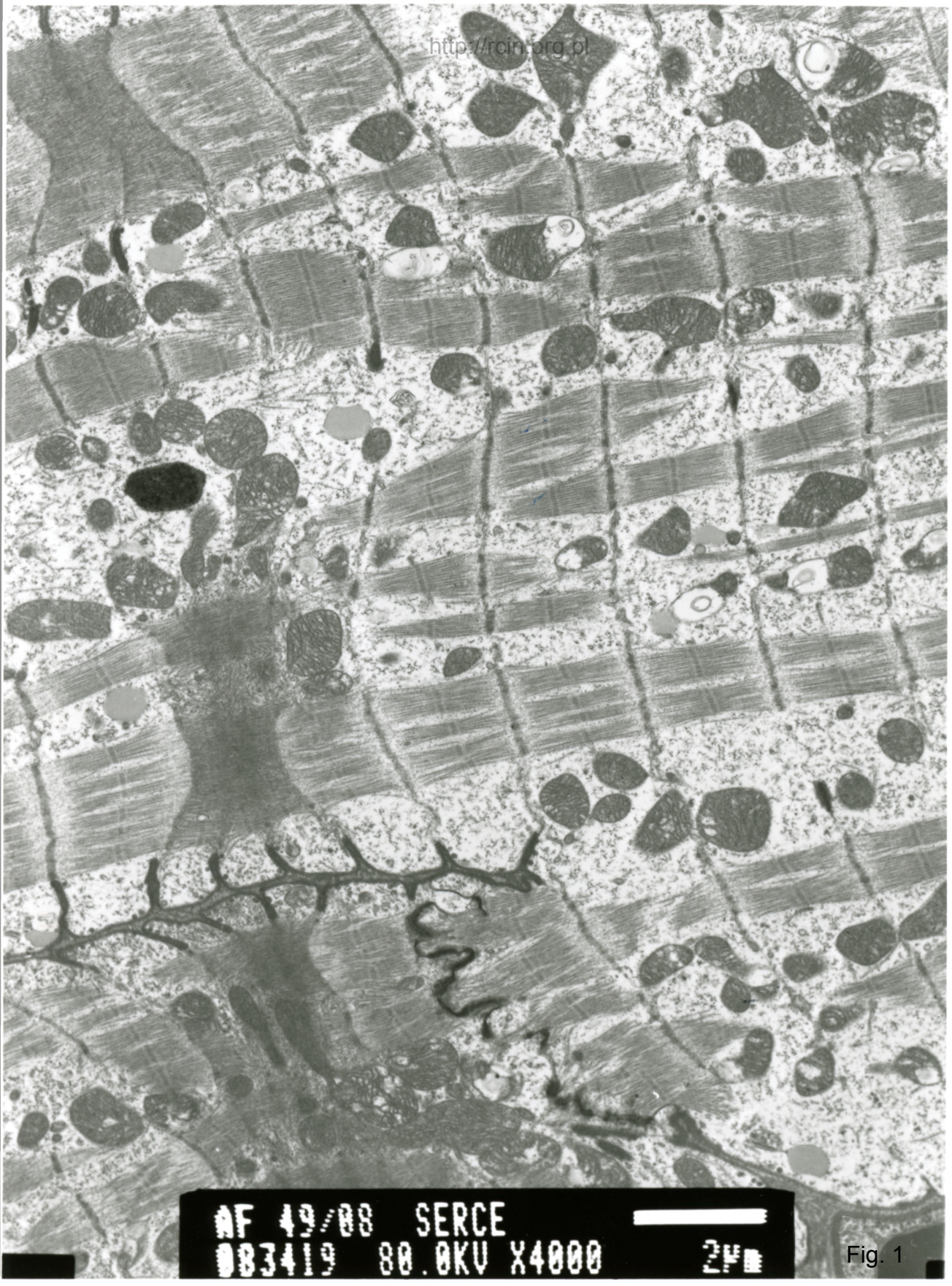
49/08

### Kardiomiopatia rozstrzeniowa

Analiza ultrastrukturalna ujawniła cechy cytolizy w wielu kardiomiocytach (Fig. 1,2,3). W cytoplazmie kardiomiocytów obecne były obrzękłe mitochondria, charakteryzujące się jasną macierzą i nieregularnym układem grzebieni (Fig. 4).

### Dilated cardiomyopathy

Ultrastructural analysis revealed features of cytolysis in many cardiomyocytes (Fig. 1,2,3). Swollen mitochondria, characterized by a light-electron matrix and an irregular arrangement of mitochondrial cristae were seen in the cytoplasm of cardiomyocytes (Fig. 4).



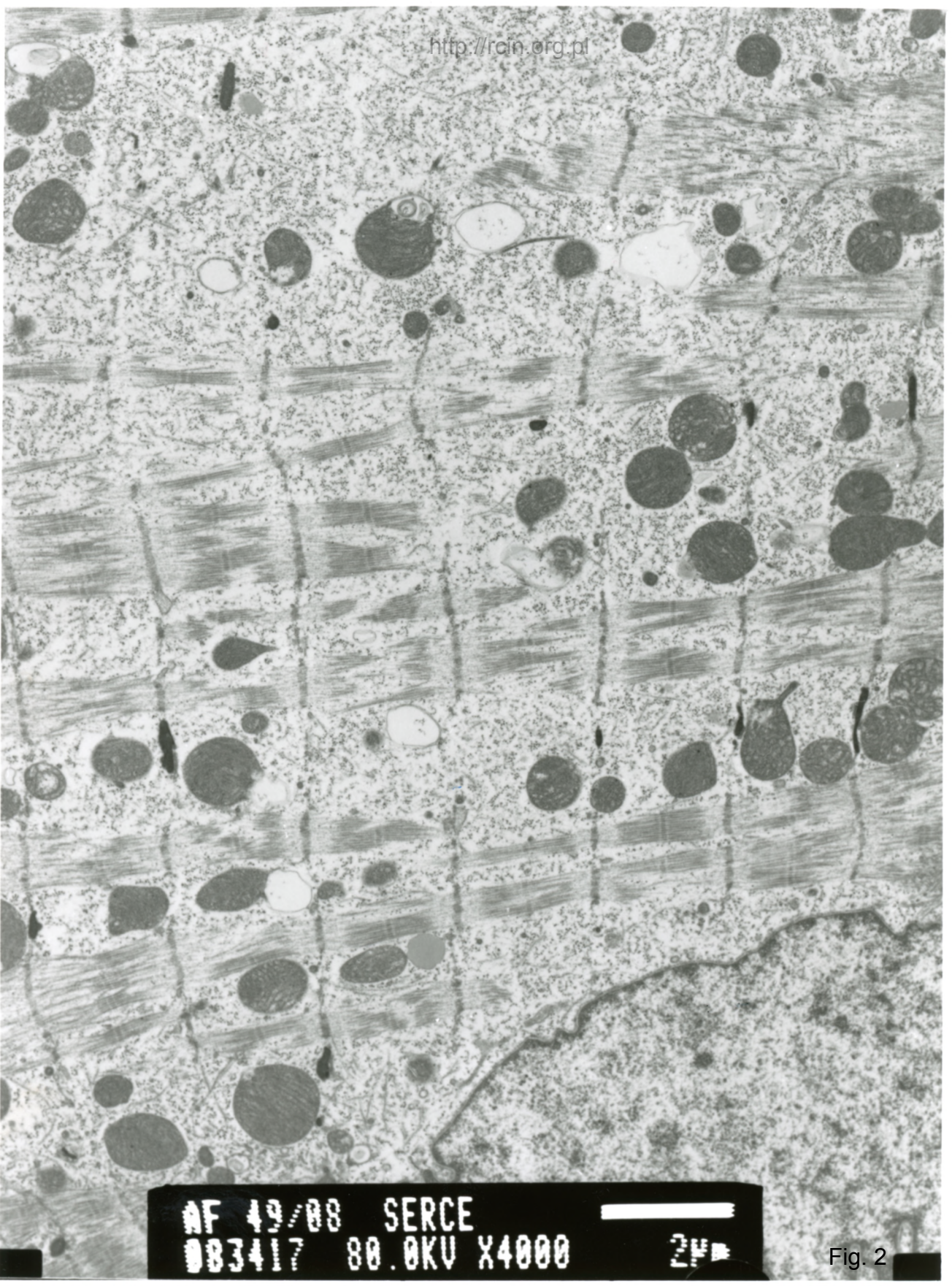
AF 49/08 SERCE  
083419 80.0KV X4000




2µm

Fig. 1





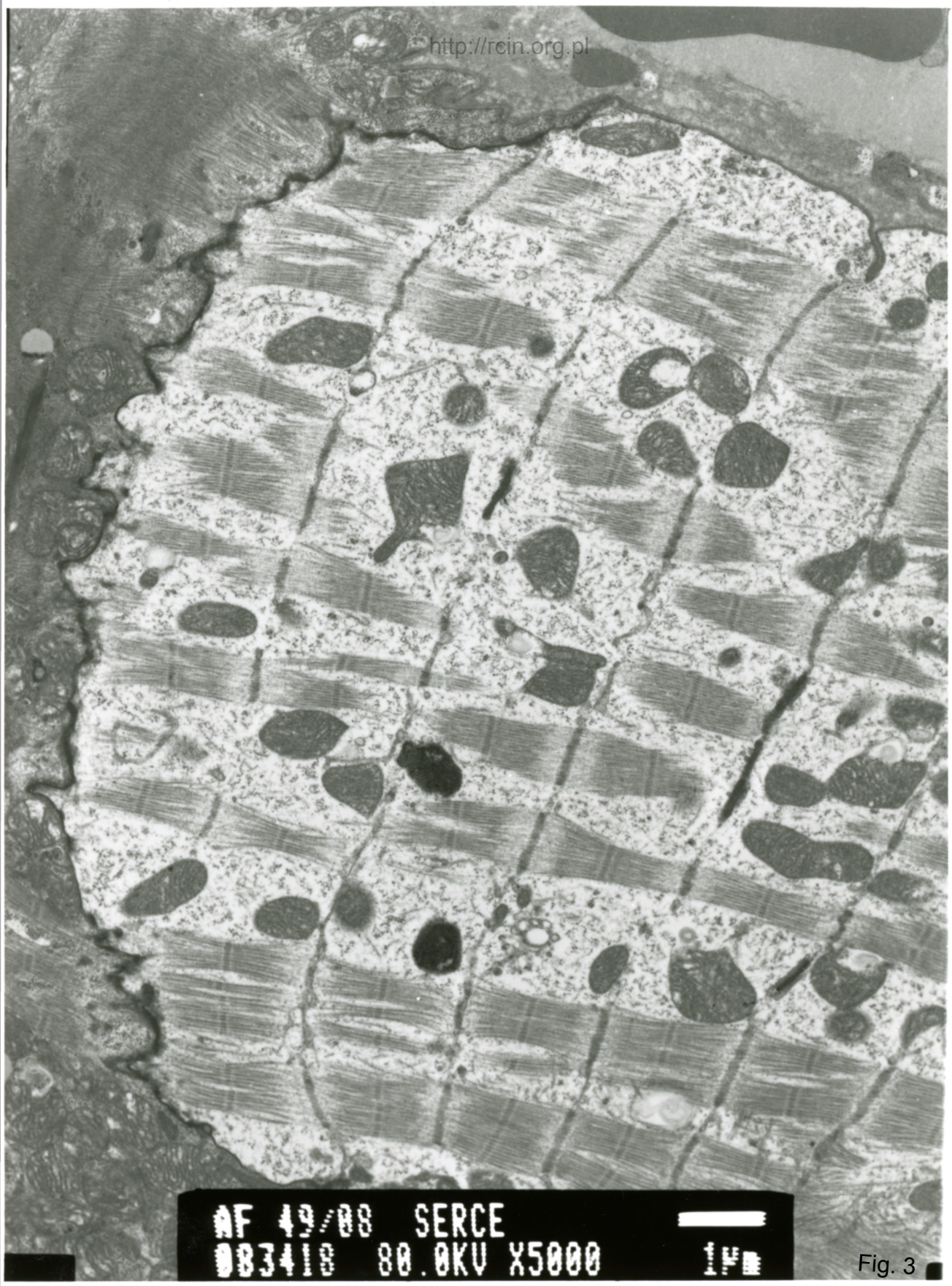
AF 49/88 SERCE  
083417 80.0KV X4000



2µm

Fig. 2





AF 49/08 SERCE  
083418 80.0KV X5000


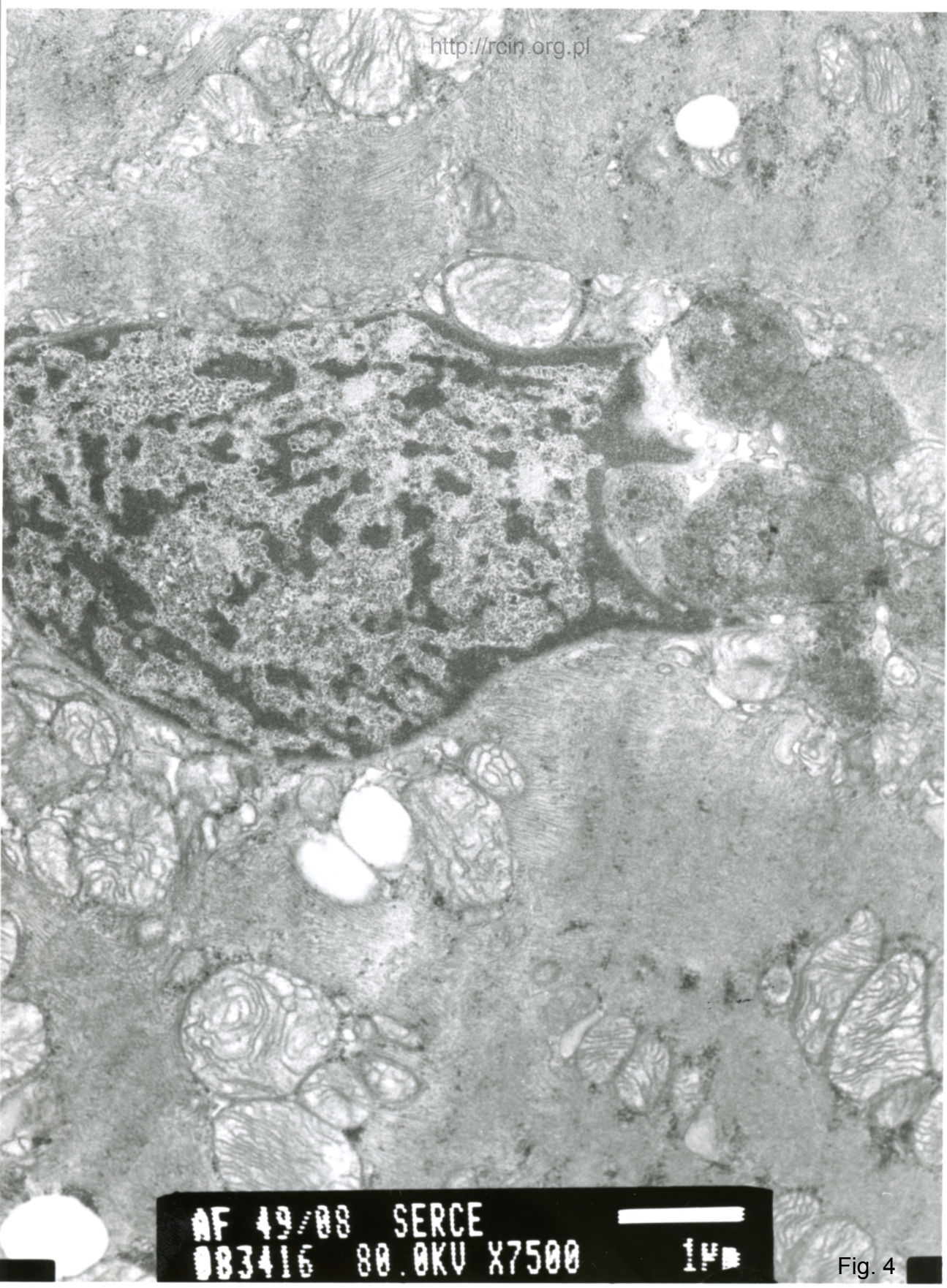


Fig. 3





AF 49/08 SERCE  
083416 80.0KV X7500

1 μm

Fig. 4