

ANDRZEJ PILARCZYK

**Zmiany hematologiczne i histologiczne przy martwiczym zapaleniu skrzelu karpia (branchionecrosis cyprinorum)**

**Haematological and histological changes in carp with necrotic gill disease (branchionecrosis cyprinorum)**

Wpłynęło 13 grudnia 1975 r.

**Abstract** — Haematological and histological investigations on carp from the Experimental Fish Culture Station at Golysz revealed a number of pathological changes accompanying necrotic gill disease in carp. On the basis of the obtained results it may be stated that this disease causes marked changes in the whole organism, these being manifested by a general anaemia which, in turn, leads to an increased regeneration of red blood cells. Large numbers of immature erythrocytes with signs of retrograde changes are found in the blood circulation. Changes in the kidney, liver, and pancreas are of necrotic character and their intensity depends on the degree of advancement of the disease.

Increasing losses in the carp stock caused by necrotic gill disease of unknown aetiology have led to more attention being paid to the problem. This paper presents the results of haematological and histological observations of diseased fish. The described changes and their course are strictly connected with the external symptoms of that disease. Publication of these observations should give some additional information and contribute to the explanation of the aetiology of this dangerous disease.

Necrotic changes in the gills, occurring in consequence of an unknown pathological factor, were already noted twenty years ago. According to Russian investigations (Apazidi 1961, Lopuchina 1968, 1969, Bauer, Musselius, Strelkov 1969, Ščerbina 1973), such changes occurred in the years 1955 and 1956 in the north-western republics of the USSR, to spread to further regions in subsequent years.

In other countries necrotic changes of this type were described later — Czechoslovakia (Tesarčík, Stos 1969), Bulgaria (Margaritov 1971), German Democratic Republic (Kulow 1973, Kulow, Musselius 1973, Matheis 1973). All the authors assume, however, that the disease began much earlier. In Poland Międzyński (1965) first drew attention to necrotic gill disease. He assumed that in this country the disease appeared about 1956.

During the last twenty years several publications have appeared aiming at explaining the aetiology of this disease and at elaborating proper preventive methods or therapy. Most research workers believe that there are many factors causing the disease (Kocyłowski 1972). These can be either parasites occurring in the gills or large variations of the pH or oxygen content in the water (Międzyński 1965, Bauer, Musselius, Strelkov 1969, Lopuchina 1969).

According to the recent investigations it would appear that parasitic algae, fungi, and sporozoa have no aetiological significance. Hitherto, leucocytes, whose numbers increased greatly on the gill surface of diseased fish, were interpreted as vegetative stages of parasites (Kulow, Musselius 1973). Deterioration of the environmental conditions (Kocyłowski 1972) in consequence of pond fertilization, the densification of fish stock, and feeding, play an undoubted role in the development of this disease. On the basis of bacteriological investigations, Linnik, Mamyš, and Lagovskaja (1972) excluded bacteria as a direct cause of necrosis. On the other hand, another group of research workers have found *Myxobacteria* present in this gill disease (Bootsma 1974, Spangenberg 1975). However, the results of investigations so far carried out do not permit the unequivocal determination of the causes which, in turn, would allow an elaboration of appropriate prophylaxis and therapy.

### **Material and method**

The analysed results are those coming from systematic investigations on carp in experimental and productive ponds of the Experimental Fish Culture Station of the Polish Academy of Sciences at Golysz. The main aim of the investigations was to observe the influence on the fish organism of such factors associated with the intensification of production as: densification of stock, water pollution, feeding on artificial fodder. The study concerned the presence of external and internal parasites and analysis of anatomo-pathological changes and haematological indices, including determination of the haemoglobin content by means of the cyanhaemoglobin method, haematocrit values, and smears. Blood for investigation was taken from the coccygeal artery. Blood smears were

stained by means of the Pappenheim method. For histological slides sections were taken from 66 carp specimens. They were fixed in Bouin-Holland's solution and subsequently prepared according to the generally applied histological methods and stained in hematoxylin and eosin.

Altogether the following were investigated: 35 specimens of  $K_3$  and 15 specimens of  $K_2$  from catches made in the experimental ponds in autumn 1972, 340 specimens of  $K_{2-3}$  in monthly investigations throughout the 1973 fish culture season, and 160 specimens of  $K_{2-3}$  and 30  $K_{1-2}$  in the 1974 season. Also part of the material collected in 1975 was used.

For a clearer presentation of the changes which occurred in most of the fish stock the results are shown in the form of diagrams. These also give the results of investigations of fish from the productive pond Wyszni III with a stock of 1200 specimens of  $K_{2-3}$ /ha where deaths occurred among fish at the beginning of June 1973 and among yearlings from the pond Byczek where the fish died with symptoms of advanced necrotic gill disease during the whole of July 1974. These data permitted, in the two cases, a comparison to be made between changes of haematological indices in cases of far advanced disease and those observed in the majority of carp.

On the basis of parasitological investigations carried out parallelly it can be stated that no parasite invasions which could have significantly influenced the presented results took place at that time; nor were clinical symptoms characteristic of other carp diseases observed during this period.

## Results

### External symptoms

Clinical symptoms of necrotic gill disease had been observed for some years in carp reared at Gołysz. However, owing to the fact that the disease did not cause any serious losses, they were usually neglected. In 1973 the necrotic gill disease became an acute form causing deaths at the end of May and beginning of June. A year later, the symptoms of this disease appeared in a large part of the stock, affecting carp of all age groups. In the three-year carp the disease did not cause any serious losses. Nevertheless, the fish were weak, reacted more intensively to oxygen variations in the water, demonstrating a characteristic behaviour for suffocation and deaths were already noted at a decrease of oxygen content to about 3 mg/l. The disease affected more intensively the two-yearling  $K_{1-2}$  and the fry, in which it turned into an acute form in a few ponds, causing considerable losses.



One of the first symptoms of the gill disease is a hypersecretion of mucus which, in the form of a white film, covers initially the ends of gill lamellae and subsequently their whole surface. Small hyperaemiae can be seen macroscopically on the lamellae and the gills are pale with an irregular blood supply. A further stage is oedema of the whole respiratory apparatus. On squashed gill preparations a marked increase in characteristic cell infiltration is observed simultaneously. With a strong infiltration the gills show a grey colour under the microscope. The size of the cells of infiltrations is usually 8 to 15  $\mu\text{m}$  and they are capable of amoeboid motility and diapedesis.

According to the recent data (Kulow, Musselius 1973) and to the author's own observations one can assume that these are leucocytes. In the microscopic picture, apart from the strong cell infiltration, haemangiectasis is observed; in the lumina of the blood vessels stases and coagula are formed. The epithelium becomes necrotic, starting from the ends of the gill lamellae of the first branchial arch, and crumbles, disclosing the blood vessels. The final stage of the acute form of necrotic gill disease are widespread necrotic changes on all branchial arches, causing large gill tissue defects and leading very often to the death of the fish in consequence of physiological disturbance or because of an infection of the whole organism.

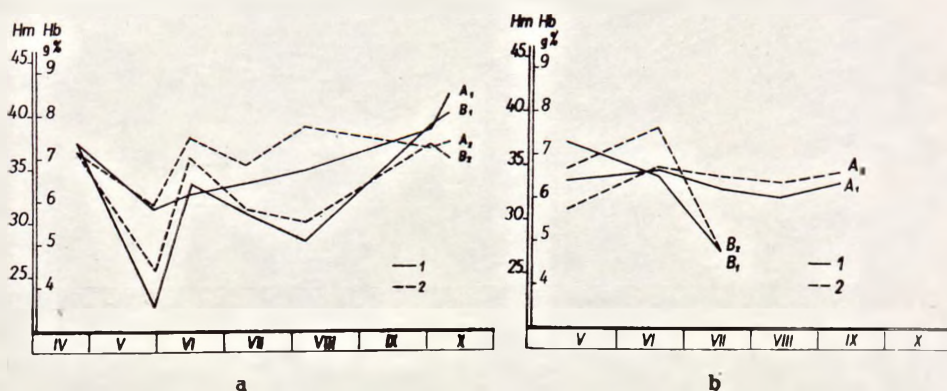
The acute form of necrotic gill disease occurs only in some ponds, mainly among fry and two-yearlings. Its occurrence is conditioned by some predisposing factors such as: deterioration of the environmental conditions, too high density of fish, or a deficiency of nutrients. In most cases, however, the disease assumes a chronic form. Pathological changes on the gills are then limited to cell infiltrations, hypersecretion of mucus, oedema, the occurrence of small ecchymoses, and sometimes small tissue defects. The diseased fish feed normally, keeping in general in good condition. Small injuries to the gills often undergo pleriosis.

In necrotic gill disease changes also occur in the internal organs. Depending on the degree of advancement of the disease, the liver becomes more or less pale. Kidney oedema is also characteristic.

#### Haematological changes

The haematocrit values for the investigated fish, without any symptoms of an acute form of the disease, are given in the graph (fig. 1). Throughout the 1973 season the haematocrit was maintained on the level 35.3 to 38.9 showing a decrease to 31.6 at the end of May. In the following year it was slightly lower — 30.9 to 34.5. The graphs show the results of investigations of fish from the ponds where an acute form of necrotic gill disease appeared which caused a decrease in the mean

haematocrit values to 25.6 and 27.2 (fig. 1), the lowest values found in fish with far advanced necrotic changes being 10.0 to 18.0. Comparing the above results with those from literature (Houston, De Wilde 1972, Svobodová 1973), it is seen that the mean haematocrit values for the investigated fish are within the norm or slightly lower (1974). A decrease in the haematocrit values occurs in fish with an acute form of necrosis.



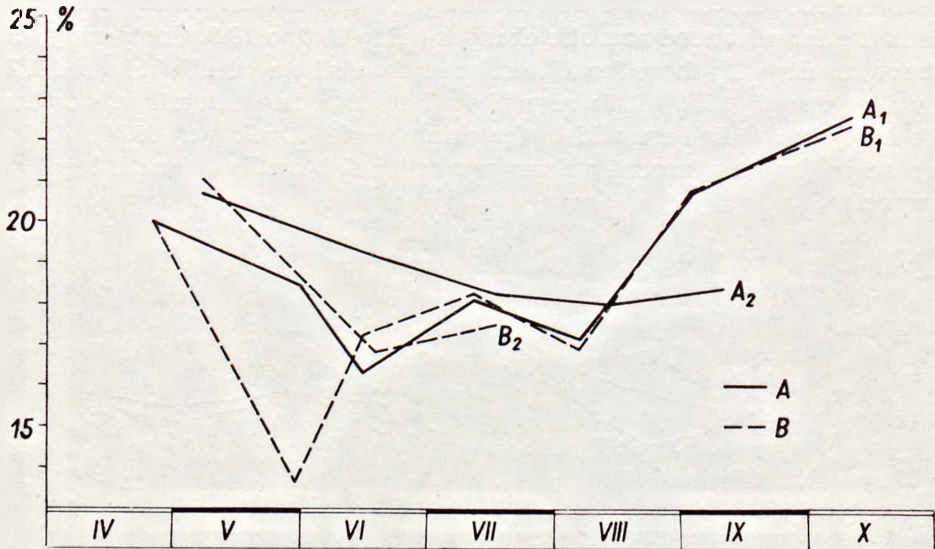
Ryc. 1. Graficzne przedstawienie zmian wskaźników zawartości hemoglobiny (1) i hematokrytu (2) w sezonach hodowlanych 1973 (a) i 1974 (b).  $A_1, A_2$  — dla większości karpki w sezonie;  $B_1, B_2$  — przebieg zmian w stawach Wyszni III (ryc. 1a) i Byczek (ryc. 1b), gdzie wystąpiła ostra forma martwicy skrzel

Fig. 1. Graphic presentation of changes of haematological indices (1) and haematocrit (2) in fish culture seasons 1973 (a) and 1974 (b).  $A_1, A_2$  — for the majority of carp in the season;  $B_1, B_2$  — the course of changes in the ponds Wyszni III (fig. 1a) and Byczek (fig. 1b), where the acute form of gill necrosis occurred

A distinct fall, however, not correlated with the haematocrit values, is observed in haemoglobin content (fig. 1). This fall is very marked in the case of an acute form of necrotic gill disease (the ponds Wyszni III and Byczek).

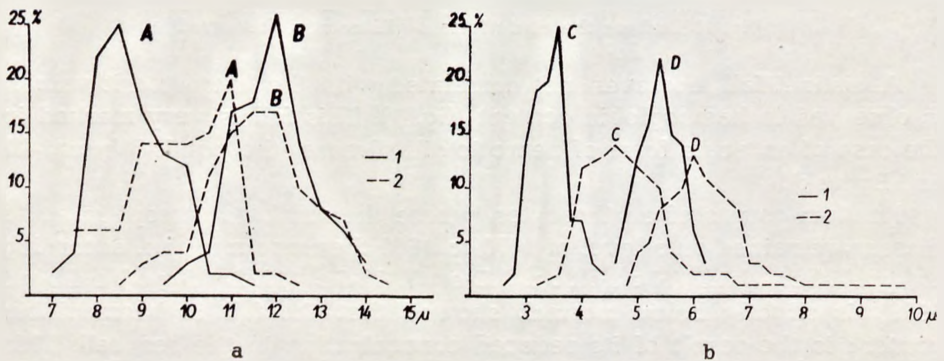
Random counts of erythrocytes, whose the numbers, except in acute disease, remained on a level of 1470 to 1800 thousand/mm<sup>3</sup>, i.e. according to publisher data (Houston, De Wilde 1972, Svobodová 1973), is slightly below normal, showed that the fall in haemoglobin content is the result of its reduced concentration in the red cell. This is also confirmed by a comparison of the mean corpuscular haemoglobin concentration (MCHC) from the author's own investigations (fig. 2) with the data from publications (Svobodová 1973, Svobodová, Smíšek 1974) where the value 20 to 26 is taken as the MCHC norm for healthy fish.

The above-mentioned changes were accompanied by qualitative ones in the red blood cells in 30 to 40 per cent of fish in 1973 and in the majority of the investigated carp in 1974. The intensity of changes in



Ryc. 2. Średnie stężenie hemoglobiny w krwince czerwonej (MCHC) w sezonie 1973 (1) i 1974 (2). A — u większości karpia w sezonie; B — u karpia z ostrą formą martwicy. B<sub>1</sub> — w stawie Wyszni III; B<sub>2</sub> — w stawie Byczek

Fig. 2. Mean corpuscular haemoglobin concentration in erythrocytes in the 1973 (1) and 1974 (2) seasons. A — in the majority of carp in the season; B — in carp with an acute form of necrosis. B<sub>1</sub> — in the pond Wyszni III; B<sub>2</sub> — in the pond Byczek



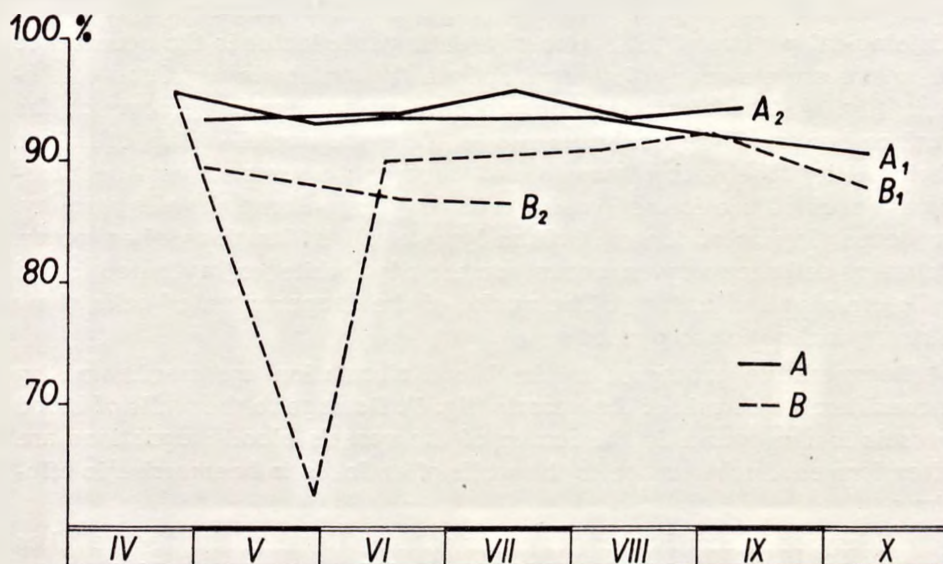
Ryc. 3. Wyniki pomiarów erytrometrycznych (a) i kariometrycznych erytrocytów (b) przedstawione w postaci krzywych Price-Jones'a. A — szerokość krwinek; B — długość krwinek; C — szerokość jąder erytrocytów; D — długość jąder erytrocytów. 1 — parametry dla ryb bez objawów choroby; 2 — parametry dla ryb z objawami choroby

Fig. 3. Results of erythrometric (a) and kariometric (b) measurements of erythrocytes presented by means of Price-Jones's curves. A — blood cell width; B — cell length; C — width of the erythrocyte nuclei; D — length of the erythrocyte nuclei. 1 — parameters for fish free from disease symptoms; 2 — parameters for fish with symptoms of the disease



particular individuals was closely related with the general state of health of the fish, reaching in extreme cases up to 90 per cent of changed erythrocytes. It should be noted that apart from the two mentioned ponds (Wyszni III and Byczek) where in single specimens occurred 80—90% of changed erythrocytes, the necrotic gill disease did not occur in an acute form.

The basic difference in the erythrocyte picture between healthy fish and fish with symptoms of necrotic gill disease consists in a much larger number of immature erythrocytes in the peripheral blood. The observed changes mainly consist in the changed shape and size of cells (fig. 3) and enlargement and change of nuclear structure (figs 3, 5). In the microscopic picture spherocytes dominate, often taking on a distinctly spherical shape (fig. 5). The volumetric relation of the cytoplasm to the nucleus changes in favour of the nucleus. The increased nucleus is of very compact structure (fig. 5) far from normal, a somewhat pycnotic form. The chromatin becomes nodular, showing hyperchromia. In some red cells a partial lysis of the nuclear chromatin is observed. A tendency for degenerative changes is also observed in whole cells. The colour of the erythrocyte cytoplasm changes from yellowish-pink to grey-blue. There are large fragments in it showing distinct hypochromatism. Most



Ryc. 4. Zmiany względnej procentowej zawartości limfocytów w badanej krwi w latach 1973 (1) i 1974 (2). A — u większości ryb; B — u karpia z ostrą formą martwicy. B<sub>1</sub> — w stawie Wyszni III; B<sub>2</sub> — w stawie Byczek

Fig. 4. Changes in the relative percentage content of lymphocytes in the investigated blood in 1973 (1) and 1974 (2). A — in the majority of fish; B — in carp with an acute form of necrosis. B<sub>1</sub> — in the pond Wyszni III; B<sub>2</sub> — in the pond Byczek

fish have an increased number of primitive erythrocytes in their peripheral blood.

In chronic necrotic gill disease the leucocyte picture does not depart from the norm. However, distinct changes occur in the leucocyte picture as soon as the gill necrosis takes on an acute form. The percentage of lymphocytes decreases then to 40 to 50 per cent. For simplicity, changes in the leucocyte picture in the investigated fish are presented in the form of relative percentage values of lymphocytes (fig. 4).

Among the leucocytes atypical degenerated forms occur. Segmentation of the heterophylic granulocyte nucleus increases. Within all white blood cells degenerative changes occur in the form of vacuolization of the cytoplasm and nucleus. The changed cytoplasm loses its normal ability to absorb pigments and usually assumes a pale blue colour. Degenerative forms occur in both the chronic and acute forms of necrotic gill disease, the changes being much more pronounced in the latter.

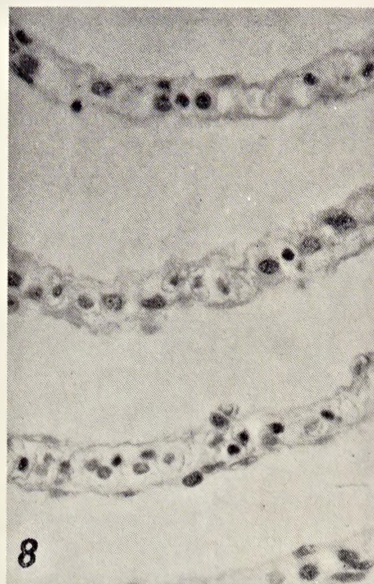
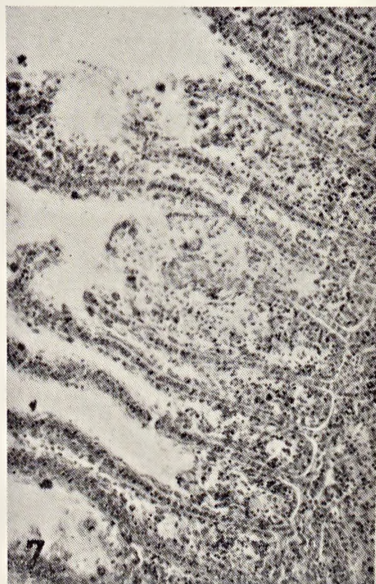
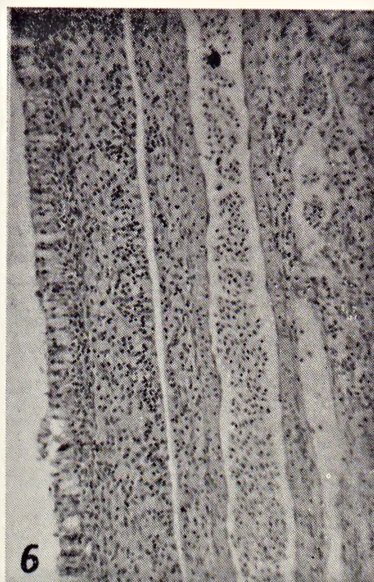
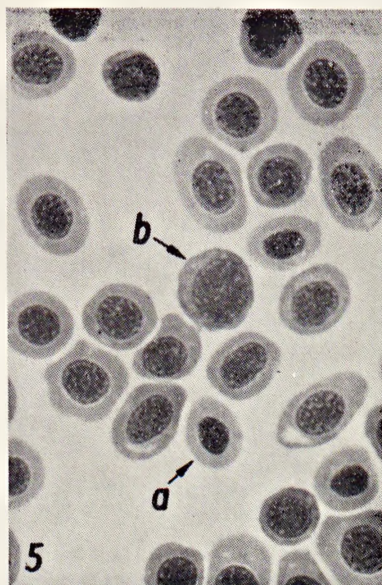#### **Histological changes**

**Gills.** In all preparations from the diseased fish more or less intensive degenerative changes are observed. These concern both the respiratory epithelium of the gills and their whole circulation. The first sign in the histological picture of the action of a pathogenic factor is the occurrence of an excessive amount of mucous cells in the surface layer of the epithelium (fig. 6). The most commonly occurring process is necrosis of the surface layers of the epithelial tissue. Here the nuclei of the cells lose their ability to absorb pigments and undergo turgescence and degradation. Vacuolae are formed in the cells and the cell membranes atrophy. In deeper layers of the epithelium lymph cell infiltrations often occur. Between cells leucocytes occur numerously, while extravasated blood cells are also encountered. The nuclei of the deeper situated cells show a strong inclination to pycnosis.

Degenerative processes in the blood circulation are manifested by a considerable ectasia of the vessels (fig. 6). Damage to the walls of blood vessels is also found. In the lumen of the vessels blood stagnations are often formed. Such damage to the walls often leads to haemorrhagic effusions.

Widespread necrotic changes occur on the gills when the disease takes an acute form. Karyolysis, vacuolization of the cytoplasm and degradation of cells is then noted in the whole epithelial tissue (fig. 7). Deep tissue necroses occur. The respiratory epithelium of the gill lamellae also becomes damaged and disintegrate (fig. 8). Blood coagula are formed in the blood vessels situated in the vicinity of necrotic foci. Haemorrhagic effusions take place from the exposed blood vessels (fig. 9). At this stage

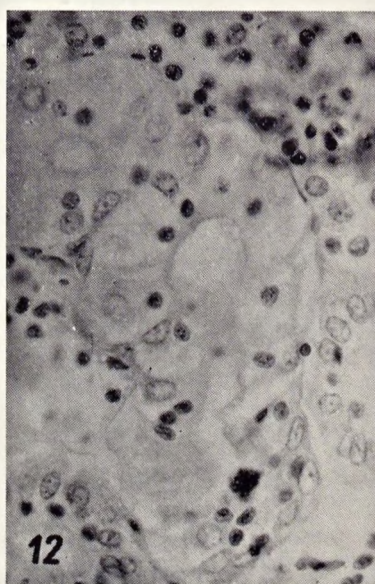
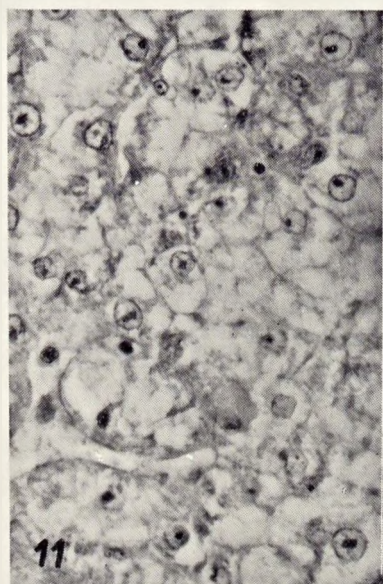
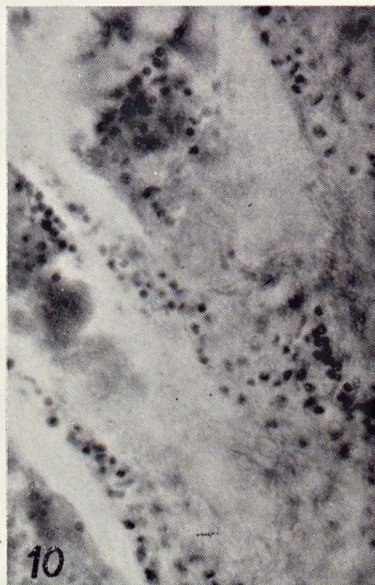
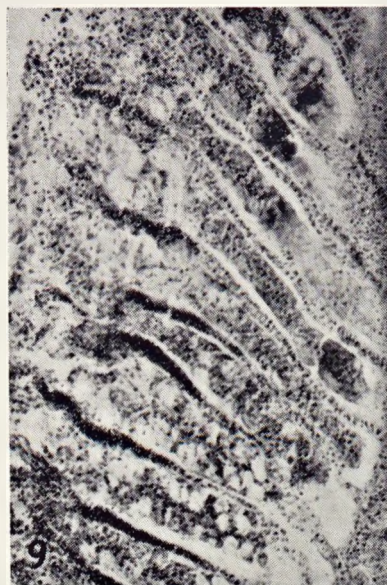



Ryc. 5—8. 5 — Obraz czerwonych krwinek u karpia z wyraźnymi objawami martwiczego zapalenia skrzelii. a — krwinki dojrzałe o wyglądzie zbliżonym do normy; b — erythroblast zasadochłonny. 6 — Przekrój przez nabłonek płata skrzelowego, na którym widoczne jest rozszerzenie głównych naczyń krwionośnych, uszkodzenie zewnętrznie położonych komórek nabłonka oraz nacieki leukocytarne w tkance nabłonkowej. 7 — Uszkodzenie pojedynczych blaszek skrzelowych polegające na rozpadzie skrajnych partii blaszki oraz przerostach nabłonka oddechowego. 8 — Przekrój przez blaszki skrzelowe, uszkodzenie i rozpad nabłonka płaskiego

Fig. 5—8. 5 — Erythrocyte picture in carp with marked symptoms of necrotic gill disease. a — mature erythrocytes appearing almost normal; b — basophilic erythroblast. 6 — Section across the epithelium of the gill lamella on which ectasia of the main blood vessels is visible, damage to the external epithelial cells and leucocytic infusions in the epithelium tissue. 7 — Disintegration of particular gill lamellae consisting in decomposition of external parts of the lamella and hypertrophy of the respiratory epithelium. 8 — Cross-section of the gill lamella, damage and disintegration of the pavement epithelium





Ryc. 9—12. 9 — Przekrój płata skrzelowego z widocznymi silnymi zmianami nekrotycznymi. 10 — Fragment uszkodzonego płata skrzelowego, zanik struktury tkanki nabłonkowej, rozpad większości komórek. W tkance widoczne liczne laseczkowate bakterie. 11 — Przekrój przez wątrobę. Widoczne uszkodzenia miąższu polegające na rozpadzie komórek wątrobowych, uszkodzeniu błon komórkowych oraz niedobarwliwości i wakuolizacji cytoplazmy. 12 — Przekrój przez kanaliki nerkowe. Widoczny rozpad pojedynczych jąder komórkowych oraz zanik błon komórkowych

Fig. 9—12. 9 — Cross-section of the gill lamella with visible serious necrotic changes. 10 — Fragment of a damaged gill lamella, atrophy of the epithelial tissue structure, disintegration of the majority of cells. In the epithelium numerous rod-shaped bacteria visible. 11 — Cross-section of the liver. Visible destroyed cellular structure of the liver consisting in karyorrhexis of the liver cell, cell membrane disintegration, and hypochromia and vacuolization of cytoplasm. 12 — Cross-section of the renal tubules. Visible karyorrhexis of particular cell nuclei and atrophy of cell membranes

of gill injury, both in the tissue itself and on its surface, rod-shaped bacteria are found to occur in masses (fig. 10).

**Liver.** The intensity of changes in particular individuals varies. Marked changes, however, are found in all investigated livers. They occur, above all, in the cells of the parenchyma (fig. 11) and, in a much smaller degree, in the blood vessels and interstitial tissue. The most frequently encountered phenomena are: hypochromatism and vacuolization of the cytoplasm (fig. 11). Large amounts of amorphous haematoxylin stained substance collect in the cytoplasm, fragments of it accumulating near the cell membranes. Turgescence and a subsequent karyorrhexis takes place. Less frequently karyorrhexis occurs by pycnosis. In places cell membranes atrophy. Damaged cells are usually uniformly distributed in the whole parenchyma of the liver. Large fragments of tissue, losing their normal structure, are also found. Necrotic foci are formed.

**Kidney.** The smallest changes are observed in this organ. In most of the analysed specimens numerous extravasated blood cells are found in the lymphoid tissue. Erythrocyte agglomerations are formed near the renal tubules. Necrosis affects only individual cells of these tubules, such changes being more intense in the acute form of the disease. They lead to disintegration of the renal tubules (fig. 12). Changes in cell nuclei of the lymphoid tissue occur. The kidneys lose their compactness, their structure becoming blurred.

### Discussion

The threat to fishery arising from necrotic gill disease was a factor stimulating investigations on this complaint. Publications appeared on the haematological indices in necrotic gill disease (Margaritov 1973, Svobodová, Tesarčík 1974), and in many papers detailed description of the symptoms were given. Histological changes were less frequently analysed and their descriptions were less detailed.

Most of the author's own observations are in agreement with the published data. This concerns both the symptoms of the disease and the great majority of haematological indices. Opinions agree as to the fact that the disease causes a decrease in the quantity of haemoglobin and erythrocytes in the blood (Margaritov 1973, Svobodová, Tesarčík 1974).

The author's observations on the changes in the erythrocyte picture, however, are somewhat different. They showed an increased participation in the peripheral blood of immature erythrocytes showing a marked inclination to degeneration. These erythrocytes are of another shape and size (fig. 3). The total volume of the blood cell increases; the nucleus increases and its structure becomes looser. The cells show hyperchromia.



The mean corpuscular haemoglobin concentration decreases and, in consequence, also the total content of haemoglobin in the blood. Changes observed in the erythrocyte picture indicate a rapid destruction of red blood cells in the blood circulation leading to intensive regeneration of the blood with simultaneous disturbances in the process of erythropoiesis. Such a type of anaemia is not encountered either in infectious or parasitic diseases. There is, on the other hand, a certain similarity with the changes observed in fish intoxication with some chemical compounds (Waluga, Flis 1971). Disturbances in erythropoiesis may also be caused by the metabolic processes of some algae and by the products of their decomposition (Lukjanenko 1967).

On the basis of the above observations it is difficult to state unequivocally the cause of erythrocyte damage in the course of necrotic gill disease. The author is inclined to think that this is the result of a long lasting intoxication of the organism with substances produced in the aquatic environment in consequence of complex biochemical processes. This would corroborate the results of a number of publications in which attention was drawn to the possibility of a toxic affect of some compounds occurring in the pond (Kocyłowski 1972, Spangenberg, Schreckenbach, Krug 1975).

In none of the hitherto published papers have the histological changes in necrotic gill disease been analysed in detail. It is therefore only possible to compare the author's own observations with the results of investigations on a similar subject.

On the basis of histological examination of the gills, two stages of the disease can be distinguished. In the first the pathological factor acting as an irritant on the gill surface causes a defensive reaction in the form of an increased quantity of mucous cells. Subsequently the surface layers of the cells of the respiratory epithelium become affected (figs 6, 8). Changes in deeper layers of the tissue consisting in an increased number of leucocytes in the tissue and ectasia and damage to the blood vessel walls are also observed. In the second stage necrosis affects the whole respiratory epithelium. The character of the changes is different; the blood vessels are seriously damaged, blood coagula formed in them leading to an insufficient blood supply to large parts of the tissue.

Widespread necrosis of the gill epithelium takes place. In the stage of intense necrotic changes large numbers of rod-shaped bacteria (fig. 10) occur both in the tissue and on its surface. It should be noted that in the initial stage of the disease these bacteria were not found.

On the basis of a comparison of the author's own results with those of Wood, Yasutake (1957), Machado-Cruz (1962), and Amlacher (1972) it is found that the changes observed in carp gills and the course of this process differ from those occurring in myxobacteriosis in salmonids. The reaction and the character of gill damage in the

initial stage of the disease are somewhat similar to the changes which are caused in the gills by toxic compounds (Flis 1968 a, b, Schweiger 1957, Waluga 1971).

To sum up, it may be assumed that in the first stage of the disease damage to the gills occurs in consequence of the long lasting effect of noxious environmental factors. The influence of bacterial gill infection is only a secondary phenomenon. Transition from the first stage, a chronic form of the disease, to the second one, an acute form with participation of bacteria, is reflected in the whole organism in the form of a marked decrease of all haematological indices (figs 1, 2), a much higher percentage of participation of granulocytes and monocytes (fig. 4), and serious necrotic changes in the internal organs.

A comparison of the result of histological examination with the descriptions of other authors does not give any decisive answer to the question whether the changes occurring in internal organs are caused by chemical factors or are the effect of an infection of the organism caused by microorganisms. It is unquestionable, however, that the changes in all the fish material are intense and indicate a toxic influence of the pathogenic factor and that their intensity is in correlation with the intensity of the external symptoms of necrotic gill disease.

### Conclusions

1. Necrotic gill disease causes in carp marked changes in the whole organism, manifested, among other symptoms, in anaemia and intensive red blood cell regeneration showing features of pathological regeneration.

2. There are marked haematological changes in the chronic form of this disease, but these concern only the erythrocyte system. No changes in the percentage composition of leucocytes were observed. In an acute form, changes concerning erythrocytes become more pronounced (a marked decrease of all indices). Concomitantly a reaction of leucocytes takes place in the form of changes in percentage composition. The number of granulocytes and monocytes increases at the expense of lymphocytes. The course of Arneth's curve suggests a bacterial infection.

3. In histological preparations of gills damage to the surface layers of the respiratory epithelium and slight damage to the blood vessels are observed. As soon as the disease becomes acute, necrotic changes affect large parts of the gill tissue. Necrosis and decay of the gill lamellae follow. On the surface and in the tissue there is a mass occurrence of rod-shaped bacteria.

4. Changes in the kidney, liver, and pancreas are of necrotic character. Their intensity depending on that of the disease. In extreme cases

these changes result in diffused necrosis of these organs. The character of the above-described changes suggests that the investigated fishes had been under the influence of a toxic factor for a fairly long time.

5. Haematological and histological changes proceed in two distinct stages. On the basis of this observation two stages can be distinguished in the development of the disease. The first one, a chronic necrotic form, is most probably the effect of a long lasting action of noxious environmental factors on the organism, while the second is an acute form of necrosis developed from an additional bacterial infection through the partly damaged gills.

#### STRESZCZENIE

W pracy przedstawione zostały wyniki badań karpi z objawami martwiczego zapalenia skrzelii, pochodzących ze stawów Zakładu Doświadczalnego PAN Gołysz.

Ogółem przebadano 580 szt. karpi w sezonach produkcyjnych 1973 i 1974. Wykorzystano również część materiałów zebranych w roku 1975. Przeprowadzone badania obejmowały badania na obecność pasożytów, analizę zmian anatomopatologicznych oraz wskaźniki hematologiczne. Wykonano również preparaty histologiczne skrzelii, wątrobo-trzustki i nerek.

Uzyskane wyniki upowazniają do stwierdzenia, że przy martwiczym zapaleniu skrzelii obserwuje się wyraźne zmiany w całym organizmie. Objawiają się one w postaci niedokrwiłości, która, z kolei, prowadzi do silnej regeneracji krwinek. W obrazie czerwono-krwinkowym zwiększa się ilość niedojrzałych erytrocytów wykazujących dużą skłonność do zmian wstecznych. Znacznie niższe średnie stężenie hemoglobiny w niedojrzałej i uszkodzonej krwince czerwonej prowadzi do wyraźnego spadku ogólnej zawartości hemoglobiny we krwi. Nieco poniżej normy kształtuje się wartość hematokrytu.

Zmiany na etapie przewlekłej postaci choroby dotyczą układu czerwono-krwinkowego. Z chwilą przejścia schorzenia w formę ostrą pojawia się obronna reakcja organizmu przy udziale białych ciałek krwi. Kosztem limfocytów zwiększa się ilość granulocytów i monocytów.

Na preparatach histologicznych skrzelii początkowo obserwuje się uszkodzenie powierzchniowych warstw nabłonka oddechowego, nacieki leukocytarne i niewielkie zmiany w naczyniach krwionośnych. Przy przejściu choroby w formę ostrą tworzą się liczne ogniska martwicze. Zmiany nekrotyczne obejmują duże partie tkanki skrzelii. Przy silnych zmianach w tkance i na powierzchni skrzelii stwierdza się duże ilości laseczkowatych bakterii.

Zmiany w nerce i wątrobie noszą charakter nekrobiozy. Ich nasilenie jest zależne od stopnia zaawansowania choroby, która w skrajnych przypadkach prowadzi do rozległej martwicy rozptylnej tych narządów.

Procesy wsteczne w organizmie przebiegają wyraźnie dwustopniowo. Autor wychodzi z założenia, że każdy z tych etapów powodowany jest przez inny czynnik patogeny. Objawy toksykozy świadczą za tym, że choroba inicjowana jest, najprawdopodobniej, przez niekorzystne warunki środowiskowe, które uszkadzają bariery obronne umożliwiając infekcję bakteryjną.



## REFERENCES

- Amlacher E., 1972. Taschenbuch der Fischkrankheiten. Jena, G. Fischer Verl.
- Apazidi L. H., 1961. Żabernaja gnil v nekatorych rybchozach RSFSR. Trudy VNIIPRCh, 10.
- Bauer A. M., V. A. Musselius, J. A. Strelkov, 1969. Bolezni prudovych ryb. Moskva, Kolos.
- Bootsma R., 1974. Bacterial gill disease of carp (*Cyprinus carpio* L.). Tijdschr. Diergeneesk., 99, 143—145.
- Flis J., 1968 a. Zmiany anatomo- i histopatologiczne u karpia (*Cyprinus carpio* L.) pod wpływem wody amoniakalnej. Część 1. Wpływ dawek toksycznych — Anatomicohistopathological changes induced in carp (*Cyprinus carpio* L.) by ammonia water. Part 1. Effects of toxic concentrations. Acta Hydrobiol., 10, 205—224.
- Flis J., 1968 b. Zmiany anatomo- i histopatologiczne u karpia (*Cyprinus carpio* L.) pod wpływem wody amoniakalnej. Część 2. Wpływ dawek subtoksycznych — Anatomicohistopathological changes induced in carp (*Cyprinus carpio* L.) by ammonia water. Part 2. Effects of subtoxic concentrations. Acta Hydrobiol., 10, 225—238.
- Houston A. H., M. A. Wilde, 1972. Some observations upon the relationship of microhaematocrit values to haemoglobin concentrations and erythrocyte numbers in the carp *Cyprinus carpio* and brook trout *Salvelinus fontinalis*. J. Fish Biol., 4, 109—116.
- Kocylowski B., 1972. Wpływ czynników środowiskowych na zapalenie zgorzelinowe skrzeli karpia. Gosp. Ryb., 24, 1, 9—11.
- Kulow H., 1973. Ein Jahr Fischgesundheitsdienst der DDR. Z. Bienenfisch. DDR, 20, 175—180.
- Kulow H., V. A. Musselius, 1973. Zur Ätiologie, Epizootologie, Prophylaxe und Therapie der Kiemennekrose des Karpfens (branchionecrosis cyprinorum). Z. Bienenfisch. DDR, 20, 289—291.
- Linnik V. J., T. J. Mamys', V. C. Lagovskaja, 1972. Etiologija żabernogo zabolevanija ryb v Belorussi. Trudy I Vsesojuz. Symp. po Infekcionnym Boleznum Ryb v SSSR, 65—67.
- Lopuchina A. M., 1968. O żebnom zabolevanii karpov. Veterinarija, 45, 56—58.
- Lopuchina A. M., 1969. Materiały po etiologii i epizootologii żabernogo zabolevanija karpa. Izv. GosNIORCh, 69, 124—137.
- Lukjanenko V. I., 1967. Toksikologija ryb. Moskva, Pišč. Promysl.
- Machado-Cruz J. A., 1962. Sur l'apparition récente de "Bacterial gill disease" en Europe et sa caractérisation histopathologique. Publ. Inst. Zool. Dr A. Nobre, 82, 8—18.
- Margaritov N., 1971. Branchionekrosata — nova bolest po šarana u nas. Rib. Stop., 18, 4—5.
- Margaritov N., 1973. Izsledovanije na niakoj hematologični pokazateli na dvuleten šaran, bolen ot branchionekroza. Rib. Stop., 20, 5—8.
- Mattheis T., 1973. Kiemennekrose des Karpfens. Z. Bienenfisch. DDR, 20, 356—359.
- Miączyński T., 1965. Viral diseases and diseases of uncertain etiology in fish in Poland. Ann. New York Acad. Sci., 126, 620—628.
- Schweiger G., 1957. Die toksykologische Einwirkung von Schwermetalsaltzen auf Fische und Fischnährtiere. Arch. Fischereiwiss., 8, 54—78.
- Spangenberg R., 1975. Orientierende Untersuchungen über das Vorkommen von Myxobakterien bei der Kiemennekrose des Karpfens. Z. Bienenfisch. DDR, 22, 121—127.
- Schreckenbach K., R. Spangenberg, S. Krug, 1975. Die Ursache der Kiemennekrose. Z. Bienenfisch. DDR, 22, 257—288.

- S v o b o d o v á Z., 1973. Influence of sex upon certain haematological indexes of the carp (*Cyprinus carpio* L.) during the third vegetation period. Acta Vet., 42, 257—263.
- S v o b o d o v á Z., J. S m i š e k, 1974. Hodnoty červeného krvního obrazu kapra (*Cyprinus carpio* L.) ruzného fenotypu a genotypu v ošpeni. Bul. VÚRH Vodňany, 10, 1, 9—16.
- S v o b o d o v á Z., J. T e s a r č i k, 1974. Některe hodnoty červeného krvního obrazu při branchiomykóze, branchiomykróze a mucofilóze kapru. Bul. VÚRH Vodňany, 10, 2, 21—24.
- S č e r b i n a A. K., 1973. Bolezni ryb. Kiev, Urožaj.
- T e s a r č i k J., L. S t o s, 1969. Vyskyt branchionekrozy (branchionecrosis cyprinum) u kapra v Severomoravském kraji. Bul. VÚRH Vodňany, 5, 4, 3—6.
- W a l u g a D., 1971. Zmiany w skrzelach pstrąga tęczowego (*Salmo gairdneri* Richardson) pod wpływem zieleni malachitowej — Changes in the gills of rainbow trout (*Salmo gairdneri* Richardson) under the influence of malachite green. Roczn. Nauk Roln., H, 93, 4, 127—131.
- W a l u g a D., J. F l i s, 1971. Zmiany we krwi obwodowej karpia (*Cyprinus carpio* L.) pod wpływem wody amoniakalnej — Changes in the peripheral blood in carp (*Cyprinus carpio* L.) under the influence of ammonium liquor. Roczn. Nauk Roln., H, 93, 2, 87—94.
- W o o d E. M., W. T. Y a s u t a k e, 1957. Histopathology of fish. 5. Gill disease. Progres. Fish-Culturist, 1, 7—13.

Adres autora — Author's address

mgr inż. Andrzej Pilarczyk

Zakład Doświadczalny Gołysz, Polska Akademia Nauk, 43-422 Chybie