

probably to atavism or the incomplete process of evolution. He drew attention to the very rare occurrence of additional teeth in humans (0.23%) and the fact that additional teeth are a fairly faithful copy of the adjacent teeth. The studies he made of persons closely related to individuals with additional teeth did not confirm any tendency to inherit this character.

The cases of additional teeth recorded in the red deer did not unfortunately permit of more exactly establishing the frequency of occurrence of this anomaly. It is impossible to attribute this phenomenon to atavism in the case of the red deer, as no decrease in the number of molars in ruminants has taken place during the process of evolution.

REFERENCES

- Chełkowski Z. & Melosik M., 1970: Nadliczbowy trzonowiec u jelenia. *Łow. pol.*, 2 (1365): 14. Pekelharing C. J., 1968: Molar duplication in red deer and wapiti. *J. Mammal.*, 49, 3: 524—526. Ziólkiewicz T., 1950: Zagadnienie zębów dodatkowych u człowieka. *Czasopismo Stomatol.*, 5: 240—246.

Polish Academy of Science, Institute of Genetics and Animal Breedin, Popielno, pow. Pisz. Received, August 25, 1970.

Janusz DYNOWSKI

A CASE OF ANOMALOUS ANTERIOR LIMBS IN *CAPREOLUS CAPREOLUS* (LINNAEUS, 1758)

PRZYPADEK ANOMALII KOŃCZYN PIERSIOWYCH U SARNY

Detailed anatomical description is given of abnormal fore-limbs of roe-deer. Hypertrophy and/or deformations of particular bones as well as defective functioning of joints were stated. Probable causes of these malformations are discussed.

This paper is to report the condition of the fore-limbs of a dead and greatly emaciated young roe-deer found near the gamekeeper's house at Orlicz (Puławy administrative district). The animal was young, as indicated by the distinct demarcation between the epiphyses and diaphyses of the long bones. Almost all the bones of the free parts of both fore-limbs were deformed, as was the distal end of the left radius.

*Radius*¹⁾. The epiphysis of the radius had undergone excessive elongation on the medial side (Fig. 1a, 2a) and the articular surface was devoid of the characteristic depressions.

Ossa carpi. All *ossa carpi* of the right limb bore traces of injuries on both the dorsal and palmar surfaces. Losses were visible in many places. Injuries were present even on the articular surfaces, the smallest number of these occurring on *os carpi accessorium*.

¹⁾ Terminology after: *Nomina anatomica veterinaria*, 1968. Vienna.

The articular surfaces of *ossa carpi* of the left limb have an altered shape from the antebrachial side, expressed in less complicated contour in comparison with the analogous surfaces of a healthy individual. Here also the *os carpi accessorium* exhibits the fewest injuries, whereas the other bones have greater injuries on the dorsal and palmar surfaces than *ossa carpi dextri*. The *os carpi radiale et intermedium* are fused, forming a uniform mass. Nine of them are similar to the analogical bones forming part of a normally developed limb (Fig. 2b). Below the *articulatio carpometacarpalis* and at its level from the medial side there is a large porous excrescence (Fig. 1c, 2c). It is probable that the cause of its formation was *periostitis ossificans*²⁾. Both *os carpale II* and *III*, and also *metacarpale III et IV*, exhibit considerable losses in this place.

Ossa metacarpi. *Os metacarpale III et IV* of the right metacarpus is approximately 10% shorter than a normally developed bone. Its shaft is slightly bent laterally and flattened laterally in the middle part, and consequently, when seen from the dorsal side it appears to be disproportionately thin in relation to the base and trochlea (Fig. 1d). The *sulcus longitudinalis palmaris* runs asymmetrically, closer to the medial side of the shaft. The trochlea of *os metacarpi IV* has considerable losses on the lateral edge. From the palmar side malformations in the form of excrescences can be seen on it (Fig. 3c), similar to those which occurred in the region of *articulatio carpometacarpalis* of the right limb. The trochlea of *os metacarpale III* has been almost completely destroyed.

Os metacarpale III et IV of the left limb is bent medially and about 20% shorter than normal. The shaft of *os metacarpale III* has split at two thirds of its length — from trochlea towards the base (Fig. 1e, 3e). The small nodule on the separated medial, thinner bone (*os metacarpale III*) in no way resembles a trochlea (Fig. 3k), although it has an articular surface. Trochlea of *os metacarpale IV* is of normal size but is deformed. *Sulcus longitudinalis palmaris* is visible on the side of *os metacarpale IV*.

Os metacarpale II et os metacarpale V are missing from the left metacarpus, but in the right, excepting the *os metacarpale III et IV* there is only *os metacarpale V*. The shaft of the latter joins the epiphysis at an angle of about 135° (Fig. 3f). *Sulcus longitudinalis dorsalis* is very faintly marked on the ends of the shafts of *ossis metacarpalis III et IV*, and is completely invisible on their medial parts. This applies to the bones of both limbs.

Ossa digitorum. *Ossa digitorum* are incomplete. The bone of the second digit is missing in the right limb. Only the *phalanx proximalis*, shortened, thin, and greatly narrowed towards its trochlea, remains. It is connected with the trochlea by a very narrow and long corneous hoof (Fig. 1g). *Phalanx proximalis* of the fourth digit is greatly thickened in the basal region, and its trochlea has been bent laterally. The medial phalanx of this digit is bent medially and the distal half is contained, together with *phalanx distalis*, in the hypertrophic and deformed hoof. There are no visible changes in the fifth digit.

²⁾ I should like to express my thanks to Professor Dr. M. Lewandowski, Head of the Department of Surgery of Lublin Agricultural College, for defining the pathological process.

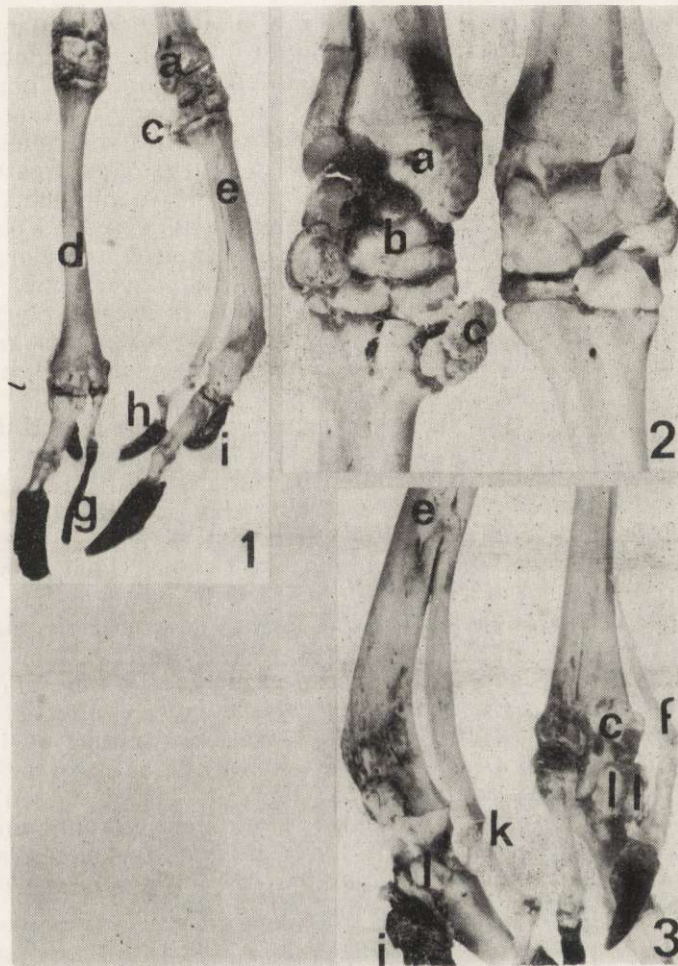


Fig. 1. Abnormal autopodia of fore-limbs. Dorsal view.

Fig. 2. Carpus region. Palmar view.

Fig. 3. Metacarpal and digital region. Palmar view.

- a — radius of the left fore-limb
- b — *os carpi radiale et intermedium*
- c — porous excrescence
- d — *os metacarpale III et IV* of the right fore-limb
- e — *os metacarpale III et IV* of the left fore-limb
- f — *os metacarpale V* of the right fore-limb
- g — corneous hoof of third digit of the right fore-limb
- h — corneous hoof of third digit of the left fore-limb
- i — corneous hoof of fifth digit of the left fore-limb
- k — trochlea of *os metacarpale III*
- l — *ossa sesamoides*

The second digit of the left limb is also missing. The phalanges of the third digit are short and thin, proportional to the split *os metacarpale III*. Their articular surfaces have undergone deformation. The horny casing resembles a short tube slightly bent in an anterior direction (Fig. 1h). The fourth digit does not greatly differ from its right analogue. The *basis phalangis proximalis* has undergone less injury. The greatly altered horny casing of the fifth digit is fixed to it and to the shaft from the posterior-lateral side (Fig. 1i, 3i), together with unidentified osseous elements. The casing of the fourth digit, also deformed and elongated, extends slightly lower than in the right limb and covers only the distal third of *phalanx media*. *Basis phalangis distalis* is excessively thickened.

In both limbs the *ossa sesamoides phalangis proximalis* are present only near the fourth digitis (Fig. 3l). They differ from each other as to shape and size.

The animal probably touched the ground with only fourth digits as it moved.

The anomalies described have much in common with the case relating to mice observed by Grüneberg (1947), who assumed that changes in the bones of the fore limbs resulted from mutation. There also, the injuries were symmetrical in both limbs. Spicker (1968) reported two cases of hereditary hypertrophy of the hoof in roe-deer. He also considered »abnormal arrangement of the digitis« as a possible cause of deformity.

It is difficult to say what caused the occurrence of the anomalies in the case reported here. An underlying genetic cause cannot be ruled out with complete certainty. Hypertrophy and deformation of the horny casing of the fourth digits could have taken place as the result of their abnormal arrangement; or faulty positioning might have only contributed to malformation of these casings. The defective functioning of the joints and bone curvatures brought about, *inter alia*, changes in pressure distribution, which in turn contributed to the inflammatory conditions. These might have consequently led to further changes.

REFERENCES

Grüneberg H., 1947: Bilateral defect of the radius in a mouse. *Acta anat.*, Basel 2, 3/4: 270—274. Spicker, D., 1968: Ausgewachsene Schalen bei Rieke und Kitz und Hinweise zu möglichen Ursachen. *Z. Jagdwiss.*, 14, 3: 136—139.

Dept. Comparative Anat. Vertebr., M. Curie-Skłodowska Univ., Lublin, *Akademicka* 19. Received, July 2, 1970.