

glass at a distance of 30—40 m. These numbers are also visible when the animals are swimming under water, as they contrast sharply with the dark colour of the tail. This method of marking animals on farms is so useful as to appear indispensable, and it can also be successfully used for marking free-living animals. When bringing this method into general use for marking beavers it would be desirable to design special numbering stamps with figures of suitable size with a distinct fine outline to the figures and considerable heat volume.

The only disadvantage of this method is that the numbers do not appear until a fairly long time after the operation.

REFERENCES

Aldous S. E., 1940: A method of marking beavers. *J. Wildl. Mgmt.* 4, 2: 145—148. Lavrov L. S., 1953: Metodika kolcevaniya rečnych bobrov. *Tr. Voronež. Gos. Zap.* 4: 85—87. Miller D. R., 1964: Colored plastic ear markers for beavers. *J. Wildl. Mgmt.* 28, 4: 859—861.

Polish Academy of Science, Institute of Genetics and Animal Breedin, Popielno, pow. Pisz. Received, August 25, 1970.

Wirgiliusz ŻUROWSKI

ADDITIONAL MOLAR IN EUROPEAN RED DEER

DODATKOWY TRZONOWIEC U JELENIA

A description is given of a case of additional molar occurring in a stag shot in 1968 in the Mazurian region of Poland. The additional tooth had caused elongation of *margo alveolaris*, a change in the form of the tooth-socket of M^3 , and of *tuber maxillare*. The appearance of an additional tooth can be explained by early splitting of the tooth bud of M^3 .

Anomalies in the teeth of European red deer occur very rarely. An additional M_3 in the red deer was described by P e k e l h a r i n g (1968) as the only case found among the 580 red deer he examined, which had been shot in Fiordland in New Zealand. A similar case was found in a hind from the Szczecin voivodship by C h e ł k o w s k i & M e l o s i k (1970). In both cases the other premolars and molars had developed normally and exhibited normal wear. The additional tooth described by C h e ł k o w s k i & M e l o s i k (1970) was higher than the remainder and had very slight traces of wear on the anterior margin from the buccal side. Additional teeth do not differ morphologically from their neighbouring molars.

A case of an additional M^3 in a 10-year old wapiti doe (*C.e. canadensis* E r x l e b e n) was the only tooth anomaly found among the 130 wapiti deer examined (P e k e l h a r i n g, 1968). Morphologically the additional tooth was similar to the third molar, except for the absence of traces of wear on the prominent margins.

A 4-year old stag (*C. elaphus elaphus* Linnaeus, 1758) was shot on Sept. 18th 1968 in game management region nr. 163 in the Mazurian district of Poland. The stag was a well-developed animal weighing 160 kg, with irregular antlers, with a 10-tine, crown on the right branch. After the skull had been prepared it was found that there was an additional molar in the upper left maxilla (Fig. 1). Morphologically this molar did not differ in any respect from M^3 . It was in the phase of growing up from the gum, had deep marks without traces of wear, and the typical white colour. The other premolars and molars were normally developed, with traces of wear typical of 4-years old animals. The occurrence of an additional tooth had caused changes in *margo alveolaris* of the left maxillar, which had elongated, while the socket of the third molar had taken

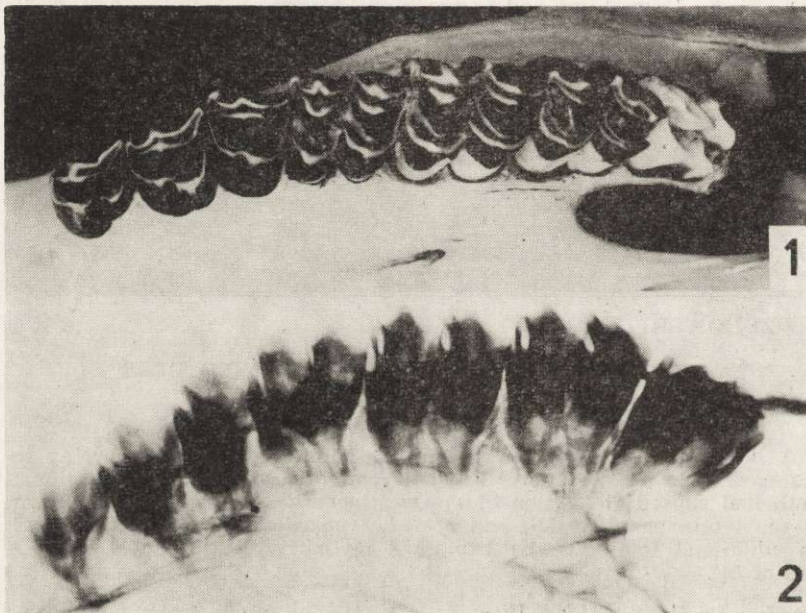


Fig. 1. Additional molar in left maxilla of stag (photo by J. J. Pollesch).
 Fig. 2. X-ray photograph of the same maxilla with additional molar (photo by K. Stempiński).

on the form of a decided rectangle, and tuber maxillare, in which the alveola of the additional tooth had formed, had almost completely disappeared. *Margo interalveolaris*, on the other hand, had not undergone any changes when compared with the right maxilla. The internal roots of M^3 and additional molar contact on the buccal side in a joint alveolar canal, but are not fused. The marked proximity of the roots of M^3 and additional molar visible on the X-ray photo (Fig. 2) may suggest that the appearance of additional teeth is due to early splitting of the tooth bud.

Ziółkiewicz (1950) considers that the formation of additional teeth as the effect of early fusion of the tooth-bud merely explains the mechanism of the appearance of such teeth, whereas their occurrence is due

probably to atavism or the incomplete process of evolution. He drew attention to the very rare occurrence of additional teeth in humans (0.23%) and the fact that additional teeth are a fairly faithful copy of the adjacent teeth. The studies he made of persons closely related to individuals with additional teeth did not confirm any tendency to inherit this character.

The cases of additional teeth recorded in the red deer did not unfortunately permit of more exactly establishing the frequency of occurrence of this anomaly. It is impossible to attribute this phenomenon to atavism in the case of the red deer, as no decrease in the number of molars in ruminants has taken place during the process of evolution.

REFERENCES

Chełkowski Z. & Melosik M., 1970: Nadliczbowy trzonowiec u jelenia. *Łow. pol.*, 2 (1365): 14. Pekelharing C. J., 1968: Molar duplication in red deer and wapiti. *J. Mammal.*, 49, 3: 524—526. Ziólkiewicz T., 1950: Zagadnienie zębów dodatkowych u człowieka. *Czasopismo Stomatol.*, 5: 240—246.

Polish Academy of Science, Institute of Genetics and Animal Breedin, Popielno, pow. Pisz. Received, August 25, 1970.

Janusz DYNOWSKI

A CASE OF ANOMALOUS ANTERIOR LIMBS
IN *CAPREOLUS CAPREOLUS* (LINNAEUS, 1758)

PRZYPADEK ANOMALII KOŃCZYN PIERSIOWYCH U SARNY

Detailed anatomical description is given of abnormal fore-limbs of roe-deer. Hypertrophy and/or deformations of particular bones as well as defective functioning of joints were stated. Probable causes of these malformations are discussed.

This paper is to report the condition of the fore-limbs of a dead and greatly emaciated young roe-deer found near the gamekeeper's house at Orlicz (Puławy administrative district). The animal was young, as indicated by the distinct demarcation between the epiphyses and diaphyses of the long bones. Almost all the bones of the free parts of both fore-limbs were deformed, as was the distal end of the left radius.

*Radius*¹⁾. The epiphysis of the radius had undergone excessive elongation on the medial side (Fig. 1a, 2a) and the articular surface was devoid of the characteristic depressions.

Ossa carpi. All *ossa carpi* of the right limb bore traces of injuries on both the dorsal and palmar surfaces. Losses were visible in many places. Injuries were present even on the articular surfaces, the smallest number of these occurring on *os carpi accessorium*.

¹⁾ Terminology after: *Nomina anatomica veterinaria*, 1968. Vienna.